Environmental Health Perspectives
Vol. 23, pp. 111–118, 1978

Effects of PBB on Cattle. II. Gross Pathology and Histopathology

by P. D. Moorhead,* L. B. Willett,† and F. L. Schanbacher†

Toxicosis was induced in pregnant Holstein heifers by feeding FireMaster BP-6 (polybrominated biphenyls) in daily oral doses of 25 g/head/day for 33–60 days. The individual heifers were dosed until each became moribund (days 33, 36, 39, 40, 41, or 66), at which time they were necropsied. Gross findings included dehydration, subcutaneous emphysema and hemorrhage, atrophy of the thymus, fetal death with concomitant necrosis of cotyledons, thickened wall of the gallbladder, inspissated bile, edema of abomasal folds, mucoid enteritis, linear hemorrhage and edema of the rectal mucosa, and secondary pneumonia. The livers were enlarged approximately 40%. Kidneys were approximately double the normal size and were pale tan to grey in color. The perirenal lymph nodes were enlarged and edematous. Microscopic changes were the most marked in the kidneys, gallbladder and eyelid. Extreme dilatation of collecting ducts and convoluted tubules with epithelial degenerative changes of cloudy swelling, hydropic degeneration and separation from the basement membrane were principal changes in the kidney. Hyperkeratosis with accumulations of keratin in hair follicles of the epidermis and squamous metaplasia with keratin cysts in the tarsal glands were characteristic findings in sections of eyelids. Moderate to marked hyperplasia and cystic dilatation of the mucous glands in the lamina propria were common changes in the gallbladder. Foci of fatty degeneration and glycogen depletion were observed in liver sections. Necropsy of heifers immediately after 60 days exposure to 0.25 and 250 mg/head/day of PBB showed no gross or histopathological signs indicating toxicosis. Following parturition, at approximately 220 days after the PBB doses, heifers from the 0.25 and 250 mg/head/day groups and their calves were necropsied and displayed no signs of toxicosis.

Introduction

Following the discovery of accidental contamination of animal feeds with polybrominated biphenyls (PPB) on Michigan farms in 1974, the investigation of the toxicologic effects of these compounds became of primary importance not only to the livestock industry but as a possible health hazard to man. Studies of PBB toxicosis in cattle conducted by our group have included tissue distribution and clearance (*1*), gross and histologic tissue changes (*2*), clinicopathologic alterations in blood and urine (*3*), effects on health and performance (*4*), renal function (*5*), and performance of calves from cows exposed to PBB (*6*). Selected tissues from cattle with acute PBB toxicosis are being processed for examination with the electron microscope. All cattle and calves involved in these studies have been, or will be, subjected to complete necropsy examination upon death or termination of a particular study. The information in this paper will be confined to the description of pathologic changes commonly observed in cattle with experimentally induced PBB toxicosis.

Materials and Methods

Treatment Groups

Details on animals, housing, rations, clinical evaluations, PBB dosage levels, and frequency have been reported (*2–4*). Toxicosis was induced only in cattle fed FireMaster BP-6 (PBB) in daily oral doses of 25 g/head/day for 25 to 60 days (*2–4*). Individual heifers and one cow were dosed until each became moribund on days 33, 36, 39, 40, 41, 63 and 66 (*2*). Experimental treatment levels of PBB used in the study are illustrated in Table 1.

* Department of Veterinary Science, Ohio Agricultural Research and Development Center, Wooster, Ohio 44691.
† Department of Dairy Science, Ohio Agricultural Research and Development Center, Wooster, Ohio 44691.

Table 1. Treatment groups and dosage of a commercial mixture of polybrominated biphenyls given to pregnant heifers.

Group	Dose rate, mg/day	Initial concentration, mg/kg body weight/day[a]	Total amount fed, g
I	0	0.0	0
II	0.25	0.0006	0.015
III	250	0.65	15
IV	25,000	67.2	820 to 1,500[b]

[a] Constant doses were given throughout the experiment and were not adjusted for changes in body weight.
[b] Animals in group IV became moribund between days 33 and 66 and were necropsied.

Necropsy Procedure

All cattle that were necropsied were killed by intramuscular injection of 100 mg of succinylcholine chloride followed by exsanguination immediately prior to necropsy. Necropsy dates were established by signs of terminal toxemia in the individual cow.

Representative specimens from organs of all cattle that were necropsied were fixed in neutral buffered formalin. Fixed tissues were processed for paraffin embedding, sectioned at 6 μm and stained with azure and eosin (*7*).

Results

Necropsy Findings

Significant gross pathologic changes were not observed in cattle receiving PBB at levels less than 25 g/head/day for a minimum of 25 days (*2*).

Toxic cattle exhibited signs of dehydration and marked emaciation (Fig. 1). Extensive subcutaneous emphysema and petechial hemorrhages occurred in the areas of flank, caudal portion of the abdominal wall and medial surface of the hind limbs. Atrophy of the thymus was common. Edematous and hemorrhagic dead fetuses were found in the uterus of pregnant cattle (Fig. 2). Concomitant uterine lesions were hemorrhage and necrosis of cotyledons, with separation of the caruncles and placental degeneration (Fig. 3). The kidneys were greatly enlarged, distended with fluid, pale tan to grey, with little perirenal fat (Fig. 4). The kidneys were approximately double normal size (Table 2) with tubules appearing as pale streaks on the cut surface of the cortex (Fig. 4). Perirenal lymph nodes were enlarged and edematous. The liver appeared slightly enlarged and friable but otherwise normal (Table 2). The gallbladder ap-



FIGURE 1. Heifer given 25 g of PBB/day for 39 days exhibiting emaciation and dehydration with excessive salivation and lacrimation.

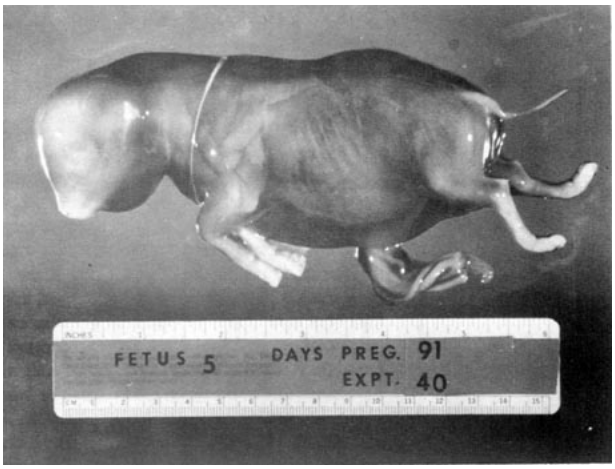

FIGURE 2. Edematous and hemorrhagic fetus from uterus of heifer given 25 g of PBB/day for 40 days.

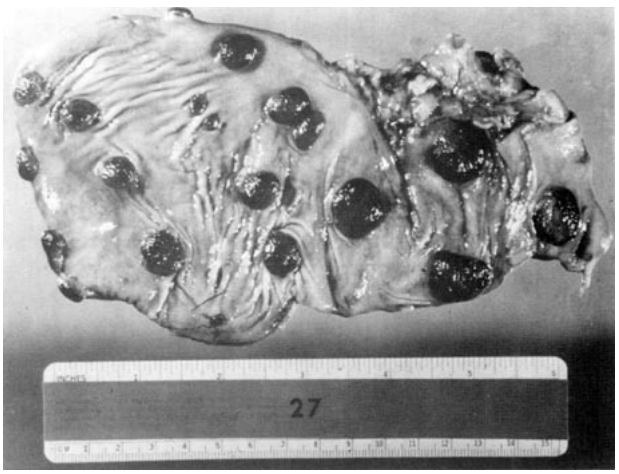

FIGURE 3. Hemorrhagic and necrotic uterine cotyledons from heifer fed 25 g of PBB/day for 33 days.

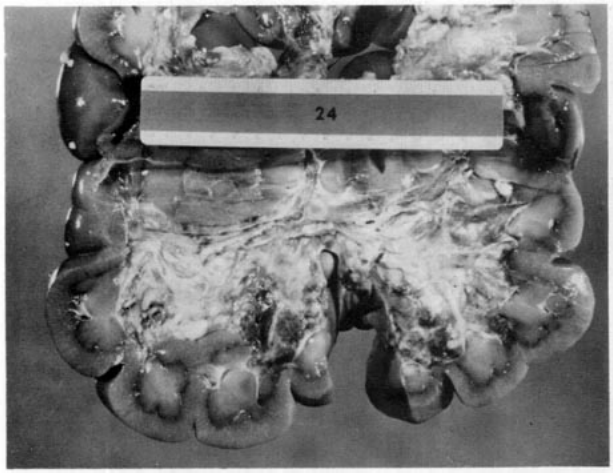

FIGURE 4. Enlarged kidneys with distended collecting tubules appearing as pale streaks on cut surface of cortex. From heifer fed 25 g PBB/day for 41 days.

Table 2. Mean organ weights of pregnant Holstein heifers treated with polybrominated biphenyls.

Organ	Organ weight, g[a]			
	Group I (control)	Group II (0.25 mg/day)	Group III (250 mg/day)	Group IV (25 g/day)
Liver	5500	5600	6575	7573
Kidneys	1044	1009	1005	2363

[a] Means of two heifers for Groups I, II, and III; mean of six heifers for Group IV.

peared thickened and filled with inspissated bile. The changes in the gastrointestinal tract were varied. The most constant observation was the absence of residual feed in the digestive tract. Other changes observed were edema of mucosal folds in the abomasum, occasional mucosal ulcers of the abomasum and colon, mucoid enteritis and linear hemorrhages, and edema of the rectal mucosa (Fig. 5).

Other lesions were pneumonia and petechial hemorrhages of tracheal mucosa, endocardium and myocardium.

Histopathologic Findings

Pathologic changes were not observed in tissue sections from cattle receiving PBB at levels less than 25 g/head/day for a minimum of 25 days.

The principal lesions observed in kidney specimens from toxic cattle were extreme dilatation of collecting ducts and convoluted tubules, with tubular degenerative changes marked by cloudy swelling, hydropic degeneration and separation from the basement membrane (Figs. 6 and 7). The changes were more prominent in the collecting ducts than in

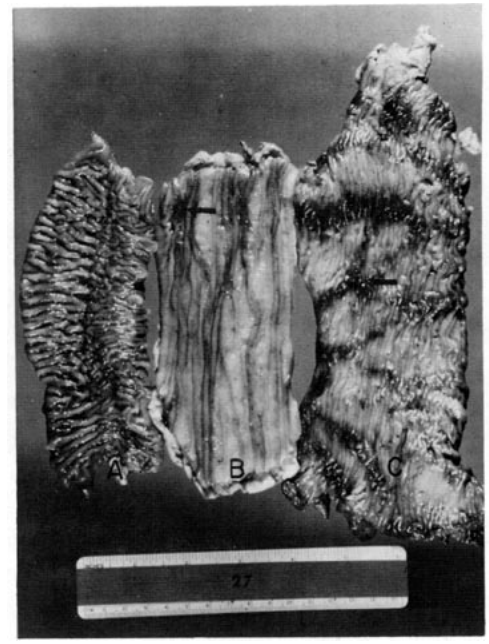

FIGURE 5. Changes in gastrointestinal tract of heifer fed 25 g PBB/day for 33 days: (*A*) hyperemia of small intestine; (*B*) mucosal hemorrhage of colon (arrow); (*C*) linear hemorrhages of rectal mucosa (arrow).

the convoluted tubules. Occasional blood and hyaline casts were found in collecting ducts in the pyramidal area. Vascular changes were not marked and consisted of congestion, with scattered microscopic hemorrhages in the medulla. There were no significant glomerular changes. Interstitial fibrosis was minimal.

Hyperkeratosis, with accumulation of keratin in the hair follicles of the epidermis, and squamous metaplasia with keratin cysts in the tarsal glands were common changes in the eyelids (Figs. 8 and 9).

Changes in the gallbladder were characterized by moderate to marked hyperplasia and cystic dilatation of the mucous glands in the lamina propria (Fig. 10). Changes in the liver were not marked and consisted of glycogen depletion of hepatocytes, sinusoidal dilatation, and scattered areas of early centrolobular fatty degeneration (Fig. 11).

Hemorrhage and necrosis of cotyledons, with minimal changes in endometrium and uterine wall, were principal lesions in the uterus from cattle with retained fetuses (Fig. 12). In specimens of uterus from cattle that had aborted, the uterus appeared to be involuting normally.

Changes in the gastrointestinal tract were minimal. Occasional findings were edema of mucosal folds and ulceration in the abomasum, hemorrhage, edema and hyperemia of the mucosa of the terminal colon and rectum. One specimen of pancreas had

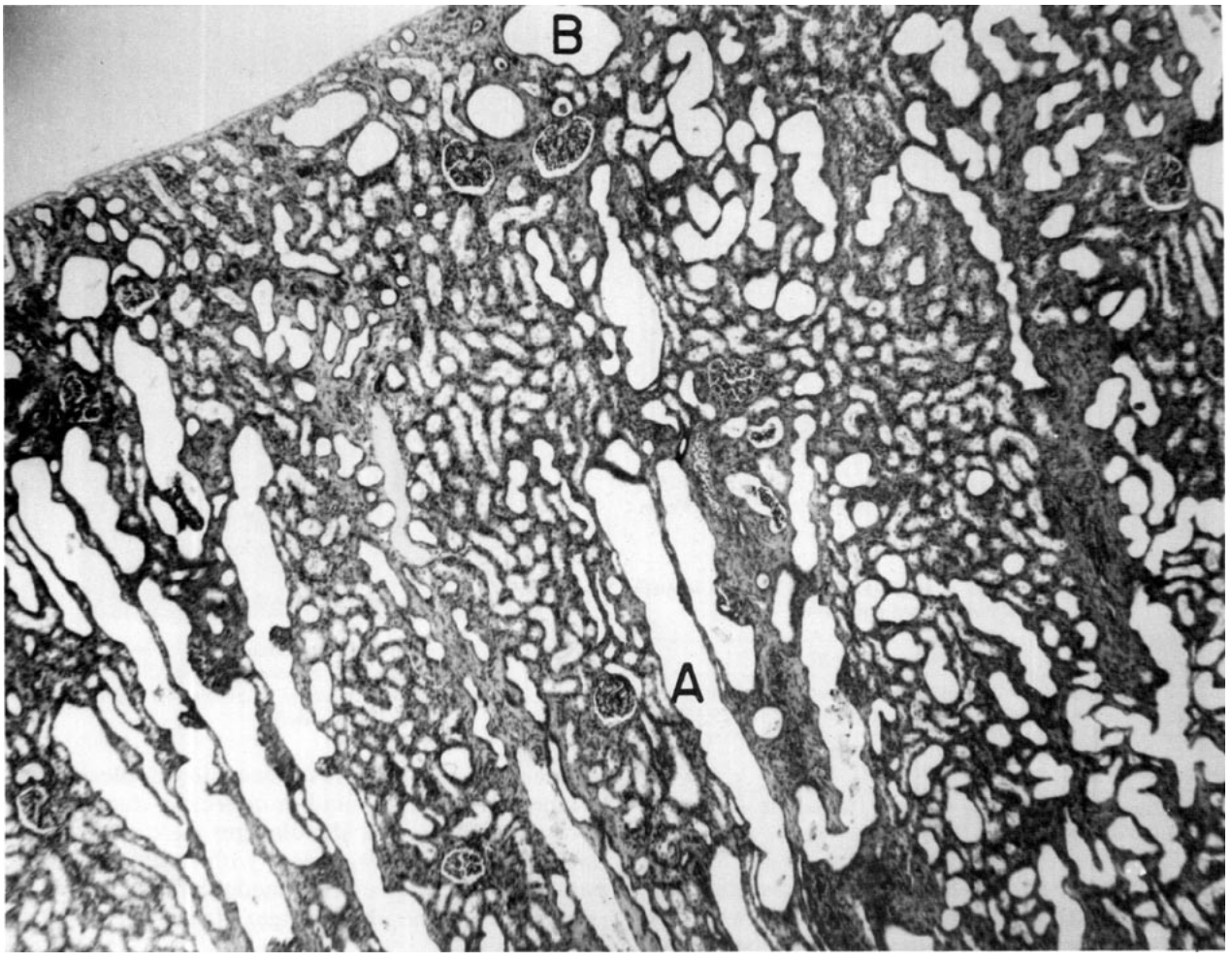

FIGURE 6. Extreme dilatation of (*A*) renal collecting tubules and (*B*) proximal convoluted tubules from PBB toxic cow. A & E stain; 28×.

lesions of chronic fibrosing pancreatitis. Moderate to marked involution of the thymus was common to all toxic cattle. Microscopic lesions of early purulent bronchopneumonia were observed in lung specimens from two cows.

Mammary gland, salivary gland, sternebrae (marrow), thyroid, trachea, esophagus, rumen, omasum, reticulum, spleen, adrenal, ovary, urinary bladder, brain, pituitary, and spinal cord were histologically normal.

Discussion

The pathologic changes observed in PBB toxicosis in cattle are remarkably similar to those described for bovine hyperkeratosis (X disease) caused by highly chlorinated naphthalenes (*8–11*). Hyperkeratosis was not as grossly apparent in cattle with PBB toxicosis, as reported for cattle with hyperkeratosis, but was obvious in histologic sections (*2*). Although the pathologic changes in cattle with PBB toxicosis and bovine hyperkeratosis were quite similar, the concentrations required to elicity toxicosis were markedly different for each of the two chemicals. Cattle have been reported to be relatively sensitive to chlorinated naphthalene intoxication, a single dose of 11 mg to 22 mg/kg producing 100% mortality (*12*). In contrast, the cattle in these studies exhibited a wide range of sensitivity to intoxication with PBB, the approximated minimum dose required to produce mortality was 67.2 mg/kg administered daily for 25 to 66 days (Table 1). Based on a 400-kg cow, the approximate total dose of PBB required to produce 100% mortality ranges from 820 to 1500 g (Table 1). The actual LD_{50} for PBB in cattle cannot be calculated from the data in these studies, but it does suggest that PBBs are relatively nontoxic.

Commercial synthesis of halogenated hydrocarbons often results in the formation of trace

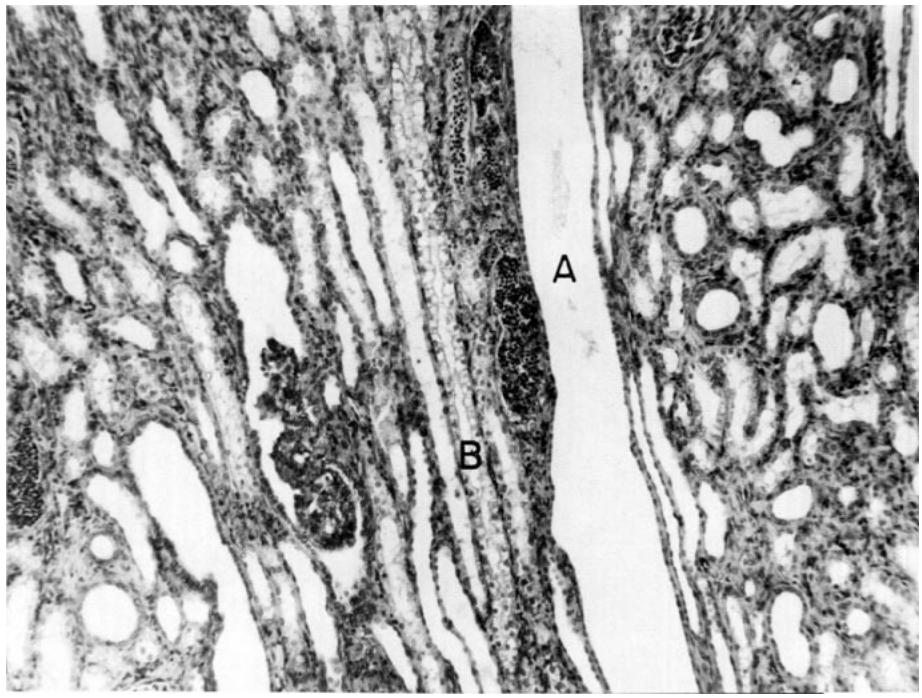

FIGURE 7. Higher magnification of dilated renal collecting tubules, with flattened epithelium (*A*), hydropic degeneration of cells (*B*), and cellular debris (*C*). Azure and eosin (A & E) stain; 72×.

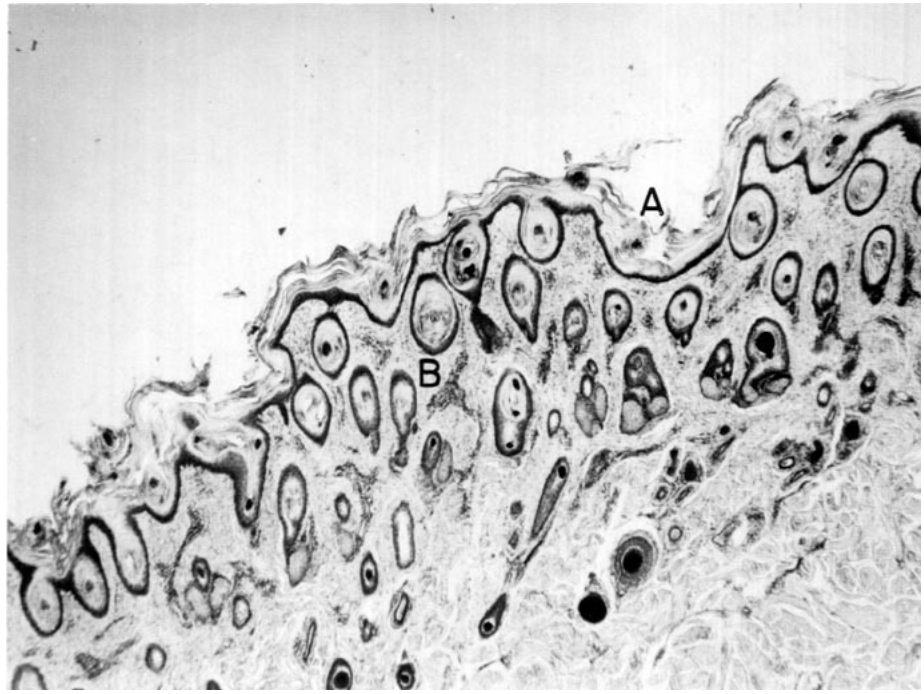

FIGURE 8. Epidermal surface of eyelid from PBB toxic cow: (*A*) hyperkeratosis with (*B*) accumulation of keratin in hair follicles. This histologic section is from a heifer fed 25 g PBB/day for 60 days. A & E stain; 23×.

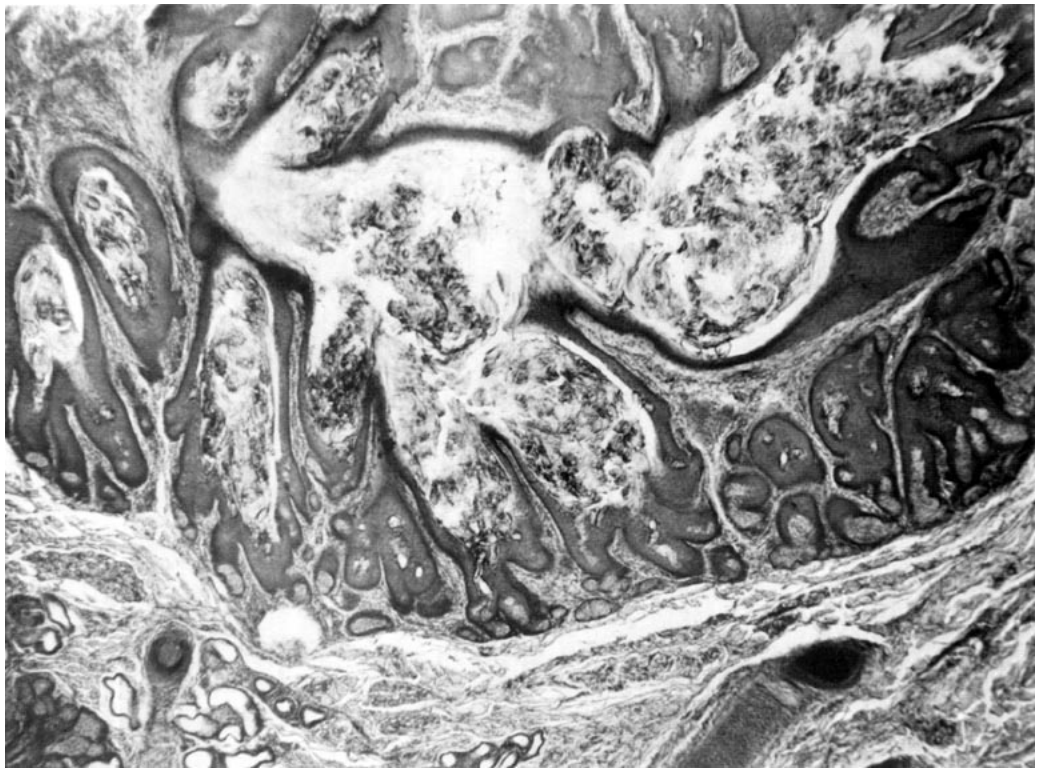

FIGURE 9. Squamous metaplasia of epithelium and keratin cysts in tarsal glands of eyelid from PBB toxic cow. A & E stain; 23×.

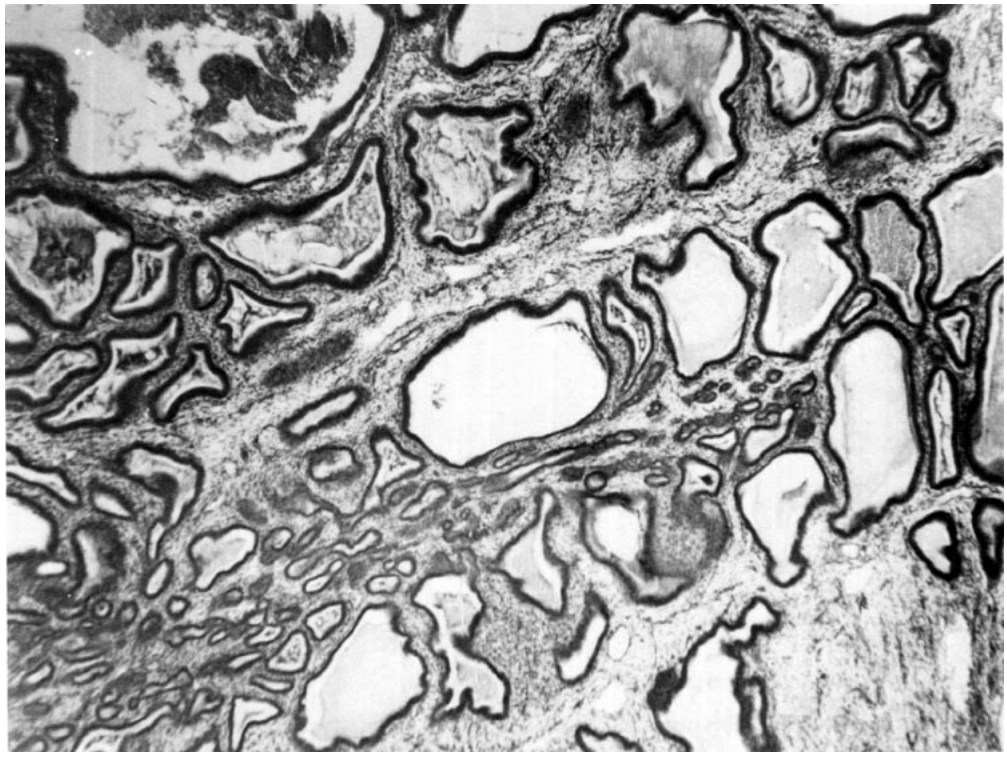

FIGURE 10. Hyperplasia and cystic dilatation of mucous glands of the gallbladder from heifer fed 25 g PBB/day for 60 days. A & E stain; 23×.

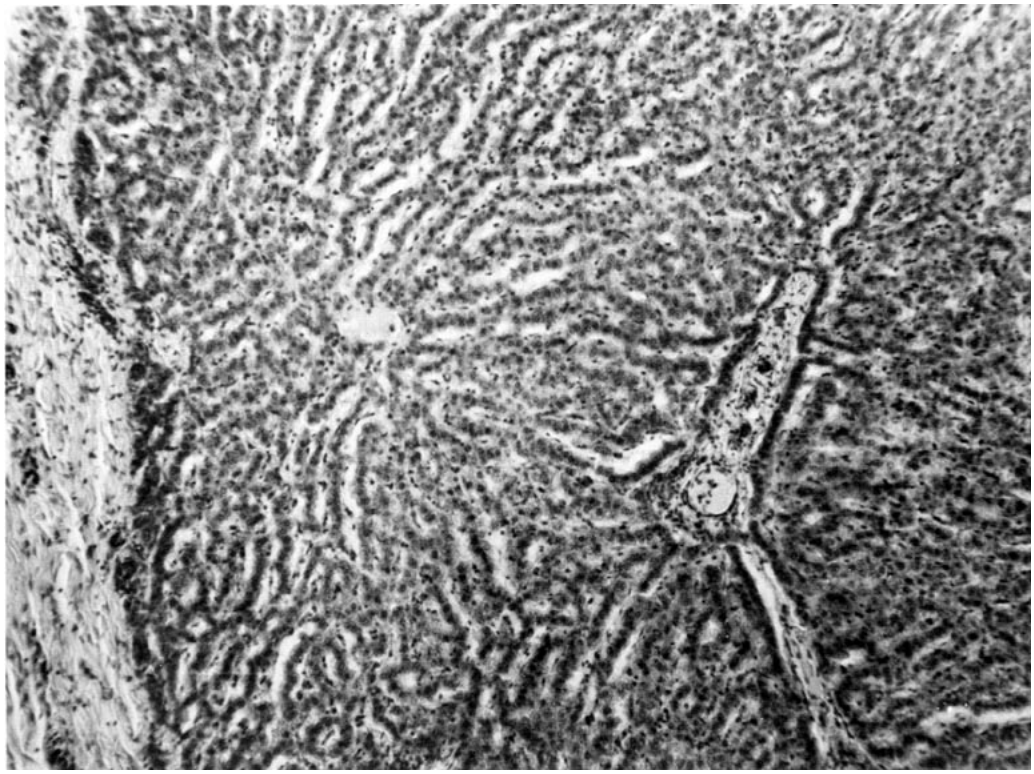

FIGURE 11. Sinusoidal dilatation and glycogen depletion of hepatocytes in liver of PBB toxic cow. A & E stain; 72×.

FIGURE 12. Necrosis of cotyledon (*A*), with minimal change in the uterine wall (*B*). This section was from a heifer fed 25 g PBB/day for 33 days. A & E stain; 23×.

quantities of other hydrocarbon contaminants as well as the expected end-product. Halogenated naphthalenes have been suggested (2) as a possible contaminant of FireMaster BP-6 (PBB); however, published reports of chemical analytical data to date have not verified this fact.

Our studies have shown that PBB toxic cattle have specific, highly characteristic and readily identifiable pathologic changes. This is valuable in that these pathologic changes should serve to clearly identify the problem should future incidents occur. Conversely, it might be used to rule out PBB involvement in incidences of claimed toxicity where specific lesions did not occur. Further, the histopathologic changes identified in the kidneys of PBB toxic cattle suggest the involvement of an extrahepatic target organ not normally associated with halogenated hydrocarbon toxicity. The mechanisms of PBB toxicity in the kidney would certainly merit further study if we are to better understand the pathogenic mechanisms of halogenated hydrocarbons in the environment.

These studies were supported in part by contract number 223-75-7015, Dept. of Health, Education and Welfare, Public Health Service, Food and Drug Administration.

REFERENCES

1. Willett, L. B., and Irving, H. A. Distribution and clearance of polybrominated biphenyls in cows and calves. J. Dairy Sci. 59: 1429 (1976).
2. Moorhead, P. D., et al. Pathology of experimentally induced polybrominated biphenyl toxicosis in pregnant heifers. J. Amer. Vet. Med. Assoc., 170: 307 (1977).
3. Durst, H. I., et al. Changes in blood and urine composition from feeding polybrominated biphenyls to pregnant Holstein heifers. J. Dairy Sci. 61: 197 (1978).
4. Durst, H. I., et al. Effects of polybrominated biphenyls on health and performance of pregnant Holstein heifers. J. Dairy Sci., 60: 1294 (1977).
5. Mercer, H. D., et al. Use of the double isotope, single injection method for estimating renal function in normal and polybrominated biphenyl-exposed dairy cows. Amer. J. Vet. Res., in press.
6. Willett, L. B., et al. The performance of calves born to cows experimentally exposed to polybrominated biphenyls. Paper presented at Amer. Dairy Sci. Assoc. 72nd Ann. Mtg., 1977; Program, p. 140.
7. Cross, R. F., and Moorhead, P. D. An azure and eosin rapid staining technique. Can. J. Comp. Med. 33: 317 (1969).
8. Bell, W. B. The relative toxicity of the chlorinated naphthalenes in experimentally produced bovine hyperkeratosis (X-disease). Vet. Med. 48: 135 (1953).
9. Hansel, W., and McEntree, K. Bovine hyperkeratosis (X-disease). A review. J. Dairy Sci., 38: 875 (1955).
10. Merck Veterinary Manual. Merck and Company, Rahway, N. J. 1973, p. 954.
11. Smith, H. A., and Jones, T. C. Veterinary Pathology, 4th ed. Lea and Febiger, Philadelphia, 1972, p. 938.
12. Garner, R. J. Veterinary Toxicology, 2nd ed. Williams and Wilkins Co., Baltimore, 1963, p. 282.