Environmental Health Perspectives
Vol. 23, pp. 183–185, 1978

A Simple Technique for Fat Biopsy of PBB-Exposed Individuals

by Susan M. Daum,* Jerome Knittle,* Kenneth Rosenman,* William N. Rom,† and Edwin C. Holstein*

A simple nonsurgical technique of obtaining fat samples by aspiration from the gluteal prominence was developed by Hirsh in 1960 and has been in use in our Nutrition Clinic at the Mount Sinai Hospital for several years. We have modified it for field use and the analysis of fat-soluble hydrocarbon residues. All the materials which will contain the fat sample to be analyzed are washed with acetone and pesticide residue-free hexane, and a 15 gauge needle and 33 cc syringe are sterilized.

Aspiration of fat from the lateral gluteal prominence is accomplished under local xylocaine anesthetic. The anesthetic also serves as the vehicle into which the fat is broken by the shearing action of the 15 gauge needle. Fat particles are sucked into the syringe by a constant vacuum kept on the syringe during lateral movement of the needle under (and parallel to) the skin within the gluteal fat pad; 200–500 ml of fat can be obtained for hydrocarbon residue analysis. The only complications have been some mild hematomas at the site of the aspiration. The method avoids surgical biopsy and sutures and takes about 7–8 min.

A simple, nonsurgical technique of obtaining fat samples by aspiration from the gluteal prominence was developed by Hirsh (*1*). We have modified the Hirsh method (which has been in use in the Nutrition Clinic of The Mount Sinai Hospital) to yield a sample of adequate size for hydrocarbon residue analysis. The aspiration procedure takes only 5–8 min, causes little pain or aftereffects, and does not require sutures or entail a return visit by the patient. Because of these advantages, the fat aspiration technique is readily adaptable to field investigations. However, biopsies are preferably limited to subjects with adequate subcutaneous fat deposits and are not suitable for thin athletic men, thin children and teenagers, and those who are cachectic.

Materials

A 15 gauge biopsy aspiration needle is used, with a 35-cm^3 glass syringe. The specimen jar is glass, with a Teflon-lined plastic screw top. The needle, syringe, and specimen jar are prepared prior to sterilization by washing them first with acetone, then with pesticide-residue-free hexane. Disposable plastic syringes and needles are used for the injection of the local anesthetic: 1% xylocaine without epinephrine. Warm sterile saline is used for rinsing the biopsy syringe and needle when transferring the aspiration specimen from the syringe to the specimen jar. A Teflon squirt jar was found to be especially convenient for this purpose. No plastics other than Teflon should come in contact with the specimen.

Method

The subject may lie in a prone or lateral position. In a prone subject, the aspiration is made from the farther gluteal fat pad to avoid important anatomic structures located closer to the midline (e.g., the sciatic nerve). The location of the gluteal prominence near the iliac crest is usually identified by inspection. In muscular subjects the fat pad may be identified by asking the subject to tense the gluteal muscles. The subject may be asked to raise his/her leg from the bed, keeping the knee straight.

The skin is cleansed in the usual manner with alcohol. The skin is anesthetized slowly with a small intracutaneous injection of xylocaine. Approximately 6 cm^3 of xylocaine is then injected slowly in

* Department of Community Medicine, Mount Sinai School of Medicine of the City University of New York, New York , N. Y. 10029.

† Present address: University of Utah, School of Medicine, Salt Lake City, Utah 84132.

a fan-shaped area laterally into the subcutaneous gluteal fat pad. The injection of xylocaine should be sufficiently slow to minimize the stinging and burning sensation the subject will feel.

A 35-cm^3 glass syringe and a 15 gauge needle are used for the aspiration. It is advisable to keep this equipment out of view of the subject and other volunteers, since the appearance of the 15 gauge needle is often upsetting.

After the area is properly anesthetized, the 15 gauge needle is introduced into the subcutaneous area. The barrel of the syringe is then drawn to the 35 cm^3 mark, creating a strong vacuum in the syringe. The vacuum is maintained for the duration of the aspiration procedure by holding the syringe and its retracted piston in the dominant hand. This maneuver requires some skill and practice.

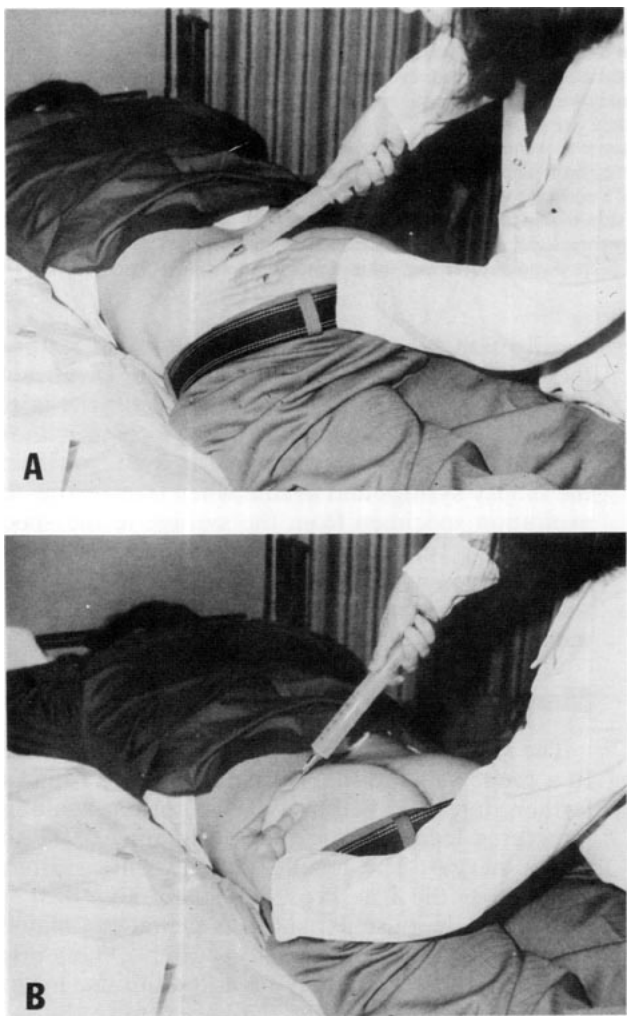

FIGURE 1. The subject is prone. Biopsy needle is within subcutaneous fat of farther side, parallel to the skin. The piston of the syringe is fully retracted. The skin may be stabilized or pinched into a track for the needle.

While maintaining the vacuum, the entire syringe and needle is moved back and forth within the fat pad by using a vigorous pistonlike motion by moving the entire arm, hand and retracted syringe from the shoulder (Fig. 1). The needle is kept parallel to the skin to avoid unanesthetized (and vascular) muscle tissue. The fat pad may be stabilized, retracted or squeezed into a tunnel for the needle with the free hand. Fat particles and liquified fat suspended in the xylocaine will appear in the syringe barrel because of the vacuum. If the specimen becomes bloody, it is sometimes helpful to release the syringe from the needle, while leaving the needle in the fat pad. The specimen can be expelled into the specimen jar, maintaining sterility, and the aspiration biopsy can be resumed.

When the fat in the syringe appears adequate, the needle is removed, pressure is applied with sterile gauze over the biopsy site, and continued for 5 min. The needle is removed from the syringe, and the fat is expressed into the sample vial. The syringe piston is removed; solid fat globules may be transferred mechanically from the piston to the sample vial using the biopsy needle. Fat which remains in the syringe barrel is removed by rinsing the barrel with warm sterile saline. The outlet of the barrel is occluded (a fine gauge needle embedded in a rubber stopper works well for this purpose) and a small amount (5-cm^3) of saline is expressed along the sides of the barrel. The wash liquid is flushed into the sample vial by reinserting the piston and releasing the occluded outlet (Fig. 2). It is usually not necessary to flush the biopsy needle.

While the sample vials may contain blood, the solid particles float on the top. This technique usually yields 200 to 500 mg of fat (Fig. 3). Blood con-

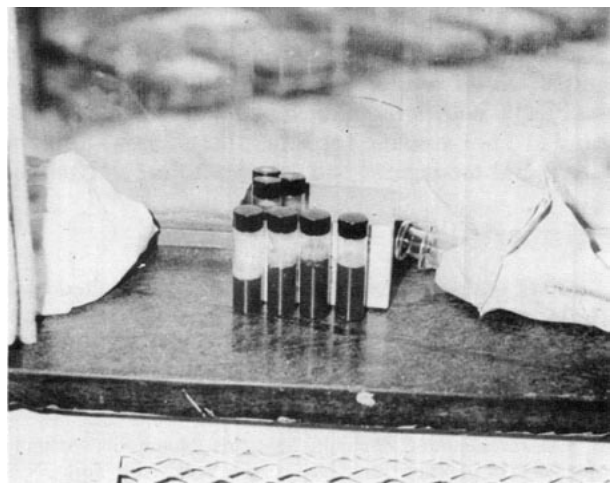

FIGURE 2. Transferring the specimen: washing the syringe barrel with warm sterile saline.

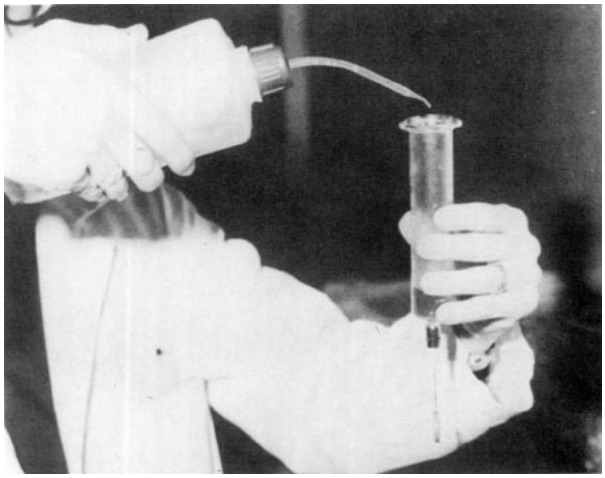

FIGURE 3. Sample vials containing fat specimens. About 200–500 mg fat is obtained.

tamination of the sample is not uncommon. However, it has not been a problem for the analysis of hydrocarbon residues.

Conclusion

This simple procedure is well accepted. The most serious complication we have seen has been the formation of a slightly tender hematoma, with tenderness lasting only 24 hr. Because of its simplicity, the procedure will also find use in the clinical diagnosis and treatment of hydrocarbon toxicity, when sequential measurements of residues may be necessary.

This research was sponsored by a grant from the National Institute of Environmental Health Sciences, ES 00928.

REFERENCE

1. Hirsh, J., et al. Studies of adipose tissue in man. Amer. J. Clin. Nutr. 8: 499 (1960).