Environmental Health Perspectives
Vol. 23, pp. 265-273, 1978

Persistent Liver Lesions in Rats after a Single Oral Dose of Polybrominated Biphenyls (FireMaster FF-1) and Concomitant PBB Tissue Levels*

by Renate D. Kimbrough,†‡ Virlyn W. Burse,† and John A. Liddle†

In a preliminary study, 12 male and 12 female weanling Sherman strain rats were given a single dose of 1000 mg polybrominated biphenyls (PBBs) FireMaster FF1 Lot 7042 kg/body weight as a 5% solution in corn oil. Three male and three female weanling rats were given corn oil. One day after dosing PBB blood levels ranged from 78 to 162 ppm and 42 days later they ranged from 1.1 to 2.99 ppm. The liver was the only organ with pathological changes. In a long-term recovery study groups of 20 male and female rats, 2 months old, were given 0 or 1000 mg PBBs/kg body weight as a single dose in peanut oil. Five rats per group killed 2, 6, 10, and 14 months after dosing had pronounced liver pathology, including hepatic porphyria in the female rats and neoplastic nodules also mainly in female rats. Chemical analyses of blood, liver, and adipose tissue for PBBs 10 and 14 months after dosing gave the following mean results. *Blood levels in females were 2.9 and 2.92 ppm, respectively, and males 0.94 and 1.34 ppm, respectively.* Adipose tissue levels in females were 1202 and 783 ppm and in males 713 and 866 ppm, respectively. The liver levels in females were 37 and 22 ppm and in males 60 and 63 ppm, respectively.

Introduction

Limited animal studies were conducted at the Center for Disease Control in 1975 to gain some understanding of the pharmacokinetic behavior of the polybrominated biphenyls (PBBs), FireMaster FF-1 (Lot No. 7042). The PBBs were accidentally mixed into cattle feed in Michigan in the summer of 1973 (*1*). During the course of these studies it was noted that, in the rat, the liver was the target organ for PBBs. The liver lesion produced after a single dose seemed to be persistent. These observations were subsequently explored further as part of the long-term followup study of the exposed population in Michigan in which the Center for Disease Control is collaborating with the Michigan State Health Department.

---

* The results in this paper previously published in part in Lancet II: 602 (1977).

† Toxicology Branch, Bureau of Laboratories, Center for Disease Control, Public Health Service, Department of Health, Education, and Welfare, Atlanta, Georgia 30333.

‡ To whom requests should be sent.

Preliminary Acute Studies

Methods

A total of 15 male and 15 female weanling Sherman strain rats were divided according to a table of random numbers into four groups of three control and 12 experimental rats for each sex. The three control male and three control female rats each were given a single dose of corn oil by stomach tube and the experimental rats received a single dose of 1000 mg/kg body weight of PBBs as a 5% solution in corn oil. The PBBs were dissolved in the corn oil by sonification. The rats were fasted 15 hr before dosing. One control and four experimental rats per sex were killed 24 hr, 8 days, and 42 days after dosing. Blood was collected by cardiac puncture under ether anesthesia and submitted for chemical analysis. Adipose tissue was submitted for chemical analysis at autopsy. Organs were fixed in 4% formaldehyde and tissue sections stained with hematoxylin and eosin. Selected sections from paraffin embedded tissue were stained with Oil Red 0.

The liver, heart, lungs, spleen, kidneys, thyroid, parathyroid, and adrenals were examined microscopically. General methods for chemical analysis outlined in the EPA Compendium (*2*) were followed. Weighed samples of whole blood were extracted with hexane:ethyl ether (1:1) and eluted through micro-Florisil columns. Samples were analyzed by electron capture gas liquid chromatography. The efficiency of the extraction and clean-up was evaluated by fortifying whole rat blood with PBBs at several levels, mixing and keeping it under refrigeration for several days prior to analysis. The samples were analyzed by using a Hewlett-Packard gas chromatograph, Model 402, equipped with a ^{63}Ni electron-capture detector and a 3 ft × ¼ in. column packed with 3% OV-1 on 80/100 Chromosorb W HP. The electron-capture detection was operated in the pulse mode. Additional gas chromatographic parameters were as follows: pulse interval, 150 μsec; injection port temperature, 250°C; column temperature, 250°C; detector temperature, 320°C; carrier gas flow (He), 60 cm^3/min; scavenger gas flow (Ar/CH4; 90/10), 150 cm^3/min.

Adipose tissue and liver were extracted with petroleum ether and the amount of lipid was determined. The lipid extracts were treated with acetonitrile and 2% sodium sulfate. This mixture was extracted with hexane. The hexane extracts were eluted through micro-Florisil columns with a small amount of sodium sulfate at the top. Samples were analyzed by electron-capture gas-liquid chromatography. The gas chromatograph was a Varian 3700 instrument equipped with a ^{63}Ni detector operated in a constant-current pulse-modulated mode. The gas chromatograph was interfaced to a Hewlett-Packard Auto Sampler, Model 7671A, and a Varian CDS III microprocessor, similar to the automated system described by Bauman et al. (*3*). The column employed for these analyses was: 6 ft × ⅛ in. coiled column packed with 1% OV-101 on 100/120 Gas Chrom Q. Additional gas chromatographic parameters were as follows: column temperature, 235°C; injection port temperature, 250°C; carrier gas flow (N_2), 20 cm^3/min; detector temperature, 300°C.

Rat liver and adipose tissue were fortified at the concentrations measured in the respective tissues. Recovery of *in vitro* fortified blood samples was between 80 and 86% and for liver and adipose tissue 89 and 78%, respectively.

Three liver extracts and one fat extract were analyzed by an LKB 9000 gas chromatograph/mass spectrometer by using a 4.4 ft 3% OV-1 column. The data were processed by a System Industries 150 digital computer.

Results

The livers of the control rats and all other organs of the control and experimental rats were normal grossly and microscopically. The livers of the four male and the four female rats killed 24 hr after exposure showed microscopically slight vacuolation of the hepatocytes and slight cellular enlargement. Eight days after dosing, the liver cell enlargement and the vacuolation of the hepatocytes was much more pronounced. Increasing numbers of mitotic figures, multinucleated cells, general pleomorphism and cytoplasmic inclusions were noted. Small foci of necrosis and fibrosis were encountered. Similar, but less severe changes, were present 42 days after dosing.

Results of the chemical analyses of whole blood and adipose tissue are given in Table 1. Blood levels in male and female weanling rats were extremely high 24 hr after dosing (78–162 ppm). At 8 days they had decreased by a factor of ten and by 42 days they ranged from 1.1 to 2.99 ppm. The age period from 1 month (weanling) to 2½ months is a rapid growth period in the rats which may have influenced blood levels to some extent.

Table 1. Concentration of PBB in whole blood of male and female rats at different recovery times after a single dose of 1000 mg PBB/kg body weight given by gavage at 1 month of age.

No. of rats	Sex	Dose given, mg/kg	Days after dosing	PBB concentration range (and mean) ppm (mg/kg)
1	F	0	1	< 0.004
4	F	1000	1	89–153 (113)
1	M	0	1	< 0.003
4	M	1000	1	78–162 (117)
1	F	0	8	< 0.005
4	F	1000	8	11.1–26.0 (17.8)
1	M	0	8	< 0.002
4	M	1000	8	12.6–28.8 (17.5)
1	F	0	42	< 0.0011
4	F	1000	42	1.63–2.99 (2.5)
1	M	0	42	< 0.0008
4	M	1000	42	1.1–2.16 (1.53)

Weanling rats have much less adipose tissue than older rats. In female rats one day after dosing the mean PBB concentration in adipose tissue on a lipid basis was 9504 ppm and 8 days later it was 8146 ppm. One day after dosing the mean PBB adipose tissue level in males on a lipid basis was 3272 ppm and 8 days later it was 3579 ppm.

Long-Term Recovery Study

Methods

Four groups of 20 male and 20 female 2 month old Sherman strain rats were given 0 or 1000 mg PBBs/kg body weight by gavage as a 5% solution in peanut oil. The rats were fasted 15 hr prior to dosing. They were given water and laboratory chow *ad libitum* and were kept five rats to a cage. They were weighed first monthly and then bimonthly. Five rats per group were killed 2, 6, 10, and 14 months after dosing. Prior to killing, blood was collected by cardiac puncture under ether anesthesia. Oxalate was used as the anticoagulant. Organs were inspected grossly for abnormalities; the livers were weighed; and tissues from brain, heart, lungs, parathyroid, thyroid, liver, spleen, kidneys, adrenals, bladder, gastrointestinal tract, reproductive organs, and pituitary were fixed in 4% formaldehyde. Additional liver tissue, adipose tissue, and the blood obtained by cardiac puncture were frozen for chemical analysis. Hematoxylin and eosin stained tissue sections were examined with the light microscope. The same methods of chemical analysis as outlined above under preliminary acute studies were followed for the PBB determinations. The Student's *t*-test was used for statistical evaluation.

Additional groups of 25 male and female rats, 4 months old, were given 200 mg PBB/kg body weight in peanut oil as a 5% solution. Equal numbers of controls were given peanut oil. Five rats per group were killed 6 months after dosing and the livers examined microscopically. The remaining animals will be allowed to recover for longer periods of time.

Results

The weight gain of the rats is illustrated in Figure 1. No difference was noted between the control and the experimental rats. One of the female control and one of the male control rats, but none of the experimental rats, died. One female control rat was killed when moribund. One male rat killed 14 months after the administration of 1000 mg PBB/kg body weight had an oligodendroglioma of the brain.

The liver weights expressed as percentage of body weight are given in Figures 2 and 3. The livers of the experimental rats weighed significantly more than those of the controls at the 2, 6, and 10 month recovery period.

Two of the male control rats killed 10 months after dosing had fatty livers on gross inspection and on microscopic examination the centrolobular liver cells had vacuolated cytoplasm. The one female control rat that was killed when moribund had a

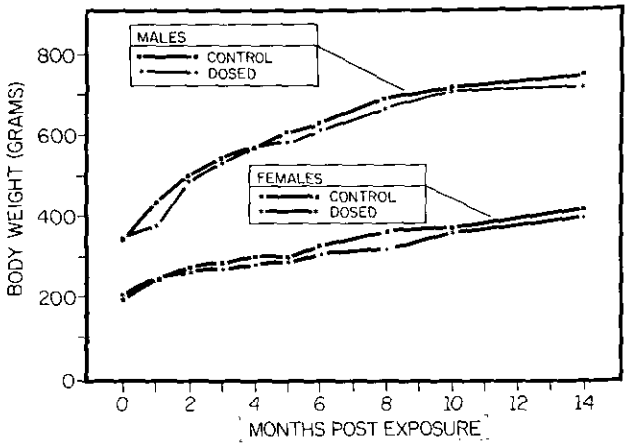

FIGURE 1. Mean body weights of control and dosed male and female rats over a 14-month recovery period.

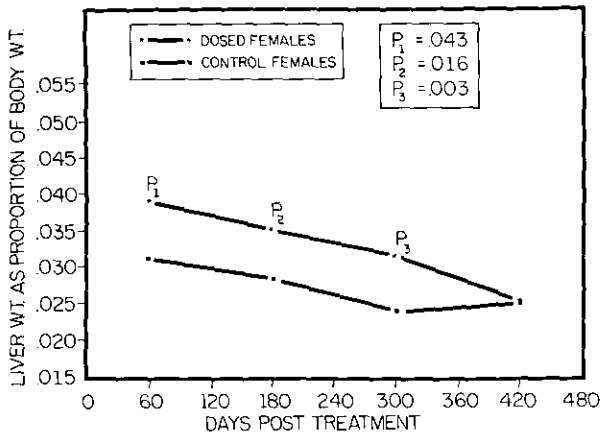

FIGURE 2. Mean liver weight expressed as percentage of body weight in dosed and control male rats 2, 6, 10, and 14 months after dosing.

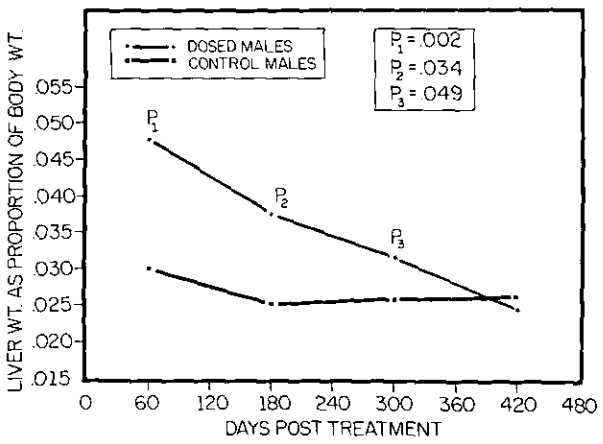

FIGURE 3. Mean liver weight expressed as percentage of body weight in dosed and control female rats 2, 6, 10, and 14 months after dosing.

large pituitary chromophobe adenoma and areas of necrosis at the base of the brain. The organs including the liver of all other control rats were normal microscopically. Grossly, the livers of three PBB dosed female rats showed pink fluorescence under ultraviolet light in some areas two months after dosing, indicative of porphyrin accumulation. On microscopic examination, the liver of the experimental female rats 2 months after dosing had enlarged hepatocytes in the center of the liver lobules. Inclusions were present in the cytoplasm of some liver cells. Focal round cell infiltrates and a slight increase in fibrous tissue were noted. The Kupffer cells were very prominent and contained an abundant amount of a brown pigment.

The livers of the male experimental rats 2 months after dosing were fatty and enlarged. On microscopic examination the liver cells particularly in the center of the lobules were enlarged with highly vacuolated or foamy cytoplasm. Inclusions were present in the cytoplasm. Pleomorphism, binucleation, multinucleation, and hyperchromatic nuclei were noted. Brown pigment was present in Kupffer cells. Small foci of fibrosis and necrosis were observed in two of the livers.

In male rats after a six month recovery period, the hepatocytes in the center of the liver lobules were enlarged, vocuolated, or had foamy cytoplasm and a general pleomorphism was noted (Fig. 4). In two livers mitotic figures and small areas of fibrosis were present (Fig. 5). Inclusions were observed in the cytoplasm of some cells. Similar observations were made in the livers of the female rats after a 6 month recovery period. In addition, inflammatory

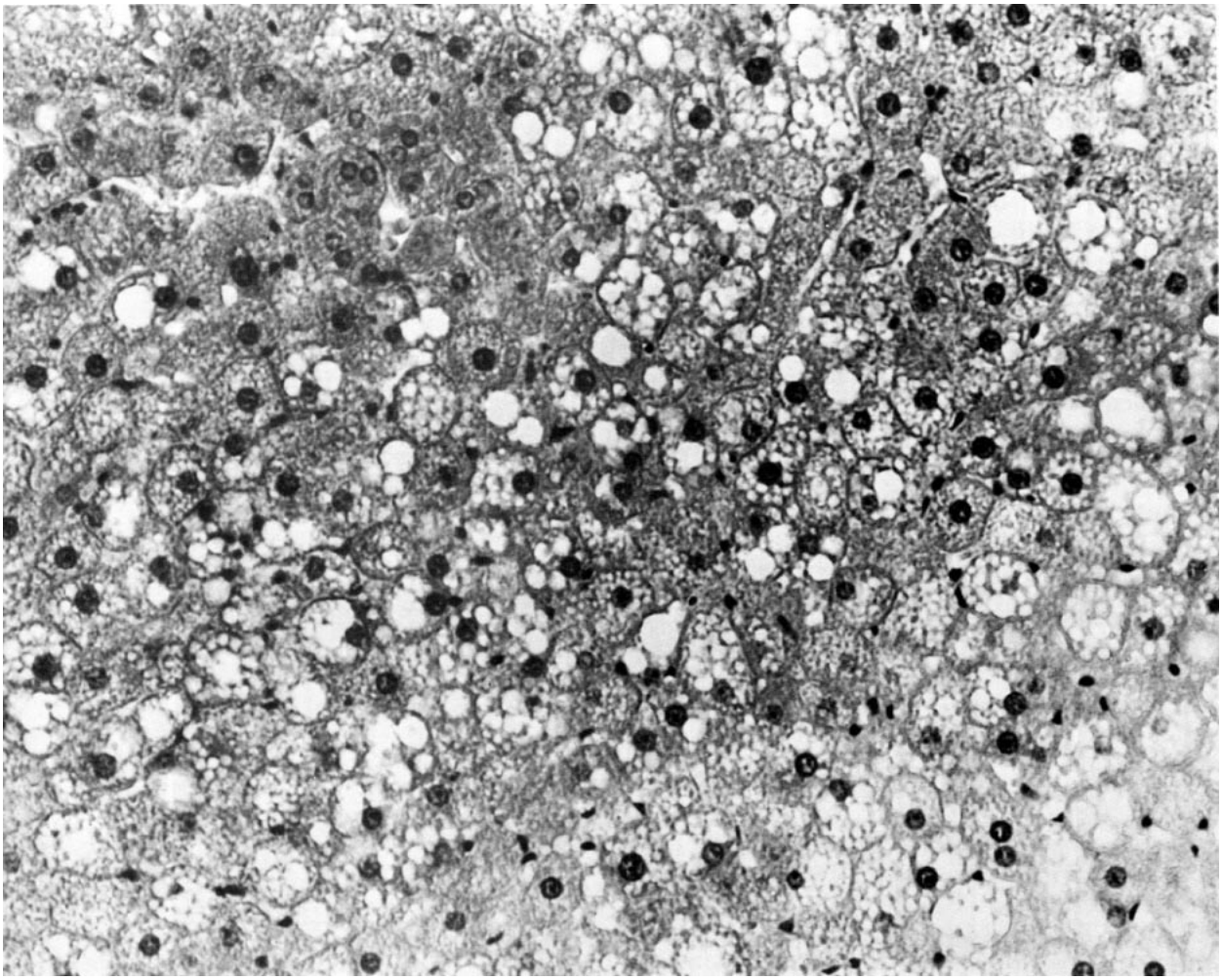

FIGURE 4. Liver section of a male rat 6 months after the rat had received a single dose of 1000 mg PBBs/kg body weight. Note the fine and coarsely vacuolated cytoplasm of the liver cells, megalohepatocytes, and general pleomorphism. HE, × 70.

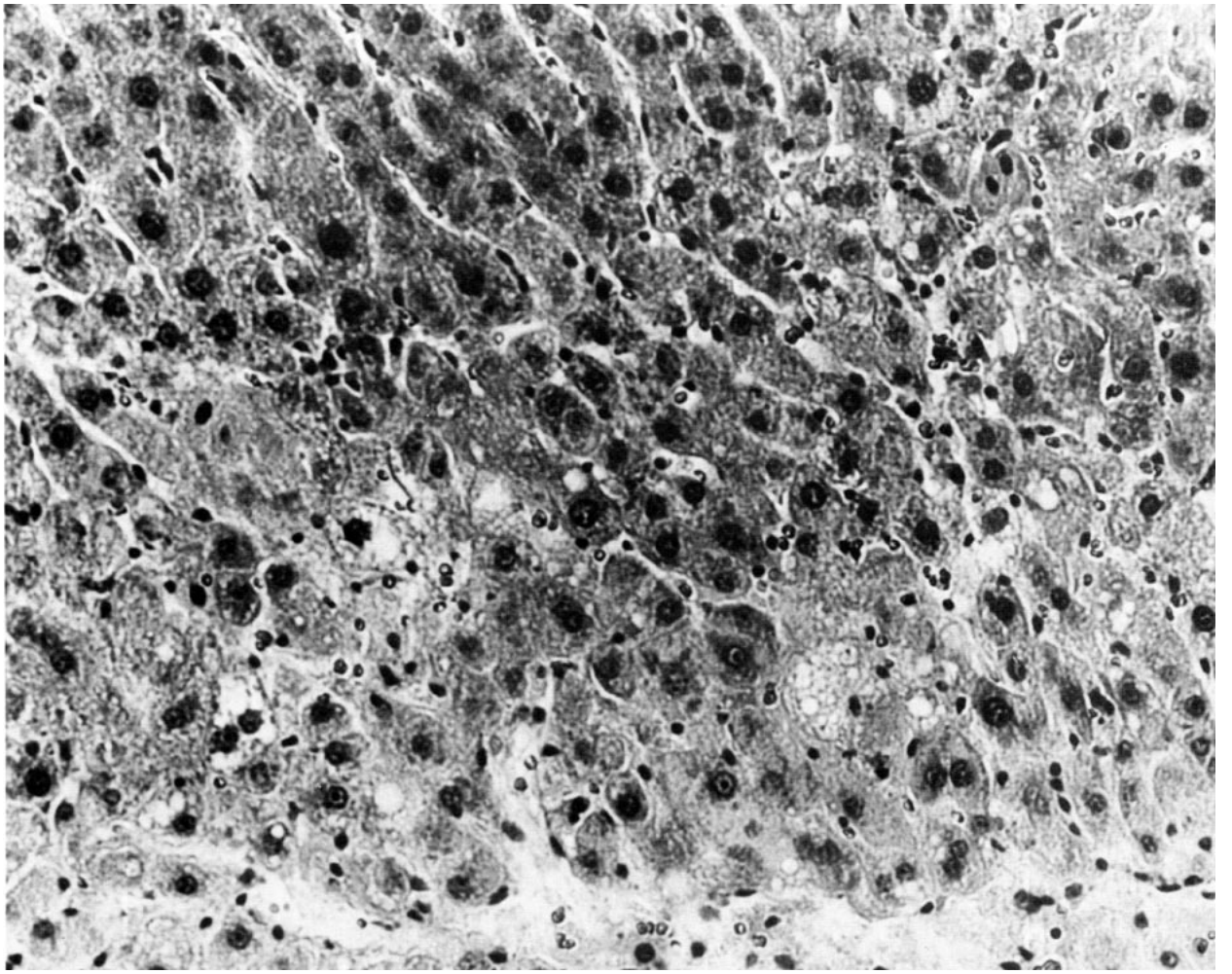

FIGURE 5. Liver section of a male rat 6 months after the rat had received a single dose of 1000 mg PBBs/kg body weight. Note hyperchromatic nuclei and beginning fibrosis. HE, × 70.

cells were noted within sinusoids and clusters of macrophages were present adjacent to central veins. Macrophages and Kupffer cells contained an abundant brown pigment (Fig. 6). This pigment made the livers appear black on gross inspection. The livers of all female rats at the 6-month recovery period showed pink fluorescence under ultraviolet light indicative of hepatic porphyria.

After a 10-month recovery period, the microscopic findings in the male rats were similar to the observations made earlier. In addition, intra- and perivascular round cell infiltrates and slight fibrous thickening of the vascular walls of the portal veins were noted. In the females clusters of macrophages were also present in the vascular walls. The dark discoloration of the liver as well as the pink fluorescence under ultraviolet light was still present at this time in female rats. In four of the livers of female rats, neoplastic nodules (synonym "hyperplastic nodules") and areas of cytoplasmic alterations were noted.

The neoplastic nodules were usually multiple, tan, and elevated above the surface of the liver. They measured from 0.1 to 1.5 cm in diameter. The cells of the nodules were enlarged and the cytoplasm was clear eosinophilic, or ground glass in appearance with frequent inclusions. The neoplastic nodules occupied areas equal to those of several liver lobules. The normal liver architecture within the neoplastic nodules was absent, and the cells were in sheets or irregular plates (Fig. 7). The surrounding liver plates were tangentially arranged and compressed in some areas (Fig. 8). In other areas the tumor cells were not well demarcated from the surrounding liver parenchyma. Foci or areas of alteration were also noted in these livers. The af-

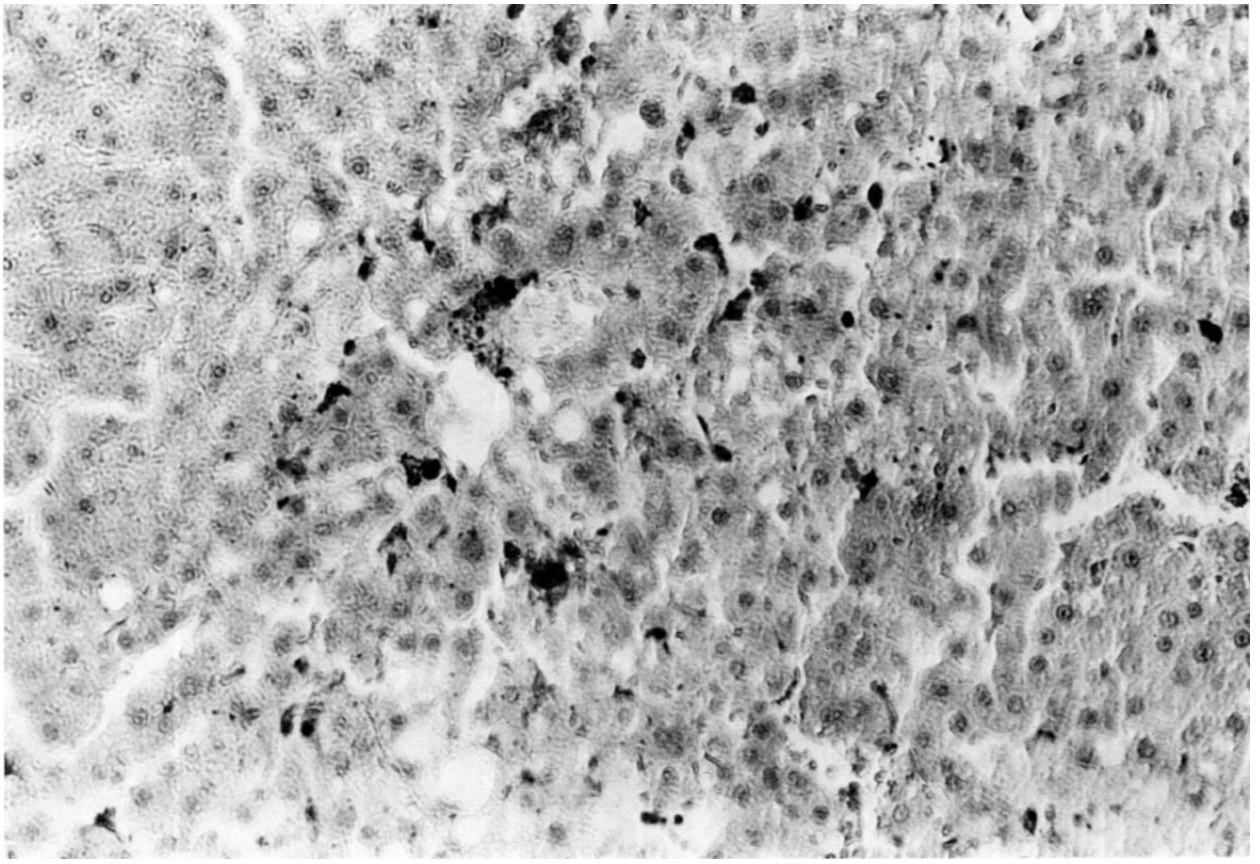

FIGURE 6. Liver section of a female rat 6 months after the rat had received a single dose of 1000 mg PBB/kg body weight. Note the pigment-laden macrophages. Oil Red O after paraffin embedding, × 70.

fected cells had ground glass or eosinophilic cytoplasm and were enlarged or were smaller and had basophilic cytoplasm. There were no architectural changes in these areas and plates of involved liver cells merged with surrounding liver parenchyma.

In the male experimental rats, after a 14-month recovery period, vacuolation of the hepatocytes was present in the center of the lobules, and the centrolobular liver cells were enlarged and occasionally multinucleated. The Kupffer cells still contained a brown pigment. A small neoplastic nodule as well as areas of alteration were noted in two livers.

In the female rats, after a 14-month recovery period, areas of alteration were noted in all livers and multiple neoplastic nodules were present in three livers. Generally, the parenchymal cells were pleomorphic with hyperchromatic enlarged nuclei. Kupffer cells were very prominent and contained a brown pigment. The livers still fluoresced.

Results of the chemical analysis of blood, adipose tissue, and liver from rats killed 10 and 14 months after dosing are given in Tables 2 and 3. In the female rats the PBB blood levels were higher than in the males, the PBB concentration in blood was the same for both sexes after a 10 and 14 months recovery period. The PBB concentration in the liver on a wet weight basis was lower in the females than in the males and appeared to be lower after a 14-month recovery period than after a 10-month recovery period. Since the amount of lipid in the livers of male rats was greater (Table 3) than in female rats, the higher PBB concentration in male rats may be related. The high PBB adipose tissue concentrations illustrate that PBB once absorbed is only very poorly excreted. Adipose tissue levels were high after a 10 and 14 month recovery period. In males no difference in adipose tissue levels was noted between the 10 and 14 month recovery period while in females the adipose tissue concentration was lower after a 14 than after a 10 month recovery period. Since the individual PBB adipose tissue levels varied widely, this may not represent a true decrease. In contrast to the results obtained in the

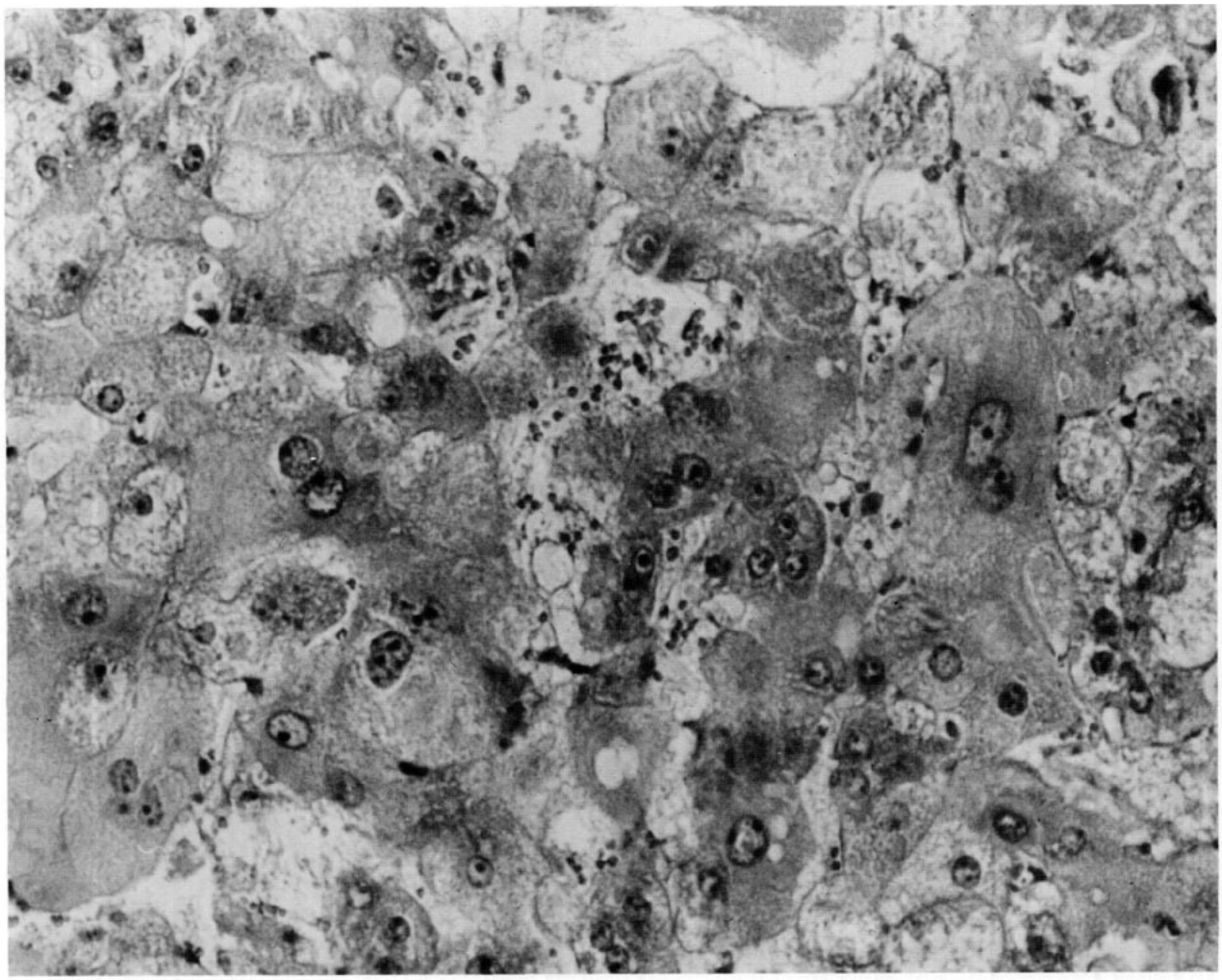

FIGURE 7. Section of a neoplastic nodule from the liver of a female rat 14 months after the rat had received a single dose of 1000 mg PBB/kg body weight HE, × 70.

liver, the PBB adipose tissue concentrations were similar in male and female rats.

Mass spectral analysis of three liver and one fat sample confirmed the presence of hexabromobiphenyl and small amounts of heptabromobiphenyl. Further results of these analyses are presented by Liddle et al. (*4*) in a separate paper.

The livers of the female rats given a single oral dose of 200 mg PBBs/kg body weight followed by a 6-month recovery period were dark on gross inspection and fluoresced under ultraviolet light. The livers of the male rats were normal in color. Microscopic examination of liver sections from female dosed rats revealed enlarged vacuolated hepatocytes around central veins and abundant brown pigment in Kupffer cells. Occasional degenerated liver cells were also noted. In the male rats, vacuolation of liver cells and megalohepatocytes were present in the central areas of the lobules. The livers of all control rats were normal.

Discussion

Even though hepatocellular carcinomas were not observed in the experimental rats, neoplastic nodules are part of the spectrum of response to hepatocarcinogens and must be included in the evaluation of tumorigenesis (*5*, *6*). Further studies are necessary to establish the carcinogenic characteristics of PBBs.

The neoplastic nodules were more prevalent in female rats even though the PBB levels were higher in male rats. The mere presence of PBBs in the liver may not be the decisive factor. The somewhat higher lipid concentration in the livers of male rats may have protected the cells from the toxic effects of the PBBs.

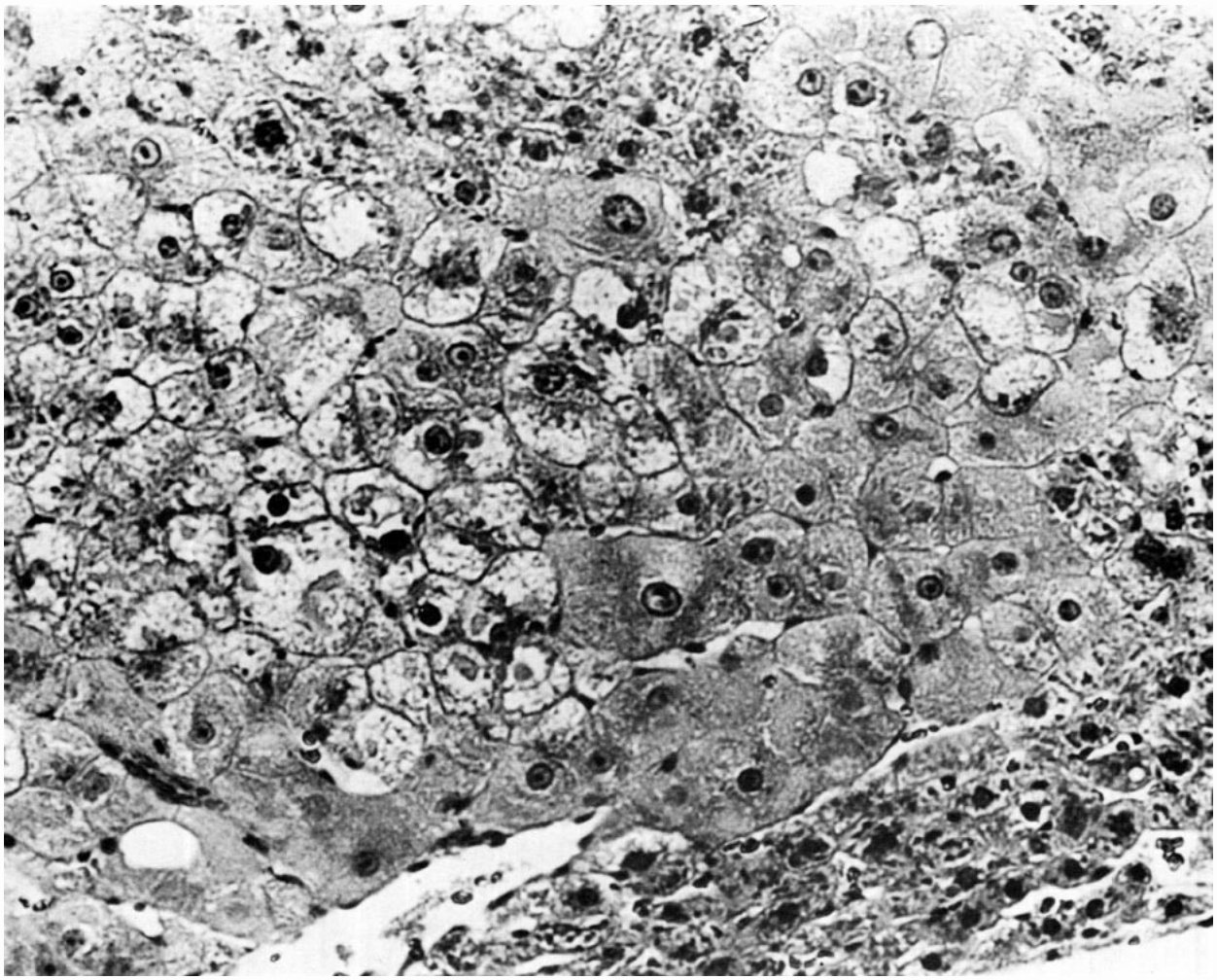

FIGURE 8. Section of the same neoplastic nodule as in Figure 7 at the periphery of the tumor, showing normal liver parenchyma in the lower right hand corner. HE, × 70.

Table 2. Concentration of PBB in whole blood of male and female rats at different recovery times after a single dose of 1000 mg PBB/kg body weight given by gavage at 2.5 months of age.

No. of rats	Sex	Dose given, mg/kg	Months after PBB dosing	Range (and mean) ppm (mg/kg)
1	F	0	10	< 0.0049
5	F	1000	10	2.00–4.66 (2.9)
1	M	0	10	< 0.0049
5	M	1000	10	0.55–1.35 (0.94)
1	F	0	14	< 0.005
5	F	1000	14	1.64–3.63 (2.92)
1	M	0	14	< 0.006
5	M	1000	14	1.20–1.42 (1.34)

A number of chemicals including PBBs, polychlorinated biphenyls, and chlorinated dibenzodioxins induce hepatic porphyria in mammalian and avian species (*7*). Jones and Sweeney (*8*) compared genetically responsive and nonresponsive mice to the induction of aryl hydrocarbon hydroxylase. After dosing with 2,3,7,8-tetrachlorodibenzodioxin, unresponsive mice did not show urine porphyrin excretion and the uroporphyrinogen decarboxylase activity was normal but was decreased in responsive mice. These results suggest a relationship between induction of aryl hydrocarbon hydroxylase and uroporphyrinogen decarboxylase activity which should be investigated particularly in respect to the carcinogenic potential of hepatic porphyria-inducing compounds.

Table 3. **PBB concentration and lipid content range (and mean) in liver and adipose tissue of rats given a single oral dose of PBB.**

No. of rats	Dose, mg/kg	Recovery period, months	Sex	PBB in liver, ppm (wet weight)	Concentration of lipid in liver, %	PBB in adipose tissue, ppm (wet weight)	Concentration of lipid in adipose tissue, %
				21–100.4	5.6–9.9	433.9–920.2	74.2–88.2
4	1000	10	M	(60.3)	(7.55)	(713.6)	(81.3)
1	0	10	M	0.04	7.2	0.73	83.6
				32–104.6	3.6–11.6	662.4–1170.4	80.8–86.6
5	1000	14	M	(63.2)	(7.0)	(866.3)	(83.5)
1	0	14	M	0.003	5.5	0.3	77.9
				27.5–58.7	3.4–5.1	856.7–1801.5	75.1–88.7
4	1000	10	F	(37.4)	(4.1)	(1201.7)	(83.5)
1	0	10	F	0	4.3	0.02	96.
				11–41	3.2–4.1	478.8–1264.1	81.5–92.2
5	1000	14	F	(22)	(3.8)	(783.3)	(85.5)
1	0	14	F	0.003	3.8	0.073	87.4

The results of the chemical analyses show that PBBs are very persistent in rats and can still be detected in high concentrations 14 months after a single oral dose. Not all isomers of the PBB mixture are probably retained equally well. Further studies are necessary to determine this. A liver lesion which develops in the exposed rats may not regress because of continuous internal exposure to some PBB isomers. It is interesting that between 10 and 14 months after exposure the liver decreases in size, but the PBB levels in the liver remain the same particularly in the males.

The elimination of halogenated aromatic compounds after cessation of exposure varies with different species and different compounds. When C^{14}-labeled dieldrin was given to rats and mice, 50–70% of radioactivity was eliminated within one week (*9*). A child ingested an unknown amount of dieldrin; the dieldrin adipose tissue level 3 days later was 47 ppm, 5 months after ingestion it was about 15 ppm, and 15 months later it was less than 1 ppm (*10*). On the other hand, adipose tissue levels of DDT in men decreased from 92.1 ppm to 68.3 ppm over a 37.8-month recovery period (*11*); in rats adipose tissue levels of DDT decreased from 115 ppm to 39 ppm over a 5-month recovery period (*12*).

Adipose tissue levels of Aroclor 1242, a mixture of polychlorinated biphenyls, decreased in rats from 133 ppm to 44 ppm over a 4-month recovery period and to 24 ppm over a 6-month recovery period (*13*).

In general, not quite as much material is stored after a single dose than after repeated doses and different species eliminate halogenated aromatic compounds as well as other chemicals at different rates. The examples given above seem to indicate that some chlorinated compounds are eliminated more slowly in men than in rats. If a toxic effect is produced in the organ primarily responsible for elimination, excretion may be further impaired. Elimination of at least some PBB isomers seems to be much slower than that of Aroclor 1242, dieldrin, and DDT in rats.

REFERENCES

1. Carter, L. Michigan PBB incident: chemical mix-up leads to disaster. Science 192: 240 (1976).
2. Thompson, J. F. Analysis of Pesticide Residues in Human and Environmental Samples. Environmental Toxicology Division, Health Effects Research Laboratory, U. S. Environmental Protection Agency, Research Triangle Park, N. C. 1974.
3. Bauman, F., et al. Chromatography automation: system control and credibility improvement through microprocessors. J. Chromatogr. Sci. 14: 177 (1976).
4. Liddle, J. A., et al. The chemical characterization of FireMaster FF-1 utilizing GC, HPLC and MS-GS techniques. Paper presented at Workshop on Scientific Aspects of Polybrominated Biphenyls, October 24–25, 1977, East Lansing, Mich.
5. Kimbrough, R. D., et al. Induction of liver tumors in Sherman strain female rats by polychlorinated biphenyl Aroclor 1260. J. Natl. Cancer Inst. 55: 1453 (1975).
6. Squire, R. A., and Levitt, M. H. Report of a workshop on classification of specific hepatocellular lesions in rats. Cancer Res. 35: 3214 (1975).
7. Strik, J. J. T. W. A. Species differences in experimental porphyria caused by polyhalogenated aromatic compounds. Enzyme 16: 224 (1973).
8. Jones, K. G., and Sweeney, G. D. Association between induction of arylhydrocarbon hydroxylase and depression of uroporphyrinogen decarboxylase activity. Res. Commun. Chem. Pathol. Pharmacol. 17: 631 (1977).
9. Baldwin, M. K., et al. A comparison of the metabolism of HEOD (dieldrin) in the CFI mouse with that in the CFE rat. Food Cosmet. Toxicol. 10: 333 (1972).
10. Garrettson, L. K., and Curley, A. Dieldrin. Study in a poisoned child. Arch. Environ. Health 19: 814 (1969).
11. Hayes, W. J., Jr., et al. Evidence of safety of long-term, high, oral doses of DDT for man. Arch Environ. Health 22: 119 (1971).
12. Ortega, P., et al. DDT in the diet of the rat. Its effect on DDT storage, liver function and cell morphology. Public Health Monograph No. 43, PHS Publ. No. 484, U. S. Govt. Printing Office, Washington, D. C. (1956).
13. Burse, W. V., et al. Polychlorinated biphenyls storage, distribution, excretion and recovery: Liver morphology after prolonged dietary ingestion. Arch. Environ. Health 29: 301 (1974).