Environmental Health Perspectives
Vol. 23, pp. 275–281, 1978

EM Changes and Other Toxic Effects of FireMaster BP-6 (Polybrominated Biphenyls) in the Mouse

by T. H. Corbett,* J. L. Simmons,† H. Kawanishi,† and J. L. Endres†

Groups of Swiss ICR mice were fed 1000 ppm polybrominated biphenyls (FireMaster BP-6) in rodent chow for 4, 8, 11, and 14 days. Control groups were fed standard rodent chow without FireMaster BP-6. Animals were killed at the end of each feeding period and the livers examined by electron microscopy. EM changes noted were progressive increase in size of hepatocytes, a decrease in rough endoplasmic reticulum, a marked increase in smooth endoplasmic reticulum, mitochondrial degeneration, increased lysosomes, and a decrease in glycogen. In addition, there was increasing proliferation of microvilli in bile canaliculi with increasing feeding times.

A group of mice fed 1000 ppm FireMaster BP-6 in rodent chow for 11 days had livers with a mean of 13.93% of total body weight as compared with 6.49% for the control group (P = 0.02).

Tissue distribution following ingestion of 100 ppm FireMaster BP-6 for 14 days was studied. Twelve weeks post-feeding, the tissue concentrations of hexabromobiphenyl in order of highest concentration to lowest were as follows: perithymic fat, perirenal fat, adrenal glands, thymus gland, liver and stomach.

Introduction

In 1975, we reported that the commercial mixture of FireMaster BP-6 was weakly teratogenic in mice, produced decreasing birth weights with increasing dosage during pregnancy in both mice and rats, and produced a marked increase in liver size and weight with a concomitant increase in P-450 activity (*1*). The dietary doses studied ranged from 50 to 1000 ppm. In the teratogenicity studies, rodents were fed FireMaster BP-6 in the diet from day 7 to day 18 of the pregnancy for mice and from day 7 to day 20 of the pregnancy for rats. The birth defects produced in mice included exencephaly and cleft palate. In the liver studies, the only dose tested was 1000 ppm in the diet for 11 days.

In addition, we performed a pilot study feeding 100 ppm FireMaster BP-6 to six timed-pregnant Swiss/ICR mice on days 7–18 of the pregnancy, with six identical mice on a normal diet as controls. The offspring of both groups were born spontaneously and nursed by their mothers and maintained for 15 months. Five of the six FireMaster BP-6-fed mothers died prior to termination of the experiment and unfortunately were not examined. At autopsy, the one remaining mother had multiple hyperplastic nodules throughout the liver which weighed 7.2 g. The hexabromobiphenyl concentration in the liver was 2.4 ppm. One of 22 male offspring had a solitary liver nodule while 0/20 female offspring had nodules. None of the control mice had nodules (*2*).

These findings prompted us to perform electron microscopic studies of liver from mice fed 1000 ppm Firemaster BP-6, perform tissue distribution studies of polybrominated biphenyls, and undertake a carcinogenicity bioassay of the chemical mixture in mice which is still in progress.

Materials and Methods

A group of 8-week-old male Swiss/IRC mice was fed a diet of granular rodent chow containing 1000

* Research Services, The Wayne County General Hospital, Eloise, Michigan 48132.
† The USVA Hospital, Ann Arbor, Michigan 48105.

ppm Firemaster BP-6 (polybrominated biphenyls) up to 14 days. During the feeding period, the animals were maintained in an environmental exposure chamber designed for use with toxic substances. A control group of similar mice was maintained in a second chamber and fed noncontaminated granular rodent chow. All animals were weighed on day 0, 4, 8, 11, and 14 of the study.

Three animals from each group were killed and the livers weighed and prepared for histologic examination on days 0, 4, 8, 11, and 14 of the feeding period. Liver specimens were minced into approximately 1–1.5 mm^3 pieces and fixed in 2.5% cacodylate-buffered gluteraldehyde at pH 7.4 for several days, after which tissues were rinsed in cacodylate buffer, post-fixed in 1% osmium tetroxide, dehydrated in graded ethanol, and embedded in Epon 812. (*3*, *4*). Sections were obtained with a Sorvall MT-2 microtome. Survey sections prepared for light microscopy, 1 μ thick, were made at least from seven blocks in each animal and stained with toluidine blue. Ultrathin sections were stained with uranyl acetate and lead citrate and examined with Hitachi HU-11C electron microscope.

Testicular weights of each animal were also recorded and the tissues prepared for light microscopy.

Two groups of 8-week-old Swiss ICR mice were maintained in separate environmental exposure chambers designed for use with toxic substances. One group was fed granular rodent chow containing 100 ppm FireMaster BP-6 (polybrominated biphenyls) while the other was fed with normal granular rodent chow. The experimental feeding period lasted 14 days.

At both 6 hr and 14 weeks post-feeding, three animals from each group were killed and various tissues or organs were isolated, weighed, and combined within each group for hexabromobiphenyl (HBB) analysis. Portions of tissues or organs were preserved in 10% formalin and prepared for histologic examination. The hexabromobiphenyl concentrations were determined by a commercial laboratory, Anatech Services, Ann Arbor, Michigan, using micro-Soxhlet extraction with diethyl ether and Florisil clean-up, and gas liquid chromatography (*5*, *6*).

Once the results of the first feeding were examined, a second study was initiated. Groups of 8-week-old Swiss ICR mice were again fed and maintained in a similar manner and then examined twelve weeks post-feeding.

Transplacental transfer of hexabromobiphenyl was studied in a pregnant dam fed 100 ppm FireMaster BP-6 from day 7 to day 18 of the pregnancy. The pregnancy was terminated on day 18 and the following tissues or organs were analyzed for hexabromobiphenyl: maternal fat, maternal liver, whole fetus, and fetal liver. A control group of pregnant dams was fed normal granular rodent chow, maintained and examined in a similar manner.

In addition, fat and thymus tissues from two 3-day-old human infants who had expired were examined for hexabromobiphenyl concentration.

Results

The results of the feeding study during which mice were fed 1000 ppm FireMaster BP-6 and examined after 0, 4, 8, 11, and 14 days are depicted

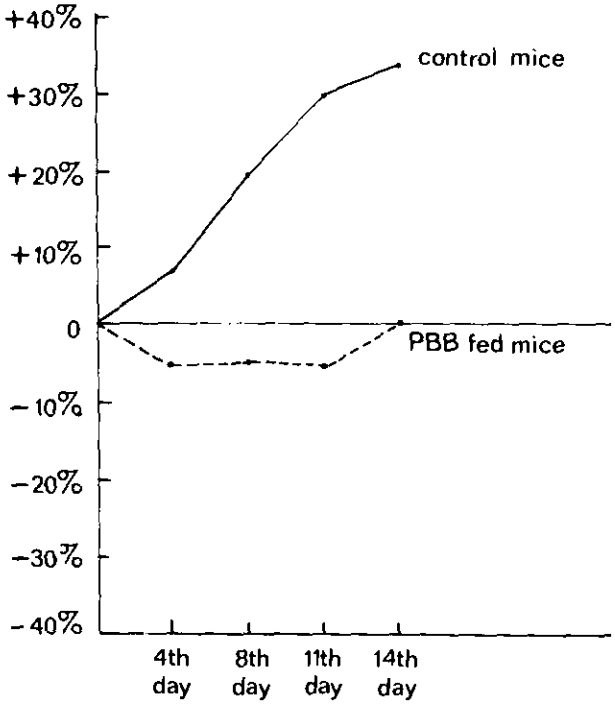

FIGURE 1. Per cent weight change of mice fed 1000 ppm FireMaster BP-6 and of control mice on days 0, 4, 8, 11, and 14 of the experiment.

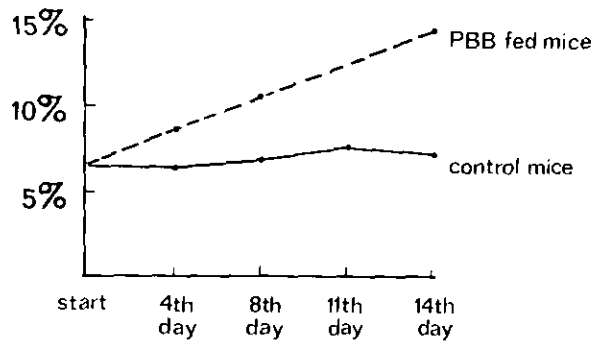

FIGURE 2. Changes in liver weight/body weight ratios (expressed as per cent) in mice fed 1000 ppm FireMaster BP-6 and control mice.

Table 1. Changes in ultrastructure of liver parenchymal cell cytoplasm following ingestion of FireMaster BP-6.

Days following HBB treatment (1000 ppm)	Size of hepatocyte	RER[a]	SER[b]	Mitochondria	Lysome	Glycogen
4	Mild increase	No change	Moderate increase	No Change	No change	No change
8	Moderate increase	Mild decrease	Moderate to marked increase	Slight degeneration	Slight increase	Slight decrease
11	Marked increase	Moderate decrease	Marked increase	Slight to moderate degeneration	Slight to moderate increase	Moderate decrease
14	Marked increase	Moderate decrease	Marked increase	Moderate degeneration	Moderate increase	Marked decrease

[a] RER: rough-surfaced endoplasmic reticulum.
[b] SER: smooth-surfaced endoplasmic reticulum.

Table 2. Change in ultrastructure of liver parenchymal cell nucleus and cell membrane following ingestion of FireMaster BP-6.

Days following HBB treatment (1000 ppm)	Nucleus		Cell membrane	
	Nucleolus (size and number)	Nucleoplasm	Disse space	Bile canaliculus
4	Slight increase	No change	No change	No change
8	Moderate increase	No change	No change	Slight proliferation of microvilli
11	Moderate increase	No change	No change	Moderate to marked proliferation of microvilli
14	Moderate increase	Occasional inclusions and more pseudo-inclusions	No change	Marked proliferation of microvilli

in Figures 1 and 2. Figure 1 shows that, while the control animals continually gained weight during the course of the experiment, the PBB-fed mice lost weight until day 14, when they returned to their starting weights. Figure 2 shows the liver/body weight ratios increased progressively with the length of feeding for the PBB-fed mice only. Testicular/body weight ratios did not vary significantly between the experimental and control mice.

Electron microscopy studies of liver from these animals revealed a number of progressive changes with increasing ingestion times of polybrominated biphenyls. These changes are noted in Tables 1 and 2. Cytoplasmic changes include (1) increasing size of hepatocytes (Fig. 3), (2) increasing rough and smooth endoplasmic reticulum (Figs. 3–5), (3) mitochondrial degeneration (Figs. 6–8), (4) increased lysosomes (Fig. 7), (5) decreasing glycogen content (Fig. 6), and (6) increasing proliferation of microvilli in bile canaliculi (Fig. 4a). Nuclear changes include increasing size and number of nucleoli and occasional inclusions and more pseudoinclusions in the nucleoplasm after 14 days of treatment.

The results of the feeding study during which the experimental group was fed 100 ppm FireMaster BP-6 for 14 days and animal tissues examined for hexabromobiphenyl concentrations both 6 hr and 14 weeks after feeding are shown in Table 3. In this series, the thymus gland had the highest concentrations at both examination periods. At the 6 hr examination, the hexabromobiphenyl concentrations, in decreasing order, were thymus gland, perirenal fat, liver, brain, spleen, pancreas, and testicles. The adrenal glands were not examined. At the 14-week examination, the hexabromobiphenyl concentrations, in decreasing order, were thymus, adrenal glands, perirenal fat, liver, testicles, spleen, brain, and pancreas. The ratio of hexabromobiphenyl concentrations for each organ or tissue/perirenal fat, expressed as per cent, is noted in parentheses in Table 3.

Because we suspected that the thymus gland had abnormally high concentrations of HBB due to adherent fat tags, additional groups of mice were fed and maintained in a similar manner and examined 12 weeks post-feeding. The thymus

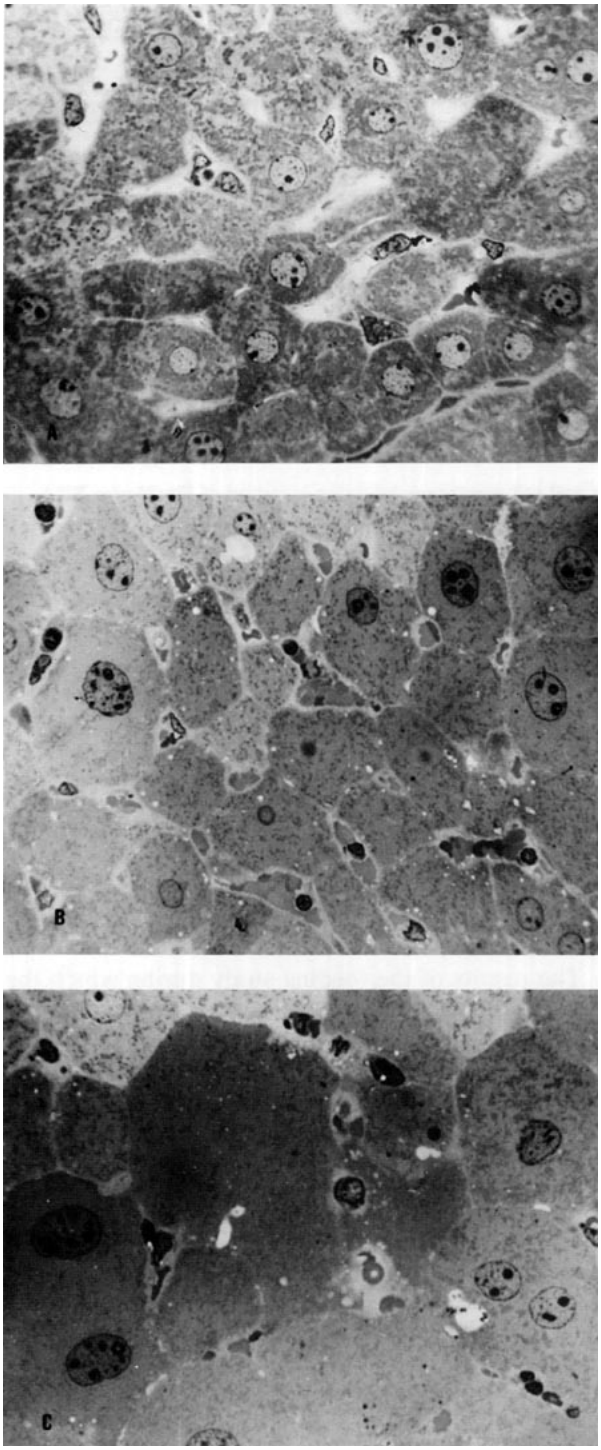

FIGURE 3. Light micrographs of (*A*) liver tissue from a normal mouse, (*B*) liver tissue 4 days after HBB treatment, exhibiting enlarged hepatocytes, and (*C*) liver tissue 14 days after HBB treatment. Note a prominently hyperplastic appearance of each hepatocyte. Epon-embedded thick section, stained by toluidine blue × 543.

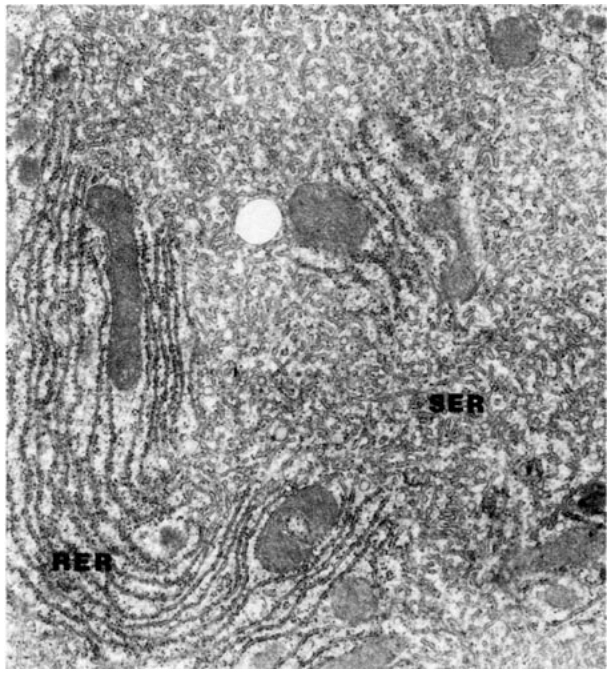

FIGURE 4. Electron micrograph of a portion of a liver parenchymal cell 4 days after the treatment of HBB. There are a number of parallel cisternae of rough-surfaced endoplasmic reticulum (RER), which appear to be responsible for proliferation of smooth-surfaced endoplasmic reticulum (SER) by extending the end parts of the cisternae. Aggregates of irregularly arranged proliferated SER fill up the cytoplasm. × 13,082.

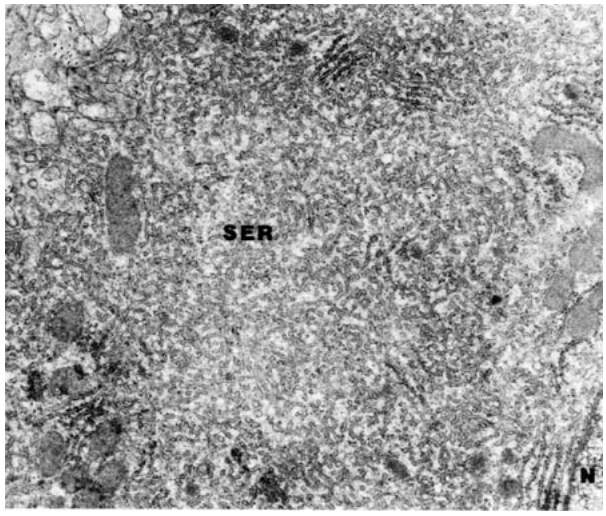

FIGURE 5. Electron micrograph of a portion of a hepatocyte 8 days after HBB treatment, showing abundant hyperplastic smooth-surfaced endoplasmic reticulum (SER), which occupies the majority of the cytoplasm. Degenerative changes of organellae are not seen. × 10,875.



FIGURE 6. Electron micrographs of portions of hepatocytes 14 days following HBB treatment: (*A*) proliferated smooth surfaced-endoplasmic reticulum (SER) is persistently present; (*B*) microvilli surrounding a bile canaliculus (BC) also proliferate markedly; (*C*) mitochondria (M) degenerate in variable degrees, exhibiting swelling, increased matrix density, loss of cristae, and vesico-vacuolation. Glycogen granules are diminished remarkably or lost entirely. × 22,666.

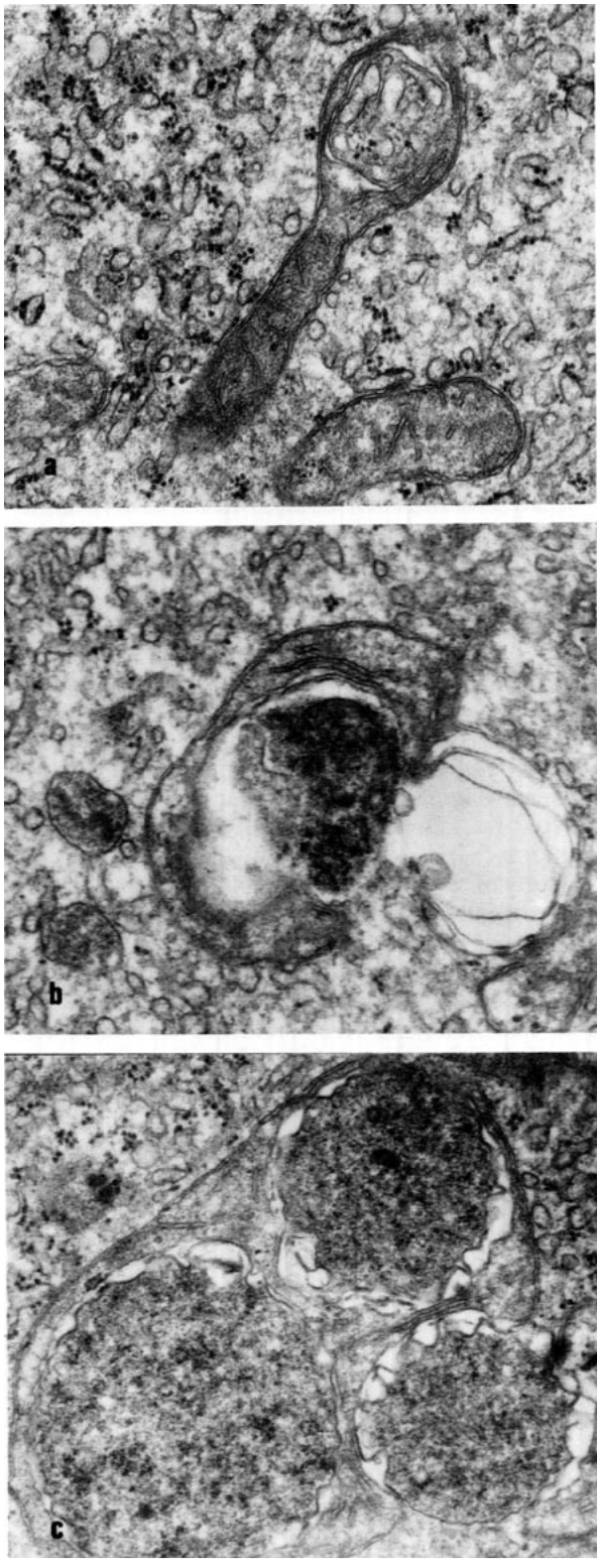

FIGURE 7. Mitochondrial autophagic alterations in HBB-treated hepatocytes, 14 days, demonstrating the process of formation of autophagic vacuoles (a type of lysosomes) (a→c). × 35,542.

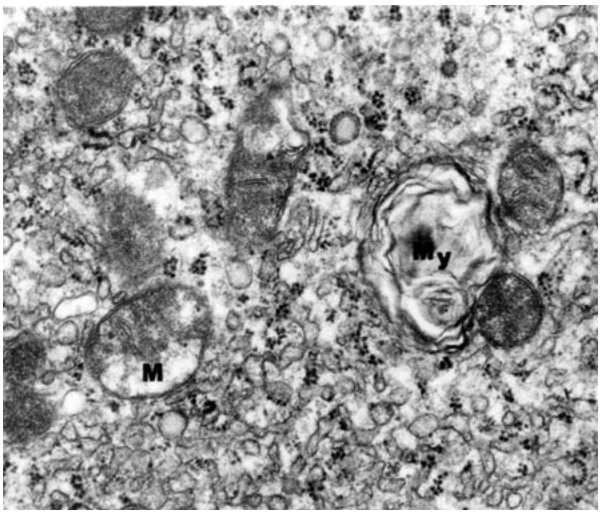

FIGURE 8. Another form of an autophagic vacuole consisting of myelinlike concentric membranes (My) 14 days after HBB treatment. M:Mitochondria. × 27,818.

glands and adrenal glands were carefully stripped of adherent fat under a dissection microscope before being sent to the laboratory for analysis. The results of this experiment are shown in Table 4. The concentrations of hexabromobiphenyl found in this experiment, decreased in the order, perithymic fat, perirenal fat, adrenal glands, thymus gland, liver, and stomach.

Results of the study of the transplacental transfer of hexabromobiphenyl are shown in Table 5. The maternal fat concentration after 100 ppm FireMaster BP-6 in the diet on days 7–18 of the pregnancy was 112.74 ppm, while the maternal liver had 12.02 ppm. The maternal liver/maternal fat ratio, expressed as per cent, was 11%. The whole fetus concentration was 0.95 ppm while the fetal liver concentration was 5.86 ppm. The whole fetus/maternal fat and fetal liver/maternal fat ratios, expressed as per cent, were 0.8% and 5.2%, respectively.

The results of analysis of fat and thymus specimens from two human infants, taken at autopsy, are shown in Table 6. The ratios of thymus/fat HBB concentrations, expressed as per cent, were 13% and 37%.

Table 3. Tissue concentrations of hexabromobiphenyl in mice after dietary intake of 100 ppm for 14 days.

	Tissue concentration, ppm			
Tissue	6 hr post-feeding	6-hr control	14 Weeks post feeding	14-week control
Thymus	390.9 (174.9%)	ND	49.8 (123.0%)	ND
Fat	223.4 (100.0%)	0.1	40.5 (100.0%)	—
Liver	33.2 (14.7%)	ND	9.7 (24.0%)	ND
Brain	12.0 (5.4%)	0.02	0.1 (0.2%)	ND
Spleen	2.7 (1.2%)	ND	2.4 (5.9%)	ND
Pancreas	7.0 (3.1%)	0.07	ND —	ND
Testicles	6.4 (2.9%)	ND	2.5 (6.2%)	ND
Adrenals	— —	8	40.8 (100.7%)	ND

Table 4. Tissue concentrations of hexabromobiphenyl in mice 12 weeks after dietary intake of 100 ppm FireMaster for 14 days.

	Tissue concentration ppm		
Tissue	FireMaster group		Control
Perithymic fat	96.4	(107.5%)	ND
Perirenal fat	89.7	(100.0%)	ND
Adrenal glands	29.8	(33.2%)	ND
Thymus gland	8.6	(9.6%)	ND
Liver	7.7	(8.6%)	ND
Stomach	5.5	(6.1%)	ND

Table 5. Maternal and fetal tissue concentrations of hexabromobiphenyl in mice fed 100 ppm FireMaster BP-6 in the diet on days 7–18 of the pregnancy.

	HBB concentration, ppm			
Group	Maternal fat	Maternal liver	Whole fetus	Fetal liver
FireMaster	112.74 (100.0%)	12.02 (10.7%)	0.95 (0.8%)	5.86 (5.2%)
Control	0.13	ND	0.04	0.11

Table 6. Fat and thymus concentrations of hexabromobiphenyl in 3-day-old humans.

	HBB concentration, ppm	
	Fat	Thymus
Patient I	0.091	0.012 (13.2%)
Patient II	0.062	0.023 (37.1%)

Discussion

We have demonstrated a number of cellular changes in livers of mice fed 1000 ppm FireMaster BP-6 for periods up to 14 days. On the basis of our previous studies showing marked increase in P-450 activity in livers of mice fed 1000 ppm FireMaster BP-6 for 11 days, the finding of marked increase in smooth endoplasmic reticulum was expected. The additional findings of marked bile canalicular microvilli proliferation and mitochondrial damage was unexpected. The long-term significance of these findings is unknown.

Using the concentration of hexabromobiphenyl in perirenal fat as standard reference of 100%, we have attempted to demonstrate, in a small series, the relative tissue distribution of this chemical in the mouse after several periods of time post-feeding. Liver and brain concentrations were relatively high initially after the feeding period; however, liver appears to have relatively concentrated the chemical

with passing time, while the brain concentrations appear to have dropped considerably. The concentration in the testicles started relatively low compared to perirenal fat but dropped more slowly, so that the relative concentration rose after 14 weeks. Adrenal glands appear to concentrate hexabromobiphenyl to the same degree as perirenal fat. If we disregard the first thymus studies as erroneous due to extraneous fat, the thymus gland had a relative concentration of 9.8% at 12 weeks post-feeding. This compares favorably to relative concentrations of 13% and 37% in two newborn human children. In light of the findings of Allen et al. (*7*) demonstrating hyperplasia of the gastric mucosa in monkeys following ingestion of the related polychlorinated biphenyls, the finding of persistent concentrations of hexabromobiphenyl in the stomach (relative concentrations of 6.1% 12 weeks after feeding) warrants investigation of possible similar effects in that organ with polybrominated biphenyls.

The persistence of hexabromobiphenyl in tissues up to 14 weeks after feeding suggests that delayed onset disease may occur in these organ systems. Further studies of the tissue distribution and effects of FireMaster BP-6 in rodents for longer time periods are in progress. Unpublished data from human autopsy fat specimens (*8*) have indicated that a majority of Michigan nonfarm residents have measurable levels of HBB with levels as high as 0.75 ppm.

Further studies of tissue distribution and effects of HBB and other brominated biphenyls and contaminants in both animals and humans are indicated.

REFERENCES

1. Corbett, T. H., et al. Toxicity of polybrominated biphenyls (FireMaster BP-6) in rodents. Environ. Res. 10: 390 (1975).
2. Corbett, T. H., Simmons, J. L., and Endres, J. L. unpublished data.
3. Satabini, D. D., Benoch, K., and Barrnett, R. J. Cytochemistry and electron microscopy: the preservation of cellular ultrastructure and enzyme activity by aldehyde fixation, J. Cell. Biol. 17: 19 (1963).
4. Luft, J. H. Improvements in Epoxy Resin Embedding Methods. J. Biophys. Biochem. Cytol. 9: 409 (1961).
5. Fehringer, N. Determination of polybrominated biphenyl residues in dairy products. J. Assoc. Office. Anal. Chemists 58: 878 (1975).
6. Manual of Analytical Methods for the Analysis of Pesticide Residues in Human and Environmental Samples. U. S. Environmental Protection Agency, 1974.
7. Allen, J. R., Carstens, L. A., and Barsotti, D. A. Residual effects of short-term, low-level, exposure of nonhuman primates to polychlorinated biphenyls. Toxicol. Appl. Pharmacol. 30: 440 (1974).
8. Simmons, J. L., and Corbett, T. H. unpublished data.