Environmental Health Perspectives
Vol. 26, pp. 97–105, 1978

Distal Axonopathy: One Common Type of Neurotoxic Lesion

by Peter S. Spencer* and Herbert H. Schaumburg*

Neurotoxic chemicals commonly produce retrograde degeneration of the axons of long and large nerve fibers in the central and peripheral nervous system. This produces a clinical picture of polyneuropathy in man and animals in which sensory and motor disturbances develop in the feet and hands then progress with time to the legs and arms. Distal axonopathy, as the underlying pathologic process is termed, is one of four principal types of neurotoxic diseases, the others including degeneration of neurons (neuronopathy), myelin sheaths (myelinopathy) and damage to the neurovasculature (neurovasculopathy). In the experimental animal, these four types of neurotoxic diseases can be distinguished by examining selected areas of brain and nerve tissues prepared by contemporary methods of tissue fixation. These procedures may form the basis of a new and sensitive assay for neurotoxicity.

The word "neurotoxin" conveys a variety of meanings. To the behaviorist, neurotoxins produce abnormal patterns of behavior; to the physiologist, a discrete functional impairment; to the pharmacologist, a metabolic alteration; to the neurologist, a clinical syndrome, and to the neuropathologist and neurochemist respectively, structural and biochemical alterations of the central or peripheral nervous systems. Part of this confusion arises from the practice of using the word neurotoxin to describe compounds with widely differing pathophysiological actions. For example, the term includes the biological neurotoxins such as venoms, curare, tetanus, and diphtheria toxins, pharmacological agents such as tranquilizers, narcotics, anesthetics, stimulants, antidepressants, hallucinogens and antimicrobials, and environmental pollutants such as heavy metals, pesticides, solvents, and a variety of other industrial chemicals (*1*).

There is a paucity of information on the neurotoxic effects of most compounds, and this lack of data prevents the development of a systemic classification of neurotoxins. However, in general, it is important to distinguish between the acute, pharmacological and frequently reversible nervous system effects of a chemical or drug, and the structural, often irreversible damage more commonly associated with chronic exposure to a compound. This paper is concerned with the morphological aspects of neurotoxicity.

Establishing Normative Data

The examination of the structure and pathology of the nervous system is difficult because of technical problems relating to tissue preparation. Conventional methods of tissue analysis which utilize light microscope examination of sections of formaldehyde-fixed, paraffin-embedded autopsy and biopsy material are unsatisfactory for the assessment of neurotoxicity. The problem lies not in the use of the light microscope, but in the poor tissue preservation inherent with the conventional technique. Since there is poor structural resolution, it is impossible to achieve a sensitive morphological assay of neurotoxicity. Morphological techniques which overcome these problems and are within the scope of most histology laboratories, have been available for 20 years and are routinely used in academic research. These contemporary techniques employ perfusion fixation with buffered glutaraldehyde, post-fixation in osmium tetroxide, thin plastic sections, and general purpose stains (*2*). Although originally developed for use in conjunction with electron microscopy, such methods also provide optimal preparations of tissue for light microscope analysis. Resolution of structural detail is limited only by the microscope and not by the tissue

* Neurotoxicology Unit, Rose F. Kennedy Center, Albert Einstein College of Medicine, Bronx, New York 10461.

preservation. Artefacts are minimal and minute pathological changes are therefore readily detectable. The gain in sensitivity over conventional histological techniques is enormous, making possible a precise description of the type and character of structural damage. Other major advantages are that the perfusion process optimally fixes all organs for sensitive light microscope assay and that the same tissues are immediately available for electron microscope examination, should this be necessary. These technical considerations are important for the establishment of normative data on the structure of the nervous system. The advent of the new fixation methods, coupled with the introduction of the electron microscope, has made possible a precise description of the cellular elements of the central (CNS) and the peripheral nervous system (PNS) (*3*). The basic plan is common to both tissues. CNS nerve cells or neurons possess elongate axonal processes which communicate with the dendrites of other nerve cells via terminal axonal synapses. In the PNS, the axons of dorsal root neurons situated in spinal ganglia innervate sensory receptors, and motor neurons located in the spinal cord supply muscle fibers. The axon of nerve fibers is ensheathed by a chain of cells, the oligodendrocyte in the brain and spinal cord, and the Schwann cell in peripheral nerves (Figs. 1 and 2). In many fibers, this ensheathment takes the form of a multilayered membranous structure known as myelin, the membranes of myelin being continuous with those of the ensheathing cell. The junctions between each length of myelin sheath occur at regularly spaced intervals along the length of the nerve fiber. Here, at the nodes of Ranvier, the axon is attenuated and naked. Other components of the nervous system include astrocytes in the CNS and fibroblasts and collagen in the PNS. Blood vessels of varying sizes also permeate the brain, spinal cord and peripheral nervous system.

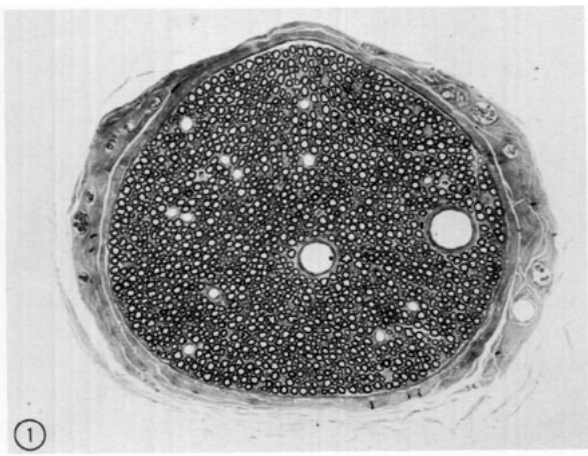

FIGURE 1. Normal rat tibial nerve fixed by systemic perfusion with glutaraldehyde and post-fixed in osmium tetroxide; 1 μm epoxy cross-section stained with toluidine blue. × 87.

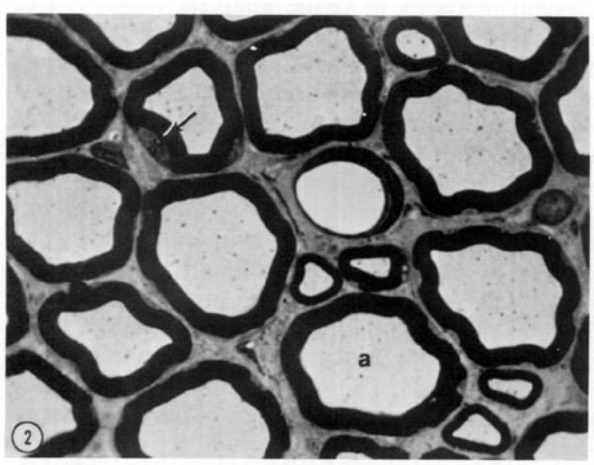

FIGURE 2. PNS myelinated nerve fibers in a lumbar ventral root. Fibers of varying sizes are composed of an axon (*a*) surrounded by a darkly-staining myelin sheath. Note the central capillary which has been cleared of blood cells by the systemic perfusion with glutaraldehyde. Arrow points to Schwann cell. × 980.6.

Classifying Neurotoxic Injuries

The statement that a compound is neurotoxic provides no information on the nature of its toxic

Table 1. Selected list of toxic chemicals producing structural damage to the nervous system.

Chemical	Response
Adriamycin	Neuronopathy
Aluminum (fibrillar change)	
Methylmercury	
Vincristine (fibrillar change)	
Acrylamide	Axonopathy
Alkyl and aryl phosphates	
Arsenic	
p-Bromophenylacetyl urea	
Carbon disulfide	
Clioquinol (CNS only)	
Diethyldithiocarbamiate	
n-Hexane	
Nitrofurans	
Methyl *n*-butyl ketone	
Polychlorinated biphenyls?	
Sodium cyanate?	
Thalidomide?	
Thallium	
Zinc pyrithione	
Acetyl ethyl tetramethyl tetralin	Myelinopathy
Alkyltin	
Cuprizone	
Hexachlorophene	
Lead?	
Tellurium	
Lead?	Neurovasculopathy

action on the nervous system. If the neurotoxic compound produces structural change, then the pathology will have a specific character. Some examples of these changes are breakdown of the neuron (neuronopathy), axon (axonopathy), ensheathing cell and myelin sheath (myelinopathy), or the vasculature (neurovasculopathy) (Table 1). Considerable effort is presently being directed towards the determination of the primary site of tissue damage. This information will be of use in developing more sensitive methods to assay for neurotoxicity and also provide a locus to study the biochemical abnormality generally believed to precede and precipitate pathology (*4*). It is also well established that primary structural changes in the nervous system may precipitate secondary and tertiary effects. For example, primary degeneration of the axon will also cause a secondary degeneration of the myelin sheath. This is the basis for the loss of myelin that accompanies distal axonopathies.

Distal Axonopathy

A common, clinically expressed response of the nervous system to chronic systemic intoxication with a neurotoxic drug or chemical is the development of peripheral neuropathy (*5*). This is manifested in a laboratory animal by the gradual appearance of symmetrical hindlimb weakness, ataxia and other gait disturbances such as a broad-based hindlimb locomotion. As intoxication continues, the lower extremities become progressively weaker and the animal loses weight. Eventually, the forelimbs become weakened and the animal is rendered quadriplegic. The animal can be maintained in this debilitated condition for some time, but continued weight loss, inadequate nutrition, and nervous system dysfunction eventually result in death. However, if the neurotoxin is removed, in time the animal will slowly recover, regain strength over a period of many months, and eventually be able to conduct the full spectrum of body movements. Recovery is never complete, however, because irreversible changes in the central nervous system may leave some residual spasticity and ataxia which only appear when the peripheral nervous system has regenerated and muscle strength has been regained (*6*).

The neuropathology underlying these toxic neuropathies has been studied in detail for some compounds, notably acrylamide, tri-*o*-cresyl phosphate, *n*-hexane and methyl *n*-butyl ketone. It has been demonstrated both by light and electron microscopy that these neurotoxins first affect the distal parts of axons located in the central and peripheral nervous systems (*7*). The choice of axons which are damaged seems to be related to the diameter and length of the axon, long and large axons initially undergoing distal axonal degeneration and, subsequently, progressively shorter and small axons degenerating in a similar manner. This type of pathology is known as distal axonopathy (*8*). Another feature of these diseases is that the axonal degeneration spreads towards the nerve cell body with time, and continued intoxication. This characteristic pattern has led to the use of the term "dying-back" in connection with these neuropathies.

The distal (dying-back) axonopathies associated with acrylamide and *n*-hexane intoxication have been most thoroughly studied and represent paradigms for other neurotoxic injuries of this type. The most dramatic clinical features of these diseases in man and in animals are attributable to changes in the peripheral nerves (i.e., peripheral neuropathy). However, recent experimental work has demonstrated that vulnerable axons in both peripheral and central nervous systems die back contemporaneously. Thus, long ascending spinal cord tracts projecting to the medulla oblongata and the cerebellum, involved in sensory perception and motor coordination, begin to die-back at the same time as hindlimb nerve fibers. Descending spinal cord tracts involved in motor control undergo similar changes. Shorter nerve tracts become involved later as the disease develops. At this time, the shorter PNS nerve fibers supplying the forelimb, CNS optic nerve tracts responsible for conducting visual information and tracts in the hypothalamus also become damaged (*9*). Comparable pathological changes are believed to be responsible for the clinical picture of neuropathy in man which may include weakness of the lower limb and hands, stocking-and-glove sensory loss, loss of limb reflexes, optic nerve degeneration and changes in mentation.

Principles of Neurotoxicity Testing

Several points require emphasis in designing neurotoxicity tests for the detection of neurotoxic diseases such as distal axonopathies. Firstly, it has to be clearly understood that the nervous system changes are a response to systemic intoxication irrespective of the route of administration of the toxic compound. The causation of axonal damage is not understood, but is generally assumed to result from one or more discrete metabolic neuronal lesions produced by the neurotoxic agent. Secondly, there is an all-or-none response to a neurotoxic agent which produces structural change. Once the appro-

priate species, level, and duration of intoxication have been established, then 100% of animals will display nervous system damage. Thus, in contrast to carcinogenicity testing where large numbers of animals must be used because response is variable, relatively small numbers of animals may be confidently used to assay for neurotoxicity. A third principle underlying neurotoxicity testing is the need for subacute or chronic testing protocols. This is very significant, since some neurotoxic agents produce entirely different and unrelated effects depending on the dosage. For example, *n*-hexane produces a pharmacological and reversible CNS narcosis in rodents at levels of 30,000 ppm administered for 60 min (*10*). By contrast, only a few hundred parts per million administered continuously over a period of many weeks will precipitate a central-peripheral distal axonopathy (*6*). Another example is provided by the *o*-cresyl phosphates (*11*). After acute dosing, these compounds produce striking reversible neuromuscular blockade because of their anticholinesterase properties. However, the well known delayed neurotoxic effect produced by these compounds is entirely unrelated to inactivation of this enzyme. In the delayed distal axonopathy caused by cresyl phosphates, there are striking changes in spinal cord tracts and degeneration of peripheral nerves. Axonal degeneration is again the primary event, and this eventually results in fiber loss with the attendant removal of the myelin sheath. In conventional histological preparations, this late change appears as a loss of myelin. This observation has given rise to the so-called "demyelination" assay for neurotoxicity in fowl, widely used in testing laboratories and presently being recommended by the U. S. Environmental Protection Agency for the testing of pesticides for neurotoxic properties. Not only is the name "demyelination" a misnomer (see Table 1), the histopathological procedure employed is not capable of revealing the early primary axonal change. It should be clear from the foregoing that such a test for neurotoxicity is totally inadequate.

Sensitive techniques using the contemporary tissue preparation methods described above have to be developed. Care must be taken to sample appropriate areas of the nervous system because distal axonopathies are diseases which move in space with time. Since nerve fibers in spinal cord tracts and peripheral nerves die back from their extremities over a period of many months, it would be inappropriate to attempt to detect early changes by sampling the top of the sciatic nerve and a slice of the brain. Experience with experimental hexacarbon and acrylamide neuropathies has also illuminated another important problem regarding the choice of behavioral or morphological methods to detect the earliest evidence of neurotoxicity. It is quite clear from these studies that it is possible to detect discrete pathology in the nerve fiber axon before any change in locomotion appears (*12*). Therefore, in the distal axonopathy group of neurotoxic diseases, it seems evident that "state of the art" neuropathology presently provides the simplest sensitive assay for neurotoxicity. The same premise is likely to be true for diseases affecting other nervous system tissues, for example, the neuronopathies, the myelinopathies, and the neurovasculopathies. By contrast, morphological techniques will be quite useless for assessing the neurotoxic properties of those compounds which exert a purely pharmacological effect on the nervous system.

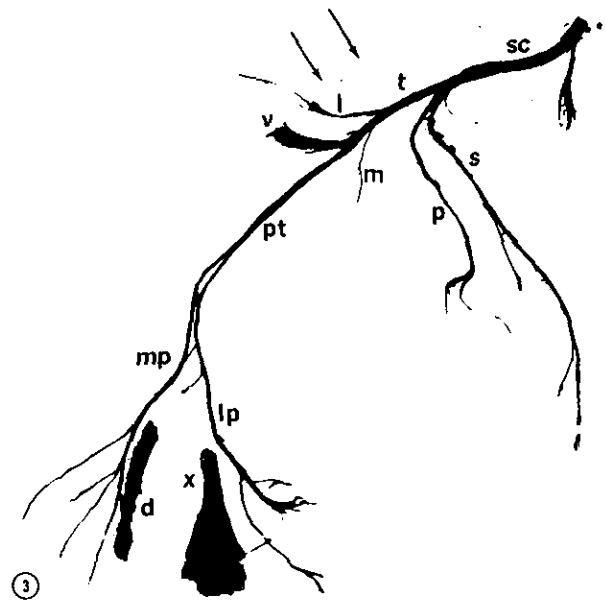

FIGURE 3. Gross dissection of the sciatic/tibial/plantar nerve complex and some associated intrinsic hindfoot muscles of the rat. The sciatic nerve (sc) branches into the sural (s), peroneal (p) and tibial (t) branches. At the level of the popliteal fossa, the tibial nerve gives a branch to the medial head of the gastrocnemius (m), a branch to the lateral head of the gastrocnemius (l) plantaris and soleus, and a cluster of branches accompanying the posterior tibial blood vessel to flexor hallucis longus, tibialis posterior and flexor digitorum longus (v). Distally, the posterior tibial nerve (pt) branches into lateral plantar (lp) and medial plantar (mp) nerves. The medial plantar nerve supplies three digits and there are two branches to the flexor digitorum brevis muscle (d). The lateral plantar nerve supplies two digits and, in addition, supplies the lumbrical muscle (x) with a delicate branch. The two arrows indicate the approximate level of the section illustrated in Fig 4. Fixed in glutaraldehyde and osmium tetroxide, dehydrated and embedded in epoxy resin. ×2. Reproduced by permission from Spencer and Schaumburg (*14*).

Developing a New Test for Neurotoxicity

Studies on the distal axonopathies produced by chronic intoxication with hexacarbon compounds or with acrylamide have revealed the vulnerability of large and long nerve fibers in the CNS and PNS (*13, 14*). Some of the largest, long PNS nerve fibers are contained within tibial nerves and supply calf musculature with motor and sensory innervation (Fig. 3). In the rat and the cat, these nerves also appear to be the first to develop signs of distal axonal degeneration, changes commencing in these fibers before they occur in the longer but smaller nerve fibers supplying the hindfoot. The tibial nerve at the knee, just proximal to the existing sensitive branches, would therefore appear to be the optimum site to assay for distal axonopathy in the PNS (Fig. 4). As in other fibers at later time points, axons first undergo swelling proximal to nodes of Ranvier because of an abnormal accumulation of filaments within the axoplasm at this site. The focal axonal swelling may displace myelin locally thereby producing short lengths of secondary demyelination. Eventually, nerve fibers undergo distal breakdown and form a chain of myelin ovoids. Such

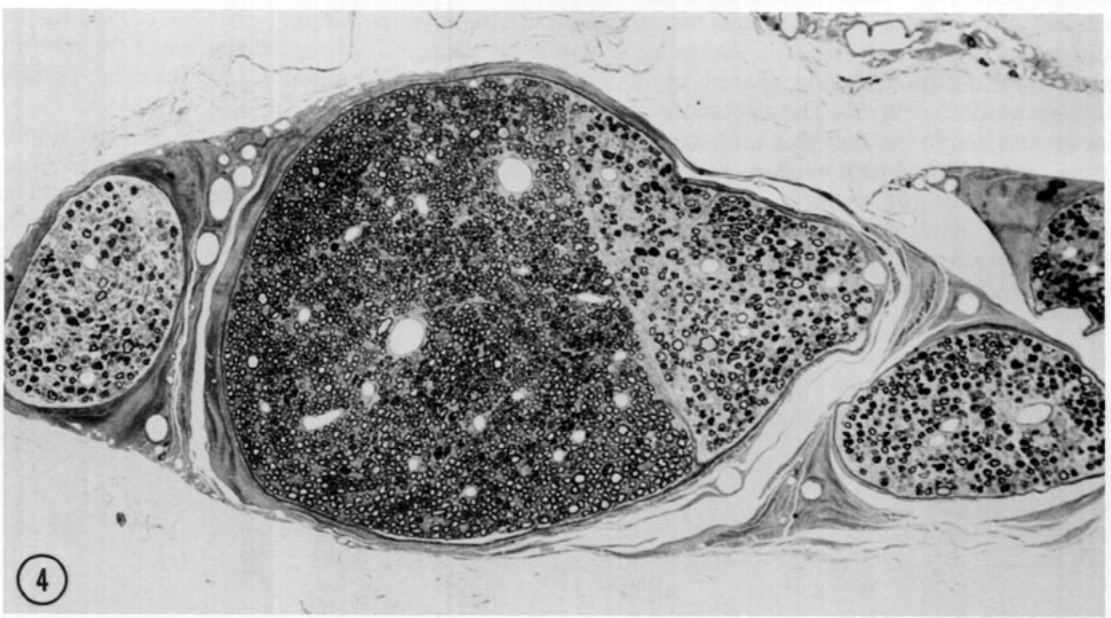

FIGURE 4. Intact tibial nerve (center) trunk and degenerating branches (right and left) to the calf musculature. This and Figures 5 and 6 are from a rat with hexacarbon neuropathy. ×120.



FIGURE 5. Single, teased nerve fiber showing focal swellings in the axon. *n* denotes node of Ranvier. ×170.

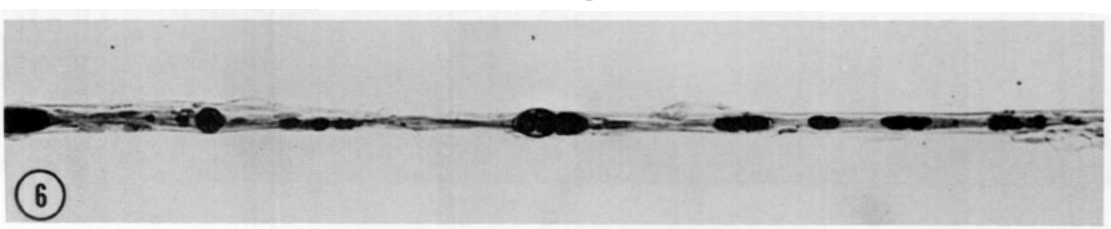

FIGURE 6. Single teased nerve fiber displaying a chain of myelin ovoids after undergoing complete degeneration. ×140.

changes are most readily recognizable not in histological sections but in nerve fibers which have been prepared by the modern methods described above and teased apart in liquid epoxy resin (2) (Figs. 5 and 6).

Teased nerve fibers also display vividly other types of specific pathology such as primary demyelination in myelinopathies, the rapid fiber degeneration which accompanies dorsal root ganglion neuronopathies and the demyelination accompanying neurovasculopathies. In the CNS, the caudal medulla oblongata is a useful locus to detect structural changes in neurotoxicities. In the distal axonopathies, the pathology seen in sections is always symmetrical and restricted to the gracile tracts located medially on the dorsal surface, the more laterally placed cuneate tracts being spared until late in the disease process (Fig. 7). The explanation for this phenomenon lies in the fact that long axons projecting from lumbar dorsal root neurons synapse in the gracile nucleus of the medulla oblongata. Since axons undergo distal degeneration in distal axonopathies, the spectrum of change seen in the PNS is concurrently taking place at the end of the gracile tract in the CNS. The cuneate tracts also project to the medulla oblongata, but because the fibers originate from cervical dorsal root neurons, axons are shorter, less vulnerable, and therefore commence degeneration later in the disease process.

Sampling the medulla oblongata also reveals the early changes in dorsal root neuronopathies and in myelinopathies. In these neuronopathies, all sensory neurons in dorsal root ganglia degenerate contemporaneously and, as a secondary effect, there is a rapid disintegration of the entire length of nerve fiber. In this situation, therefore, the gracile and cuneate tracts are equally affected at any one time (Fig. 8). In myelinopathies, primary demyelination would be scattered across the section of the medulla oblongata and not limited to any one nerve fiber tract.

The greatest caution must be taken in any morphological assay to exclude tissue changes unassociated with neurotoxicity. These may be caused by poor fixation, trauma, or advancing age. The recommended techniques for tissue preparation are satisfactory if the use of systemic perfusion is

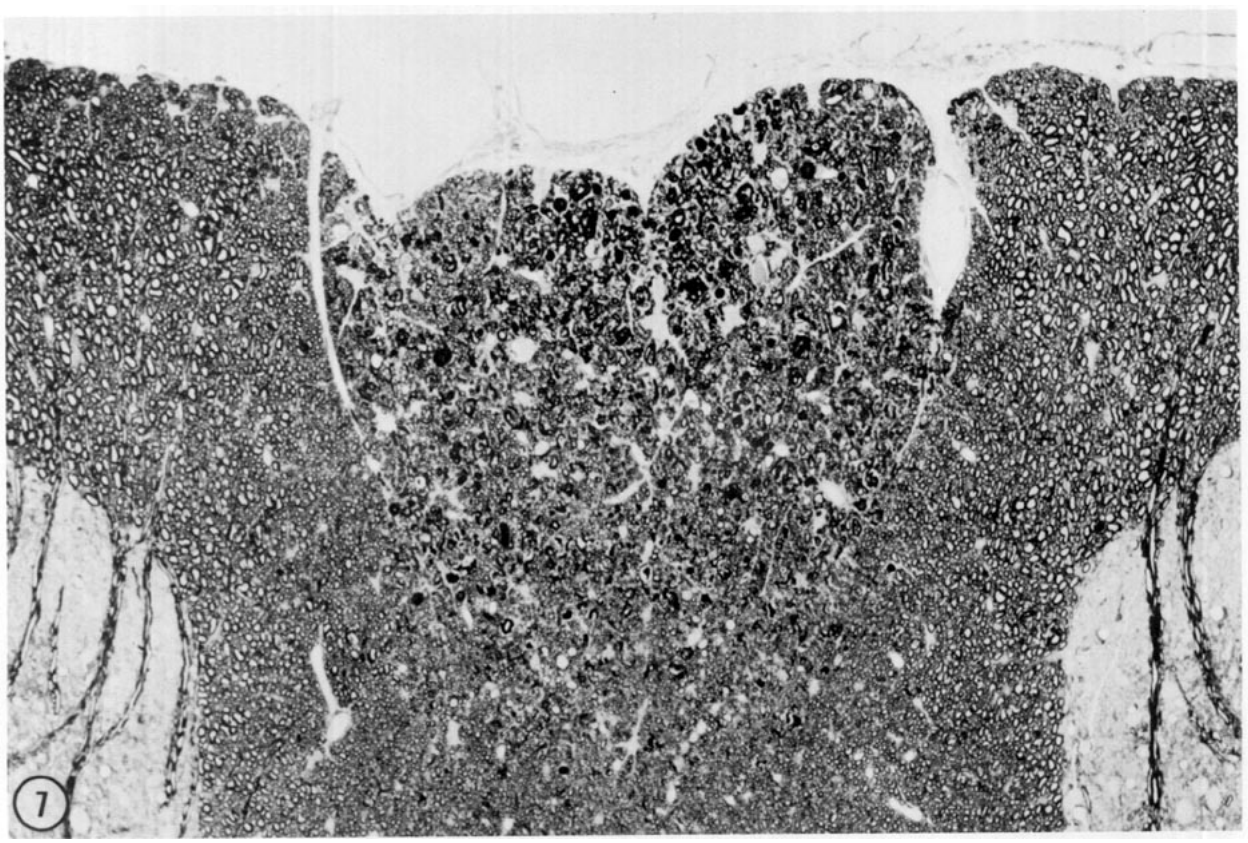

FIGURE 7. Medulla oblongata of a rat with hexacarbon distal axonopathy showing selective degeneration of the gracile tracts (center). ×200.

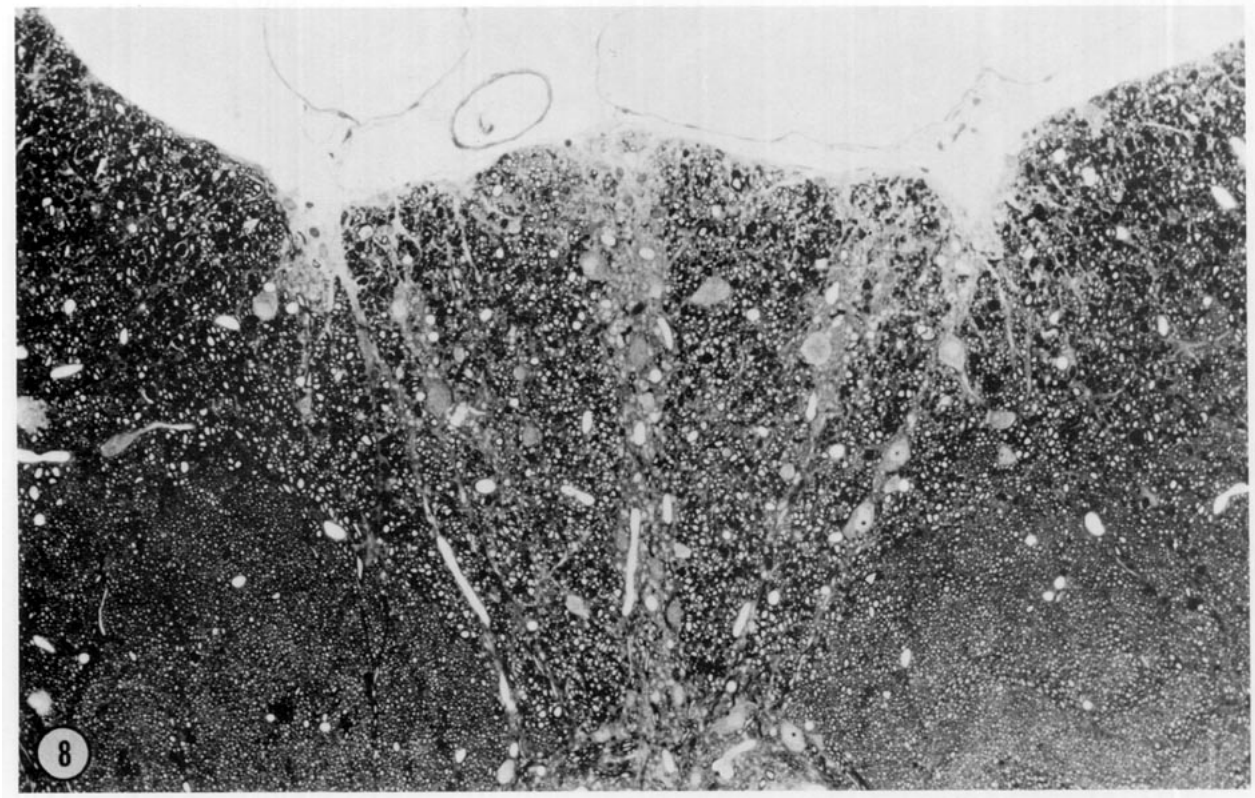

FIGURE 8. Medulla oblongata of a rat with adriamycin dorsal root neuronopathy showing degeneration of gracile (center) and cuneate (sides) tracts. ×200.

adopted. Immersion in glutaraldehyde is not a satisfactory substitute, since tissue penetration is poor, especially in the CNS, and the act of cutting PNS nerves can itself produce spectacular artefacts similar to real pathology (*2*, *15*). Trauma to exposed areas of plantar nerves is a natural consequence of locomotion in rodents and perhaps in other species (*16*). This is especially significant when the animal lives on floors constructed of wire mesh, the degree of damage increasing with time spent in the cage (*14*). Although animals caged on smooth floors for months or years also display some fiber damage at sites of vulnerability, the combination of smooth floors and young animals will serve to avoid this artefact. Using young adult animals also avoids the naturally occurring age changes which develop in the gracile tract of the medulla oblongata gradually over the animal's lifetime. These changes appear as axonal swelwings distinguishable in the light microscope from the swellings of hexacarbon neuropathy only by the presence of narrow clefts within the axoplasm in the aged animals (*17*) (Figs. 9 and 10).

In summary, therefore, by sampling two specific areas of the CNS and PNS, the tibial nerve at the knee and the medulla oblongata, it may be possible to recognize the early signs of change in three entirely different classes of neurotoxicity associated with structural damage. However, before such a new assay for neurotoxicity is recommended for use by the regulatory agencies, much additional work with other neurotoxins has to be conducted.

Neurotoxicity, Human Disease, and the Aging Process

There are remarkable similarities between the pathological and clinical expressions of the toxic distal axonopathies and the naturally occurring neuropathies associated with diabetes, uremia, vitamin deficiency, old age, and certain genetic-metabolic diseases of unknown causation (*8*, *18*). Recognition of neurotoxic mimicry of human neurological diseases places new emphasis on the importance of understanding the susceptibility of the nervous system to neurotoxic damage. Because mimicry exists, it is entirely possible that chronic exposure to neurotoxins will render man more susceptible to, or accelerate the onset of, the naturally

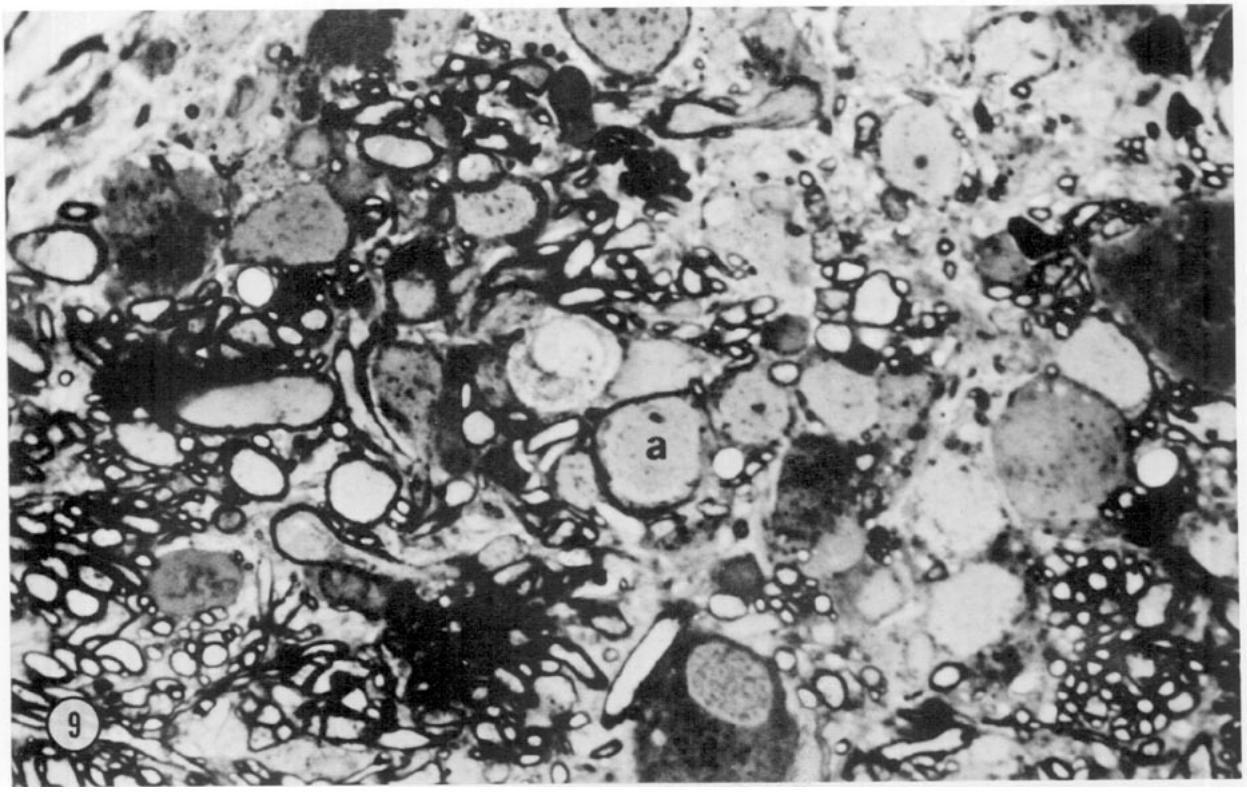

FIGURE 9. Giant axonal swellings (*a*) in the gracile tract of a rat with early hexacarbon distal axonopathy. ×460.

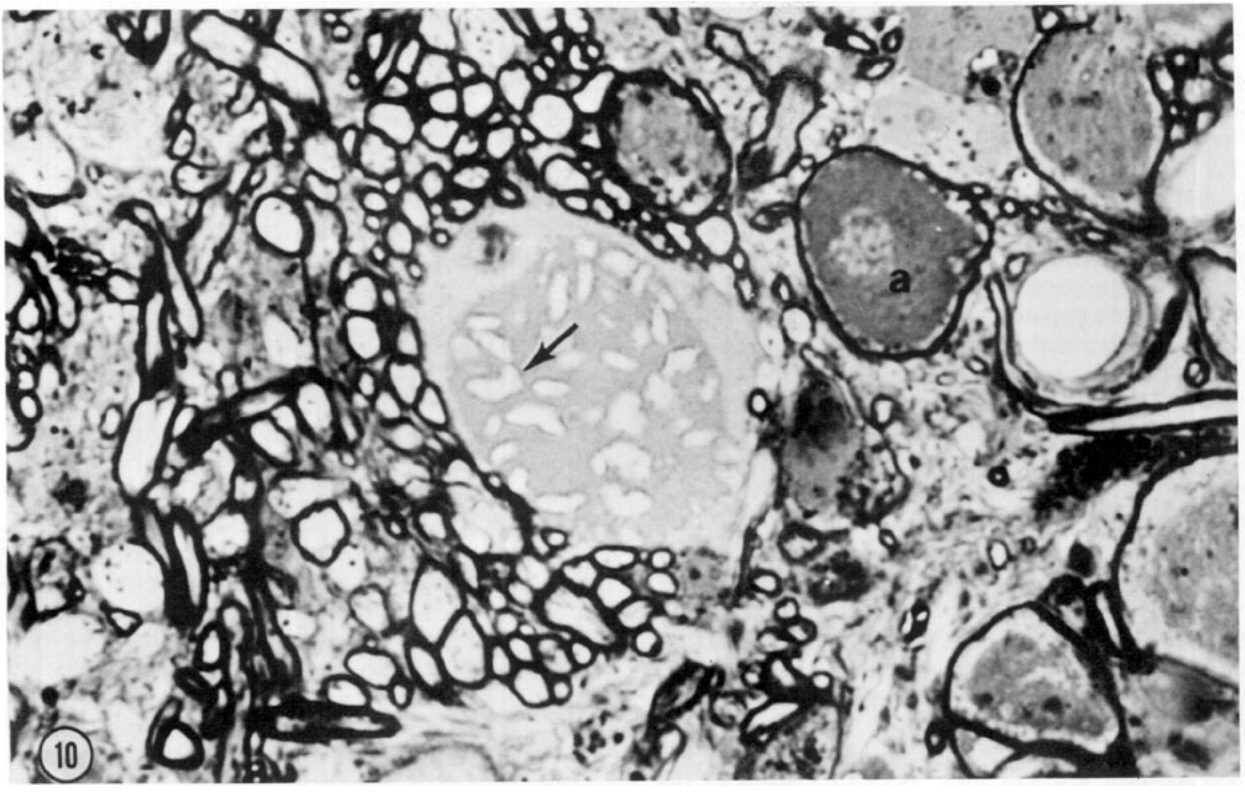

FIGURE 10. Axonal swellings (*a*) in an aged rat. Note the characteristic clefts (arrow) present within one axon. ×500.

occurring peripheral neuropathy and diminished neuronal reserve associated with aging. In establishing levels of exposure to any one neurotoxin, it will also be important to be aware of the existence of other neurotoxic substances producing the same effect or alterating the potency of the first compound. Such neurotoxic agents would be expected to produce additive, or even potentiating or synergistic effects. On the other hand, it will also be useful to employ selected neurotoxins as tools to develop animal models of those human diseases that they mimic for the purposes of determining etiology and identifying prevention or cure.

Monica Bischoff and Richard Conte are thanked for technical support and Elaine Kilduff and Marion Foulds for preparation of the manuscript.

This work was supported by USPHS grants OH 00535, NS 03356, and NS 13106, and grants from the American Cyanamid Company, Dow Chemical Company, Vistron Company, and Nalco Chemical Company.

REFERENCES

1. Roizin, L., Shiraki, H., and Grcevič, N. Neurotoxicology, Vol. 1. Raven Press, New York, 1977.
2. Spencer, P. S., and Bischoff, M. C. Contemporary morphological techniques for evaluating peripheral nerves. In: Management of Peripheral Nerve Problems, O. K. Omer and M. Spinner, Eds., Saunders, Philadelphia, in press.
3. Peters, A., Palay, S. L., and deF. Webster, H. The Fine Structure of the Nervous System, The Cells and Their Processes, Hoeber Medical Division, Harper & Row, New York, 1970.
4. Peters, R. Biochemical Lesions and Lethal Synthesis, Pergamon Press, New York–Oxford, 1963.
5. Dyck, P. J., Thomas, P. K., and Lambert, E. H. Peripheral Neuropathy, Vol. II, Saunders, Philadelphia, 1975.
6. Schaumburg, H. H., and Spencer, P. S. Central and peripheral nervous system degeneration produced by pure *n*-hexane: an experimental study. Brain 99: 183 (1976).
7. Cavanagh, J. B. Peripheral neuropathy caused by chemical agents. CRC Crit. Rev. Toxicol. 2: 365 (1973).
8. Spencer, P. S., and Schaumburg, H. H. Central and peripheral distal axonopathy. The pathology of dying-back polyneuropathies. Prog. Neuropath. 3: 253 (1976).
9. Schaumburg, H. H., and Spencer, P. S. Environmental hydrocarbons produce degeneration in cat hypothalamus and optic tract. Science, 199: 199 (1978).
10. American Conference of Governmental Industrial Hygienists. Documentation of Threshold Limit Values for Substances in Workroom Air. 3rd Ed. A.C.G.H.I., 1971, p. 126.
11. Aldridge, W. N., Barnes, J. M., and Johnson, M. K. Studies on delayed neurotoxicity. Bull. WHO 44: 259, 1971.
12. Schaumburg, H. H., Wiśniewski, H., and Spencer, P. S. Ultrastructural studies of the dying-back process. I. Peripheral nerve terminal and axon degeneration in systemic acrylamide intoxication. J. Neuropathol. Exp. Neurol. 33: 260, 1974.
13. Spencer, P. S., and Schaumburg, H. H. Ultrastructural studies of the dying-back process. III. The evolution of experimental peripheral giant axonal disease. J. Neuropath. Exptl. Neurol. 36: 276 (1977).
14. Spencer, P. S., and Schaumburg, H. H. Ultrastructural studies of the dying-back process. IV. Differential vulnerability of selected PNS and CNS fibers in experimental central-peripheral distal axonopathies. J. Neuropath. Exptl. Neurol. 36: 300 (1977).
15. Weller, R. O., and Cervós-Navarro, J. Pathology of Peripheral Nerves, Butterworths, London, 1977.
16. Fullerton, P. M., and Gilliatt, R. W. Pressure neuropathy in the hind foot of the guinea-pig. J. Neurol. Neurosurg. Psychiat. 30: 18 (1967).
17. Prineas, J., and Spencer, P. S. Pathology of the nerve cell body in disorders of the peripheral nervous system. In: Peripheral Neuropathy, Vol. I., P. J. Dyck, P. K. Thomas, and E. H. Lambert, Eds., Saunders, Philadelphia, 1975, p. 253.
18. Cavanagh, J. B. The significance of the "dying-back" process in experimental and human neurological disease. Int. Rev. Exptl. Pathol. 3: 219 (1964).