*Environmental Health Perspectives*
*Vol. 26, pp. 107–116, 1978*

# Vascular Permeability and Neurotoxicity

## by Jean M. Jacobs*

**Neurotoxic substances affect the nervous system in a selective manner. One possible basis for this selectivity is blood vessel permeability. In general, the central nervous system and the peripheral nerve trunks have impermeable blood vessels, but in certain parts the capillaries are "leaky," allowing the passage of a plasma filtrate. Intravenously injected protein tracers rapidly reach nerve cells in these regions, with the implication that these nerve cells are also readily accessible to circulating neurotoxic substances.**

**Some examples of neurotoxicity in the central nervous system show a selectivity that could be due to capillary permeability. In experimental methylmercury poisoning, cranial nerve V and sensory dorsal root ganglia, which lie in regions of vascular permeability, are particularly susceptible. A number of drug and chemically induced neuropathies are predominantly sensory, and may be due, directly or indirectly, to the accessibility of neurotoxic substances to sensory neurons.**

**Examination of areas of potential vulnerability to circulating toxic substances may be of value in the experimental testing of substances for neurotoxicity, where pharmacological tests may be negative and clinical symptoms difficult to assess.**

Neurotoxic substances characteristically produce effects that are selective to particular parts of the nervous system, resulting in identifiable patterns of neuropathological changes.

This selectivity is often difficult to explain and many factors may be involved. A better understanding of these factors, and the ability to recognize those components of the nervous system which may be particularly vulnerable, could be useful in the assessment of potential neurotoxicity.

One purpose of this paper is to suggest how vascular permeability might play a role in determining this selectivity; other factors that may account for the vulnerability of particular parts of the nervous system are also discussed.

## Nerve Cell Organization

All nerve cells have a similar basic organization; a cell body or perikaryon and one or more processes of variable length, the longest extending for perhaps a metre or more. Most of the synthetic activity of nerve cells takes place in the perikaryon, and many substances essential for the maintenance of the processes or axons must be transported along their length. Some nerve cells such as the lumbar sensory ganglion cells, giving off a peripheral process extending down the hind limb, and a central fiber running the length of the spinal cord, must support a very large volume of axoplasm; indeed, it has been calculated that such cells must synthesize several times their own volume of perikaryal cytoplasm every 24 hr.

The axon, therefore, is very dependent upon its parent cell body. If an axon is cut or crushed, that part no longer in continuity with the perikaryon will degenerate. Axonal degeneration may follow, not only from loss of physical continuity with its cell body, but also as a consequence of toxic damage to the perikaryon or to transport mechanisms along the axon, or, possibly a direct effect of the toxin upon the axon. A result of this metabolic dependence of the axon upon the nerve cell body is that structural parameters of nerve cells such as the length and diameter of their axons can be important factors in determining patterns of nervous system damage. This is exemplified in the distal type of nerve fiber degeneration produced in a number of toxic neuropathies, which tends to occur in the largest and longest nerve fibers, and which has been recently reviewed by Spencer and Schaumburg (*1*).

* Departments of Applied Neurobiology and Neuropathology, Institute of Neurology, 8/11 Queen Square, London WC1N 3AR, England.

# Blood-Brain and Blood-Nerve Barriers

## Morphology

Capillaries in brain and somatic and autonomic peripheral nerves differ from those in other tissues. Their component endothelial cells are closely connected by tight junctions; also, there is little evidence of any significant vesicular transport across these cells. Vascular endothelial cells in nonnervous tissues contain an actomyosinlike protein which responds to released histamine, causing cellular contraction and separation one from another. Cerebral endothelial cells do not appear to have this contractile protein, and do not respond to histamine in this way. These features, which restrict the movement of substances between blood and brain or nerve, form the morphological basis of the blood-brain and blood-nerve barriers. Table 1 shows some characteristics of nervous system capillaries compared with those in other tissues (*2*).

The term "barrier" is a misleading one in this context because there is clearly movement of some substances from the blood into the brain. Rapoport (*2*) has suggested that cerebral and nerve capillaries act more as a "regulatory interface."

## Factors Affecting the Passage of Substances at Blood-Brain and Blood-Nerve Barriers

The narrow cleft that separates the endothelial cells at tight junctions imposes physical limits to the intercellular passage of molecules, limits which are further modified by the presence of negatively charged material within the gap. The restriction of protein molecule exchange at the blood-brain barrier is recognized as an important protective mechanism. There is restricted transendothelial passage of ions and lipid-insoluble nonelectrolytes, but specific mechanisms exist for the rapid transfer of certain aminoacids and monosaccharides important in brain metabolism. Of practical significance is the fact that potentially useful drugs may not enter the brain because they are either too ionized or are not lipid-soluble.

## Regions of the Brain Lacking a Blood Barrier

The nervous system in this way may be protected to some extent from circulating toxic substances. Certain regions, however, have no blood-brain barrier; their capillaries have slits or fenestrations allowing rapid exchange of a plasma filtrate through these extremely attenuated regions of the endothelial cell. This feature carries with it the implication that toxic substances, too, may pass readily between blood and nervous tissue.

***Central Nervous System.*** Certain small areas of the brain contain cells which produce hormones or act as hormonal or chemoreceptors, functions requiring a close association with blood. Such areas include the circumventricular organs such as the median eminence, neurohypophysis and subfornical organ, and the area postrema. Using methods involving the intravenous injection of tracers, in particular a hemeprotein, horseradish peroxidase, (HRP) the sites and extent of vascular permeability can be observed by light and electron microscopy (*4*). This technique can also demonstrate that the tracer, having passed through perme-

**Table 1. Classification of capillaries according to type of endothelium.**[a]

| Type of *endothelium* | Basement *membrane* | *Endothelial connections* | Contractile *protein* | Vesicular *transport* | *Tissue distribution* |
|---|---|---|---|---|---|
| Continuous | Continuous | Continuous belts tight junctions with cell separation of 12 Å | Absent | Rare | Brain, endoneurium (peripheral nerve) |
| Continuous | Continuous | Spot junctions and clefts between cells 100 Å wide | Present | Very common | Skeletal muscle, heart, dermis |
| Fenestrated | Discontinuous | Fenestrae in cells, 200–1000 Å wide | ? | Minimal | Endocrine glands, renal glomerulus, dorsal root and autonomic ganglia, special regions of brain, e.g. area postrema, circumventricular organs |
| Discontinuous (sinusoidal) | Discontinuous or absent | Intercellular gaps 0.1 to 1 μm wide | Present | | Liver, bone marrow, spleen |

[a] Adapted from Majno (*3*), Karnovsky (*4, 5*) and Rapoport (*2*).

able blood vessels, may then be taken up at nerve endings and transported in a retrograde direction back to the parent cell body.

Although there are few relevant examples, it is tempting to speculate that some selective toxic effects in the central nervous system (CNS) may be explained by such mechanism. Monosodium glutamate produces damage experimentally to parts of the central nervous system, which closely correspond to sites lacking a blood-brain barrier (*6*), and a number of its analogs also produce neuronal degeneration of the arcuate nucleus of the hypothalamus (Fig. 1) (*7*). Tracer experiments (*8*) have shown that the arcuate nucleus is in a region of vascular permeability, and also that the axons of nerve cells in this nucleus enter a region of permeable capillaries, possibly the median eminence. Tracer appears to be taken up by these axons and transported back to nerve cell bodies in the arcuate nucleus (Fig. 1). Other studies (*9*) have shown that glutamate can be taken up and transported along an axon in a retrograde direction. A similar route could be taken by glutamate that has leaked across capillaries of the median eminence. Aspartame, a synthetic sweetener, was found, when fed to mice, to produce lesions in the arcuate nucleus similar to

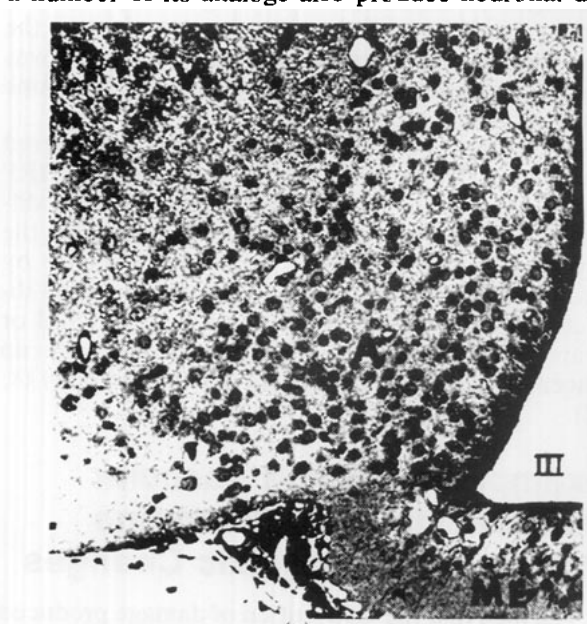


(*a*)

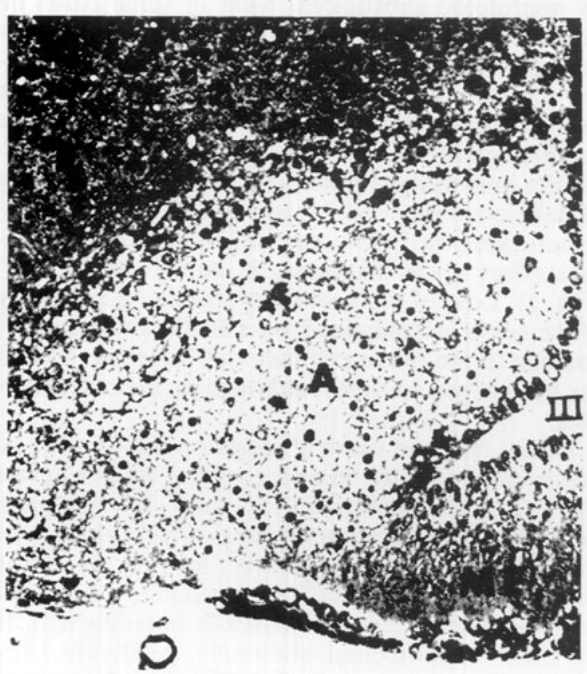


(*b*)

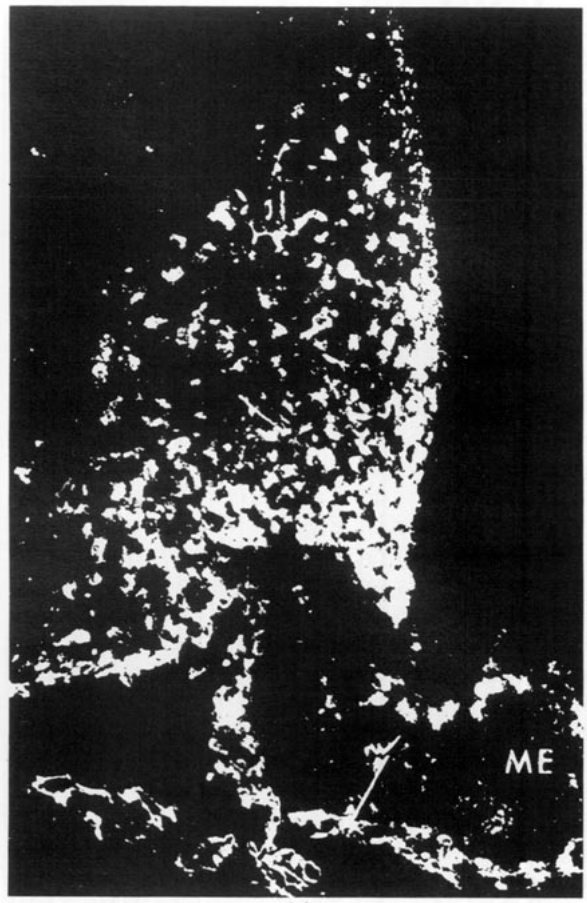


FIGURE 1. Sections through the hypothalamic region of mouse brain showing the arcuate nucleus (A), median eminence (ME) and third ventricle (III): (*a*) Normal 10-day-old mouse, × 280; (*b*) 10-day-old mouse, 6 hr after an 18 mmole/kg SC dose of monosodium glutamate; neurons in the arcuate nucleus have swollen cytoplasm and pyknotic nuclei, × 280; (*c*) dark-field micrograph showing peroxidase-labeled cells in the arcuate nucleus and in the median eminence in a mouse given HRP 24 hr before killing. Figs. 1*a* and 1*b* reproduced by courtesy of J. W. Olney; Fig. 1*c* reproduced by courtesy of M. W. Brightman.

those produced by monosodium glutamate (*10*). Aspartame is a dipeptide which is broken down in the gut into phenylalanine and aspartate, the latter aminoacid probably being the toxic agent. A recent report (*11*) has also shown that L-alanosine, a new antileukemic agent, also produces acute necrosis of the arcuate nucleus, as well as of the subfornical organ and the area postrema, which are both areas of vascular permeability.

***Peripheral Nervous System.*** Impermeable capillaries are present within somatic and autonomic peripheral nerve trunks, but tracer studies have shown (*12–17*) that blood vessels in dorsal root ganglia are permeable. Figure 2 shows a 1 μm section of a dorsal root ganglion in a rat intravenously injected 2 min before killing with the tracer HRP. This is seen as a dark reaction product lying between ganglion cells. Electron microscope studies have shown (*17*) that, within 5 min of injection of HRP, the tracer is found lying between the satellite cells and adjacent to ganglion cells and their axons (Fig. 3). Some ganglion capillaries were found to be fenestrated (Fig. 4). Even in an animal not injected with tracer it is possible to see proteinaceous material lying between the ganglion cells.

A recent study has also shown tracer leakage in autonomic sympathetic ganglia, fenestrated blood vessels being more numerous here than in dorsal root ganglia. Although it has been stated (*18*) that the perikaryal ganglion cell surface does not come into direct contact with the extracellular space proper but only with the inner surface of the satellite cells, tracer studies have demonstrated that materials in the extracellular space can penetrate to the ganglion cell surface (*19*).

***Other Parts of the Nervous System Exposed to a Plasma Filtrate.*** The myenteric plexus is an extensive network of groups of nerve cells and connecting nerve cells processes lying between muscle layers along the whole length of the gastro-intestinal tract. No blood vessels are present in the myenteric plexus, but HRP penetrates freely into the plexus, having leaked out of blood vessels in the adjacent muscle layers (*19*). This represents a considerable volume of nervous tissue potentially exposed to a plasma filtrate.

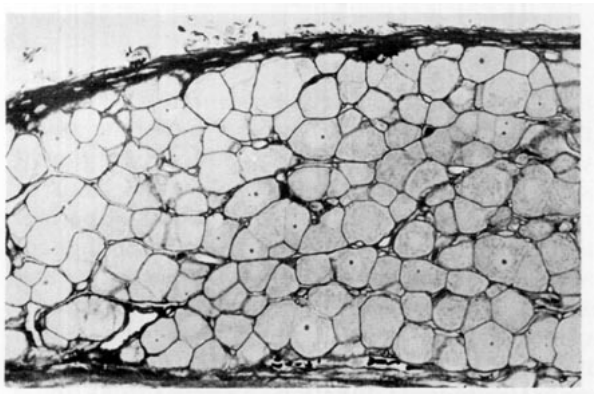

FIGURE 2. Section (1 μm) of a rat dorsal root ganglion 2 min after intravenous HRP. Peroxidase appears as black reaction product lying in the extracellular spaces, outlining the ganglion cells. × 1235.

Some leakage of an intravenous tracer was found in the optic nerve due to imperfections in the meninges or membranes covering the optic nerve where they fuse with the sclera or outer coat of the eye (*20*); tracer diffusion into the optic nerve was confirmed more recently in an electron microscope study (*21*).

The axonal endings of a muscle nerve are covered only by basement membrane. Tracers such as HRP can pass readily across muscle capillaries and diffuse into the gap between axon and muscle, the myoneural junction. There it may be taken up by axonal endings and transported in a retrograde direction back to the cell body in the spinal cord or brain (*8, 22*). Sensory endings can also take up tracer for transport back to the parent cell body (*8, 22*).

## Examples in Which Vascular Permeability May Determine Patterns of Neurotoxic Changes

The idea that the distribution of damage produced by neurotoxic substances might in some cases be influenced by blood vessel permeability arose during experimental studies of methylmercury poisoning (*23–25*). The effects of methylmercury upon nervous tissue are associated with a disturbance to protein synthesis. *In vitro* (*26*) and *in vivo* (*27*) studies had shown impairment of the incorporation of labeled amino acids into protein, and ultrastructurally, methylmercury appeared to have a direct effect upon ribosomes in nerve cells (*23–25*) (Fig. 5). Loss of the protein synthesizing capability of the nerve cell may lead to its death; alternatively, damage to the nerve cell may not be lethal, so that the perikaryon survives, although its axon degenerates.

Dorsal root and nerve V ganglia were found to be particularly affected in experimental studies in rats (*23, 24, 28–30*), rabbits (*25, 31*), pigs (*32*), and monkeys (*28*). Degeneration of nerve cells in autonomic ganglia and their associated nerves (Fig. 6) and in the myenteric plexus has been seen in rats poisoned with methylmercury (Jacobs 1977, unpublished). In all these experimental situations, relatively large doses were given, producing high blood levels of

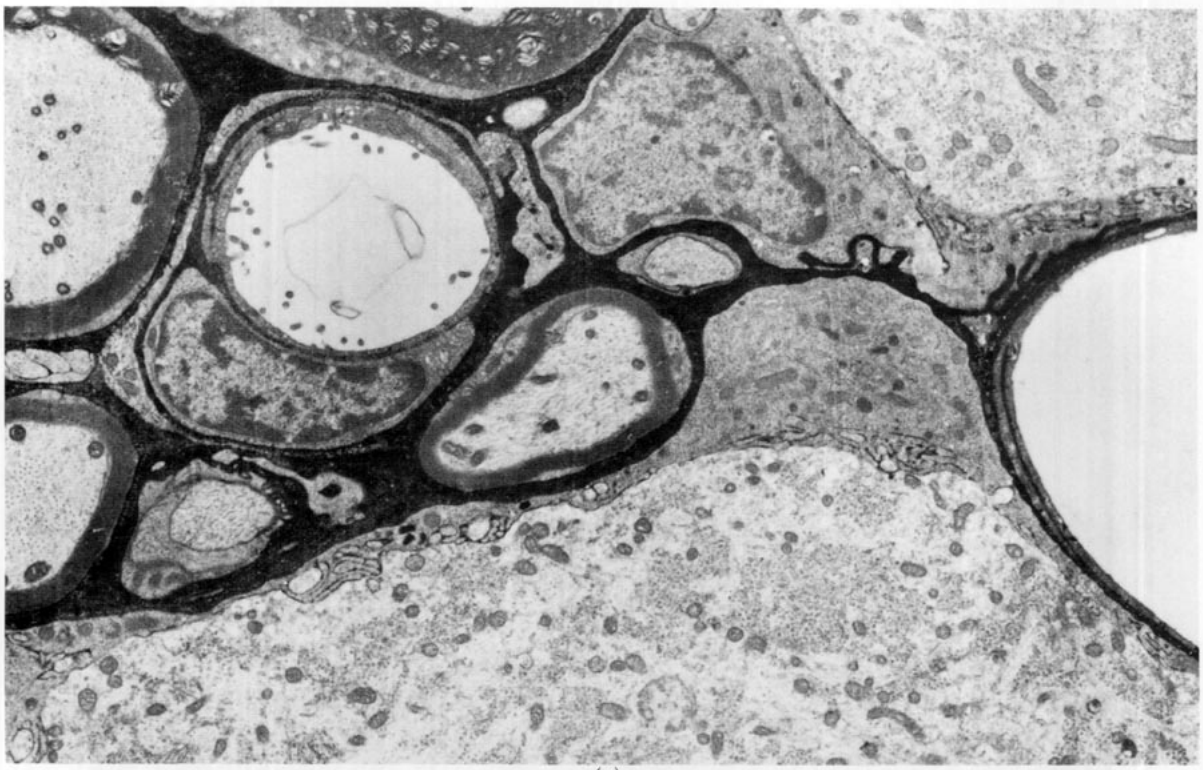

(*a*)

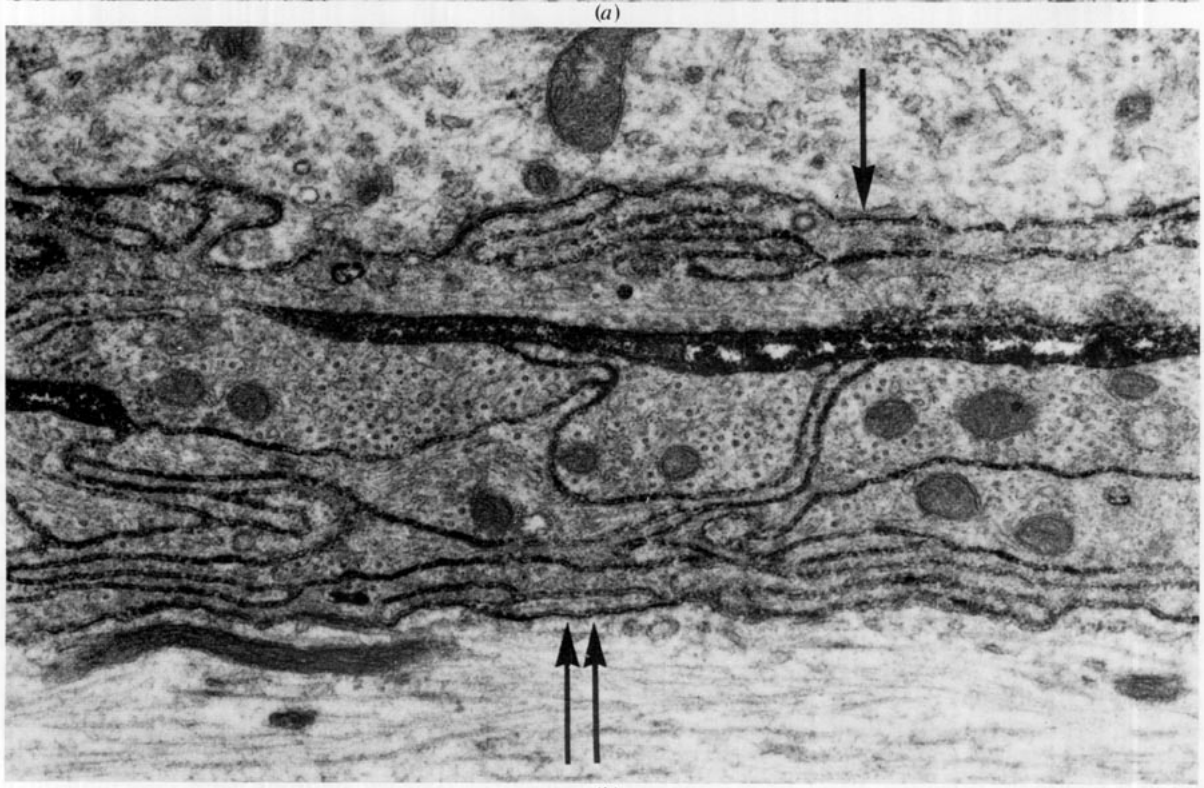

(*b*)

FIGURE 3. Lumbar ganglion from a rat 5 min after intravenous HRP, showing peroxidase in the extracellular space: (*a*) low power view, × 6750; (*b*) higher power showing HRP between the satellite cell processes and in the perineuronal space (single arrow) and periaxonal space (double arrow), × 26,000.

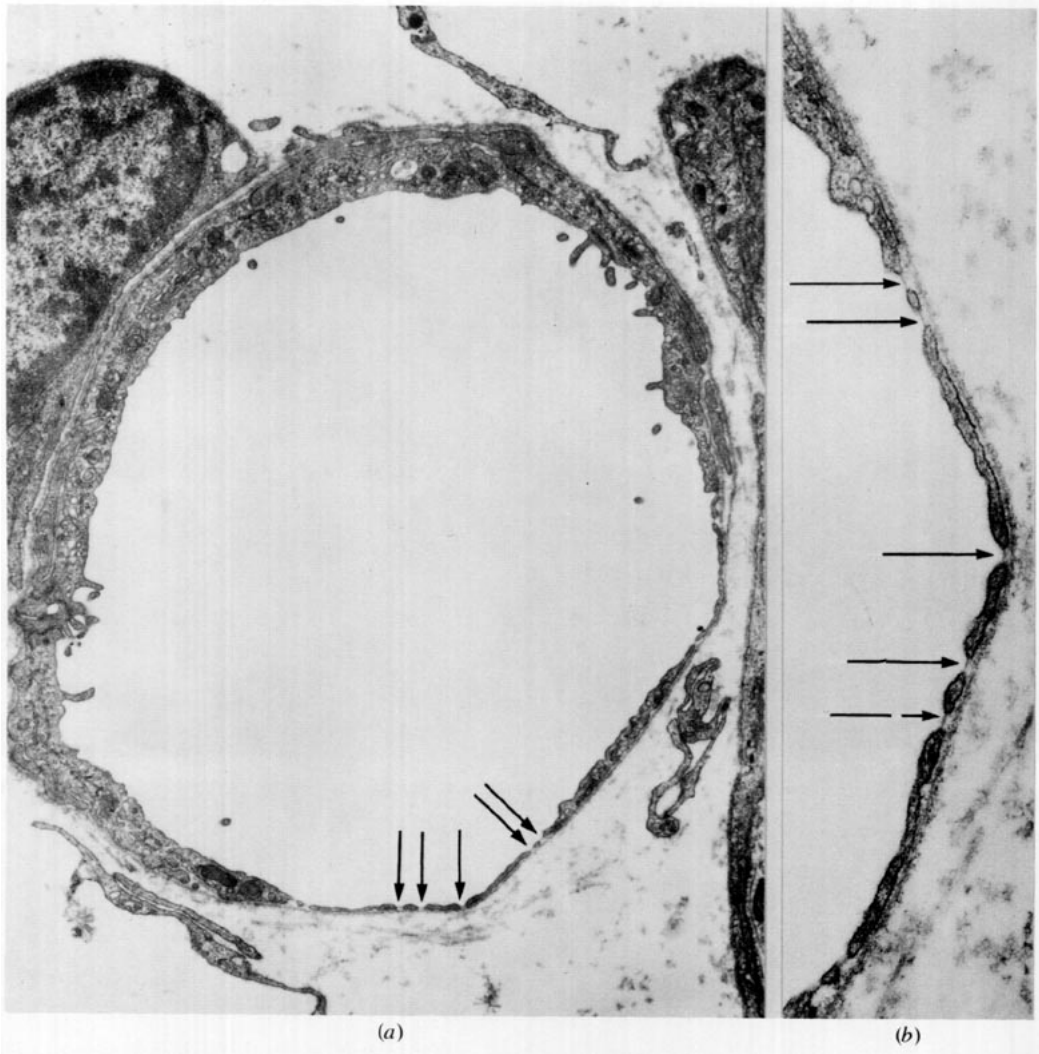


FIGURE 4. Blood vessel from lumbar ganglion of a rat, showing numerous fenestrations (arrows): (*a*) × 10,000; (*b*) × 28,000.

mercury which presumably could rapidly reach the ganglion cells because of the permeability of the ganglionic blood vessels. In studies of a more chronic type on monkeys (*33*, *34*), lower blood levels of methylmercury are produced, and ganglion cells are less dramatically affected, a situation probably paralleling that in humans. Nevertheless, in Minamata disease, there is some evidence of damage to peripheral sensory and autonomic nerves (*35*, *36*). Dorsal root ganglia were affected in a child accidentally given intravenous methylmercury (Takeuchi, 1976 unpublished).

Methylmercury is highly lipid-soluble and undoubtedly can cross the blood-brain barrier, but its rapid and markedly selective effect upon ganglion cells may be a reflection of the ease with which it is able to reach these cells.

A number of other drugs, industrial agents, and metals appear to produce a predominantly, or purely sensory neuropathy. In almost every case, sensory symptoms are the first to appear, even if the neuropathy progresses to involve motor nerves.

Chloramphenicol (*37*), chlorobiphenyl (*38*), chlorodinitrobenzene (*39*), dinitrobenzene (*39*), clioquinol (*37*, *40*), disulfiram (*37*), nitrofurantoin (*37*), and thalidomide (*37*, *40*) produce a predominantly sensory neuropathy in man. Acute arsenic intoxication in humans results in a sensory neuropathy (*41*); thallium in the cat produces a sensory neuropathy, but with sparing of muscle sensory nerve fibers (*42*). A recent study (*43*) has described neuronal abnormalities in lumbar and trigeminal sensory neurons with concomitant degeneration of the associated peripheral nerves, dorsal roots and dorsal columns of the spinal cord, in rats given a single intravenous dose of adriamycin,

an anthracycline antibiotic which inhibits cellular DNA and RNA synthesis.

In view of the observation that there are deficiencies in the barriers to vascular permeability in the optic nerve, it is interesting to note that some neurotoxic substances, e.g., clioquinol, chloramphenicol, chlorodinitrobenzene, and dinitrobenzene affect the optic nerve as well as the sensory ganglion cells. There is a paucity of information regarding the nature of these optic nerve lesions, so

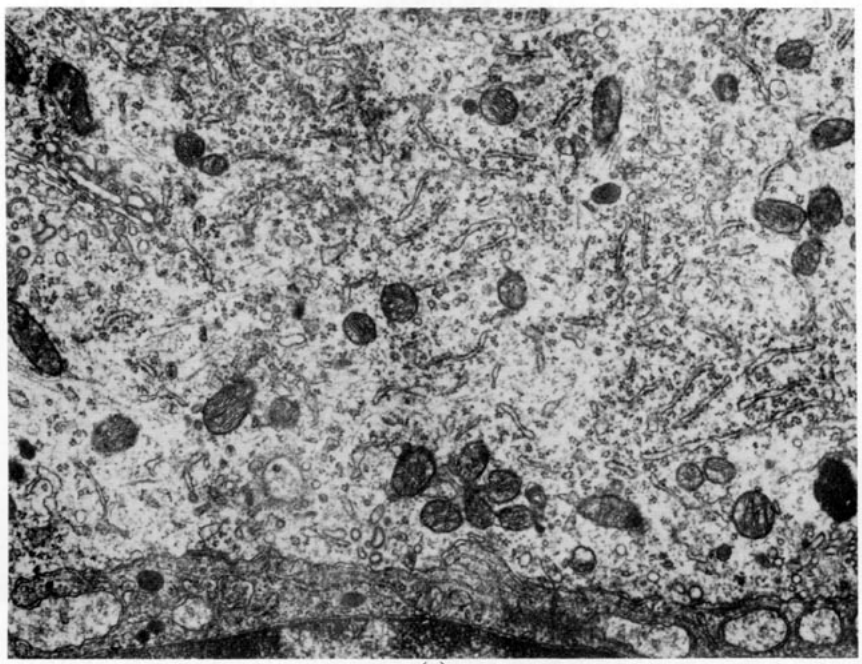

(*a*)

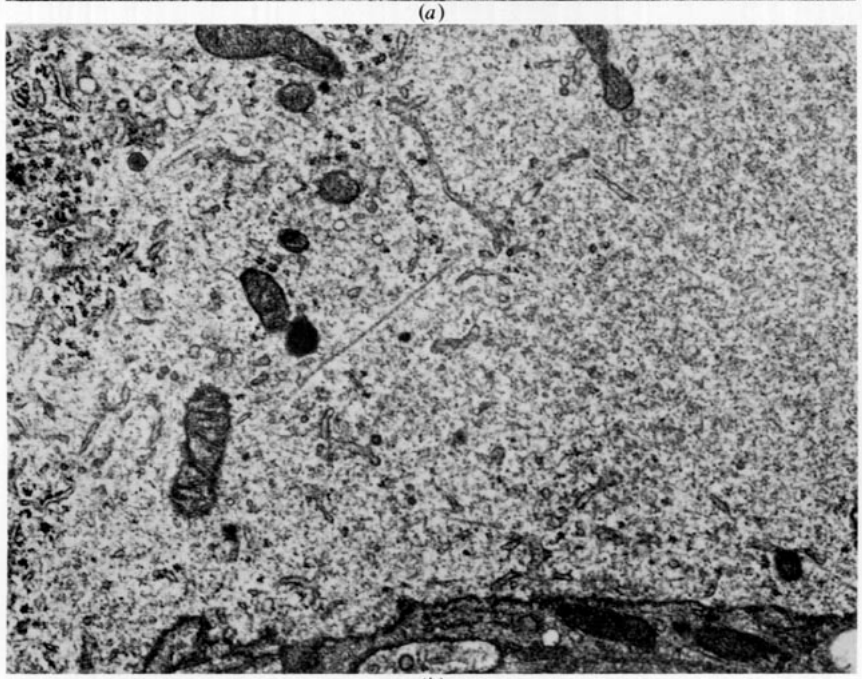

(*b*)

FIGURE 5. Part of a ganglion cell (*a*) from the cervical ganglion of a control animal, showing the normal arrangement of organelles, × 17,500; (*b*) from the cervical ganglion of a rabbit given 2 doses of 7.5 mg/kg of methylmercury acetate, by mouth. There is loss of rough endoplasmic reticulum (RER); a few strands of degranulated RER are seen, but otherwise only granular material remains, and an occasional mitochondrion which appears normal; × 17,500.

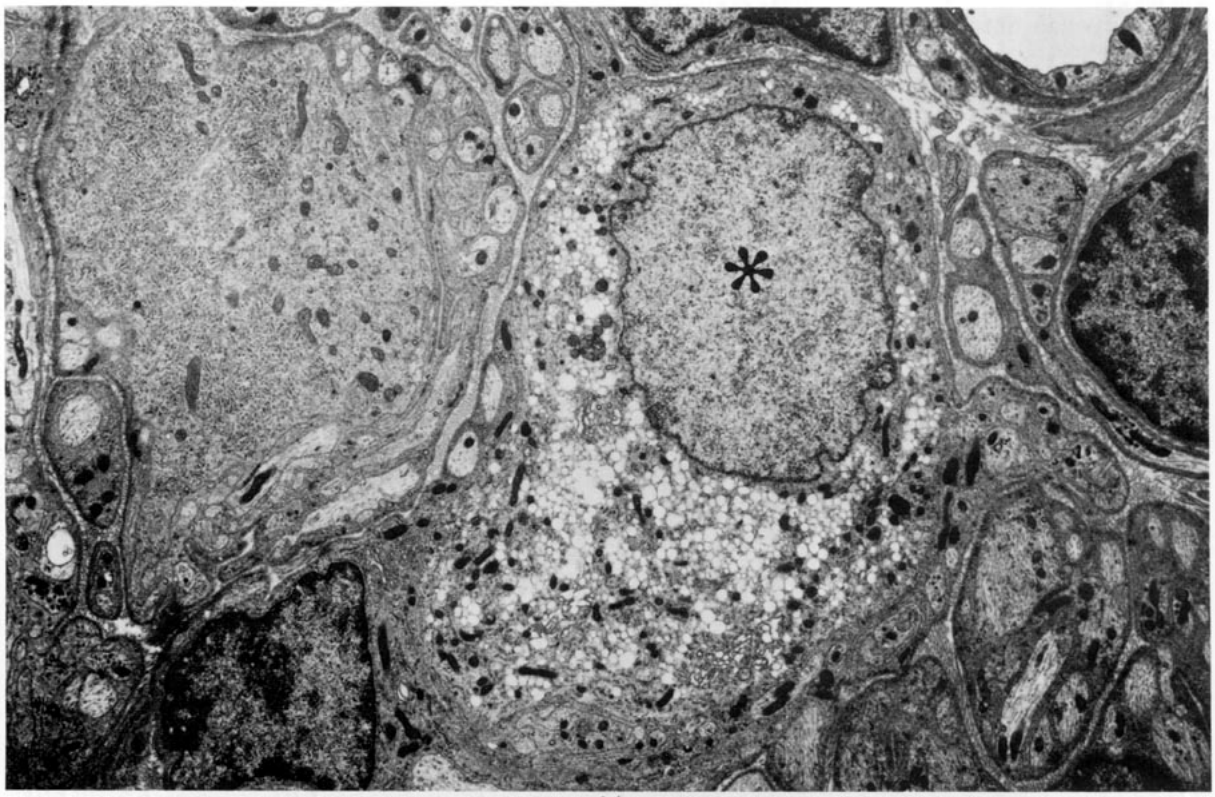

(*a*)

(*b*)

FIGURE 6. Celiac ganglion from a rat given 8 doses of 7.5 mg/kg methylmercury acetate by mouth: (*a*) one ganglion cell is degenerating (asterisk) and contains many small vacuoles, × 6500; (*b*) numerous degenerating unmyelinated nerve fibers are seen, × 13,000.

that a possible relationship to vascular leakage is not clear. Autonomic ganglia and the myenteric plexus are rarely, if ever, examined in studies of neurotoxicity. Nerve damage due to the entry of toxic substances from sensory and muscle nerve endings has not been widely investigated, although the importance of this route in viral disease is recognized (*22*). The unique finding, in thallium intoxicated rats, of sensory denervation in all regions other than muscle suggested to Cavanagh (*42*) that thallium may enter from sensory endings except those in muscle, where a large pool of $K^+$ ions perhaps restricts its entry.

Exposure of nerve cells to neurotoxic substances may not produce morphological changes in those cells, even though their metabolism may be affected; however axonal degeneration may occur. In some distal axonal degenerations, neuronal perikarya are reported as being unaffected, although good experimental evidence is often lacking and closer study may reveal changes. At later stages of intoxication, dorsal root ganglion cells may show chromatolytic changes, indicating previous damage to these cells with subsequent recovery and regeneration of the axons.

Clinical symptoms may be difficult to recognize in animals; the endocrine deficiency produced by monosodium glutamate, for example, would have to be specifically sought; sensory neuropathy may also be difficult to detect.

Neuropharmacological tests may be negative in animals with severely degenerated nerves (*44*). In most cases of human neuropathies caused by drugs, animal screening experiments had failed to show that the drugs were neurotoxic (*37*). An awareness of the accessibility of particular nerve cells or processes to circulating substances may suggest new ways of assessing neurotoxicity.

I would like to express my indebtedness to Professor J. B. Cavanagh for the help and guidance he has given me in much of the experimental work referred to in this paper.

## REFERENCES

1. Spencer, P. S., and Schaumburg, H. H. Central-peripheral distal axonopathy. The pathology of dying back polyneuropathies. Progr. Neuropath. 3: 253 (1977).
2. Rapoport, S. I. Blood-brain barrier. In: Physiology and Medicine, Raven Press, New York, 1976.
3. Majno, G. Ultrastructure of the vascular membrane. In: Handbook of Physiology. 2. Circulation, Vol. 3, W. F. Hamilton and P. Dow, Eds., American Physiological Society, Washington, D. C., 1965.
4. Karnovsky, M. J. The ultrastructural basis of capillary permeability studied with peroxidase as a tracer. J. Cell Biol. 35: 213 (1967).
5. Karnovsky, M. J. The ultrastructural basis of transcapillary exchanges. J. Gen. Physiol. 52: 645 (1968).
6. Olney, J. W., Rhee, V., and de Gubareff, T. Neurotoxic effects of glutamate on mouse area postrema. Brain Res. 120: 151 (1977).
7. Olney, J. W. Brain damage and oral intake of certain aminoacids. Adv. Exptl. Med. Biol. 69: 497 (1976).
8. Broadwell, R. D., and Brightman, M. W. Entry of peroxidase into neurons of the central and peripheral nervous system from extracerebral and cerebral blood. J. Comp. Neurol. 166: 257 (1976).
9. Kerkut, G. A., Shapira, A., and Walker, R. J. The transport of $^{14}C$-labelled material from CNS to and from muscle along a nerve trunk. Comp. Biochem. Physiol. 23: 729 (1967).
10. Olney, J. W. Another view of aspartame. In: 4th Academy Forum, National Academy of Sciences, 1975, p. 129.
11. Olney, J. W., Fuller, T., and de Gubareff, T. Alanosine—an antileukemic agent with glutamate-like neurotoxic properties. J. Neuropath. Exptl. Neurol. 36: 619 (1977).
12. Doinikow, B. Histologische und histopathologische Untersuchungen am peripheren Nervensystem mittels Vitallen Faerbung. Fol. Neurobiol. 7: 731 (1913).
13. Tschetschujeva, J. Uber die Speicherung von Trypan blau in Ganglien verschiedener Gebiete des Nervensystems. Z. Ges. Exptl. Med., 69: 208 (1929).
14. Waksman, B. H. Experimental study of diphtheritic polyneuritis in the rabbit and the guinea pig. Part 3: The blood-brain barrier in the rabbit. J. Neuropath. Exptl. Neurol., 21: 35 (1961).
15. Olsson, Y. Topographical differences in the vascular permeability of the peripheral nervous system. Acta Neuropath. 10: 26 (1968).
16. Olsson, Y. Studies on vascular permeability in peripheral nerves. IV Distribution of intravenously injected protein tracers in the peripheral nervous system. Acta Neuropath. 17: 114 (1971).
17. Jacobs, J. M., Macfarlane, R. M., and Cavanagh, J. B. Vascular leakage in the dorsal root ganglia of the rat studied with horseradish peroxidase. J. Neurol. Sci. 29: 95 (1976).
18. Gabella, G. Structure of the Autonomic Nervous System, Chapman and Hall, London, 1976.
19. Jacobs, J. M. Penetration of systemically injected horseradish peroxidase into ganglia and nerves of the autonomic nervous system. J. Neurocytol. 6: 607 (1977).
20. Grayson, M. C., and Laties, A. M. Ocular localization of sodium fluorescein; effects of administration in rabbit and monkey. Arch. Ophthal. 85: 600 (1971).
21. Tsukahara, I., and Yamashita, H. An electron microscope study on the blood optic nerve and fluid optic nerve barrier. Graefe Arch. Ophthal., 196: 239 (1975).
22. Kristensson, K., and Olsson, Y. Diffusion pathways and retrograde axonal transport of protein tracers in peripheral nerves. Progr. Neurobiol. 1: 85 (1973).
23. Herman, S. P., et al. An ultrastructural study of methylmercury-induced primary sensory neuropathy in the rat. Lab. Invest. 28: 104 (1973).
24. Jacobs, J. M., Carmichael, N., and Cavanagh, J. B. Ultrastructural changes in the dorsal root and trigeminal ganglia of rats poisoned with methylmercury Neuropath. Appl. Neurobiol. 1: 1 (1975).
25. Jacobs, J. M., Carmichael, N., and Cavanagh, J. B. Ultrastructural changes in the nervous system of rabbits poisoned with methylmercury. Toxicol. Appl. Pharmacol. 39: 249 (1977).
26. Yoshino, Y., Mozai, T., and Nakao, K. Biochemical changes in rat brain poisoned with an alkyl mercury compound, with special reference to the inhibition of protein synthesis in brain cortex slices. J. Neurochem. Biochem. 13: 1223 (1966).
27. Cavanagh, J. B., and Chen, F. C-K. Aminoacid incorporation in protein during the "silent phase" before organomer-

cury and *p*-bromophenylacetylurea neuropathy in the rat. Acta Neuropath. 19: 216 (1971).
28. Hunter, D., Bomford, R. R., and Russell, D. S. Poisoning by methylmercury compounds. Quart. J. Med. 9: 193 (1940).
29. Cavanagh, J. B., and Chen, F. C-K. The effects of methylmercury dicyandiamide on the peripheral nerves and spinal cord of rats. Acta Neuropath. 19: 208 (1971).
30. Chang, L. W., and Hartmann, H.A. Ultrastructural studies of the nervous system after mercury intoxication. 1. Pathological changes in the nerve cell bodies. Acta Neuropath. 20: 122 (1972).
31. Carmichael, N., Cavanagh, J. B., and Rodda, R. A. Some effects of methylmercury salts on the rabbit nervous system. Acta Neuropath. 32: 115 (1975).
32. Charlton, K. M. Experimental alkylmercurial poisoning in swine. Lesions in the peripheral and central nervous system. Can. J. Comp. Med. 38: 75 (1974).
33. Ikeda, Y., et al. Long-term toxicity of methylmercuric chloride in monkeys. Toxicology 1: 361 (1973).
34. Garman, R. H., Weiss, B., and Evans, H. L. Alkylmercury encephalopathy in the monkey. Acta Neuropath. 32: 61 (1975).
35. Takeuchi, T., et al. A pathological study of Minamata disease in Japan. Acta Neuropath. 2: 40 (1962).
36. Okajima, T., Mishima, I., and Tokuomi, H. Minamata disease with a long-term follow-up. Int. J. Neurol. 11: 62 (1976).
37. Le Quesne, P. M. Neuropathy due to drugs. In: Peripheral Neuropathy, P. F. Dyck, P. K. Thomas, and E. H. Lambert, Eds., Saunders, Philadelphia, 1975.
38. Hopkins, A. Toxic neuropathy due to industrial agents. In: Peripheral Neuropathy, P. F. Dyck, P. K. Thomas, and E. H. Lambert, Eds., Saunders, Philadelphia, 1975.
39. Grant, M. W. Toxicology of the Eye, 2nd ed., Charles C Thomas, Springfield, Ill., 1974.
40. Cavanagh, J. B. Peripheral neuropathy caused by chemical agents. CRC Crit. Rev. Toxicol. 2: 365 (1973).
41. Le Quesne, P. M., and McLeod, J. G. Peripheral neuropathy following a single exposure to arsenic. J. Neurol. Sci. 32: 437 (1977).
42. Kennedy, P., and Cavanagh, J. B. Sensory neuropathy produced in the cat with thallous acetate. Acta Neuropath. 39: 81 (1977).
43. Cho E-S., Schaumburg, H. H., and Spencer, P. S. Adriamysin produces ganglio-radiculopathy in rats. J. Neuropath. Exptl. Neurol. 36: 597 (1977).
44. Alder, S., and Zbiden, G. Use of pharmacological screening tests in subacute neurotoxicity studies of isoniazid, pyridoxine HCl and hexachlorophene. Agents Actions 3: 233 (1973).