Environmental Health Perspectives
Vol. 26, pp. 181–191, 1978

Cardiac Lesions Induced by Chemicals

by T. Balazs* and V. J. Ferrans†

Chemically induced cardiomyopathies are frequently the consequences of a cardiac metabolic imbalance brought about by exaggerated functional affects. The infarctlike lesions induced by adrenergic beta-receptor stimulants and the vasodilating antihypertensives serve as examples of this phenomenon. Direct cardiotoxic mechanisms not related to cardiovascular functional effects are responsible for another class of toxic cardiomyopathy. An example of this is the cardiomyopathy produced by the anthracycline antineoplastic agents. The pathogenesis, morphological changes and toxicologic features of these cardiomyopathies are described with particular reference to their detection in preclinical toxicity studies.

Cardiotoxic chemicals have been identified in the environment of industrial plants and among drugs, pesticides, and even food additives. The character of their effects varies from subtle functional alterations to severe structural changes leading to heart failure. Cardiac structural changes induced by chemicals usually involve the myocardium itself. The role of exogenous nonlipid chemicals in the etiology of coronary heart disease is not known; however, at least one chemical, carbon disulfide, is considered, on the basis of experimental animal and epidemiological studies, to enhance coronary atherosclerosis (*1*).

At the beginning of this century, epinephrine was shown to cause myocardial lesions. It was later postulated that catecholamines play a role in the etiology of noncoronarogenic ischemic heart disease (*2*). Those catecholamine analogs which are adrenergic beta-receptor agonists cause focal myocardial necroses due to hemodynamic changes brought about by their pharmacological effects. Such a mechanism is responsible for the cardiotoxicity of a number of unrelated chemicals. A true autonomous cardiotoxic effect is one which is independent of the cardiovascular pharmacological action. Among agents belonging to this category, the anthracycline antineoplastic drugs are the most thoroughly and most recently studied. The cardiotoxic propensity of some compounds is enhanced by predisposing conditions, e.g., nutritional factors. This enhancement has been demonstrated in studies with cobalt in rats, nutritional status most likely played a role in the acute cardiomyopathy that developed in beer drinkers consuming products which contained cobalt salts added as a foam stabilizer (*3*). Cardiac hypersensitivity reactions to a few chemicals also have been described, usually as part of allergic reactions involving several organs.

Chemicals can induce persistent molecular changes with functional consequences without leading to morphologically detectable alterations. For example, after cessation of prolonged treatment with propranolol, an adrenergic beta-receptor blocker, supersensitivity develops to adrenergic agonists (*4*, and Balazs et al., unpublished data). This supersensitivity is attributable to an adaptive increase in the population of beta receptors. The increase develops during the blockade (*5*) but is detectable only afterwards. Such an event serves as an example of the development of a solely biochemical lesion that does not lead to a structural alteration.

Cardiomyopathies induced by chemicals (particularly by steroids) have been the subject of heuristic research by Selye (*6*). In addition to his classical monographs, other reviews have enriched the literature on this subject (*7, 8*). In this communication we present a synopsis of two distinct types of cardiomyopathy to exemplify the diversity of pathogenetic, morphologic, and toxicologic characteristics of chemically induced cardiac lesions. These examples also serve as prototypes of the problems encountered in preclinical or premarketing toxicology studies with new products. In these studies, examinations using techniques of

* Division of Drug Biology, Bureau of Drugs, Food and Drug Administration, Washington, D. C. 20204.
† Pathology Branch, National Heart, Lung, and Blood Institute, National Institutes of Health, Bethesda, Maryland 20014.

clinical medicine, clinical pathology, and postmortem pathology are carried out to detect the effects of drugs on various organ systems, including the heart. The limitations of these tests or, rather, the inadequacy of a standard test protocol for the detection of specific cardiotoxic effects, will be evident.

Cardiac Lesions Due to Exaggerated Cardiovascular Effects

Adrenergic beta-receptor agonists (isoproterenol, metaproterenol, salbutamol, etc.) and the vasodilating antihypertensive agents (hydralazine, diazoxide, minoxidil, etc.) produce myocardial necroses in experimental animals (*9–11*). These lesions are consequences of the pharmacological effects of these drugs. The adrenergic drugs cause these effects by their direct action on the cardiac and vascular beta-receptors, whereas the antihypertensives induce vasodilatation that results in a reflex tachycardia via the adrenergic neurotransmitter. The adrenergic stimulation causes an augmented transmembrane calcium influx, which results in an increase in the rate and force of contraction (*12*). The energy and oxygen requirements suddenly increase. The supply of energy from high-energy phosphate bonds (adenosine triphosphate and creatine phosphate) is maintained as long as aerobic glycolysis and mitochondrial oxidative phosphorylation are unimpaired. If the oxygen supply does not keep up with the demand, the high energy stores become depleted. They are not well maintained by anaerobic glycolysis. Both the adrenergic and antihypertensive agents cause hypotension, which may result in hypoxemia. Then, because of the tachycardia-induced decrease in the duration of diastole (the cardiac perfusion period), hypoxia develops in the least perfused area of the heart, even if the coronary circulation is anatomically normal. If the adrenergic stimulus and the calcium influx continue, calcium accumulates in the mitochondria and further impairs their function. Hence the repletion of the energy stores will be handicapped.

The least well perfused area of the heart is the subendocardial zone of the left ventricle (particularly the papillary muscles), since the coronary pressure decreases and the tissue pressure increases through the thick left ventricular wall; thus, the perfusion pressure is the lowest in this zone. The papillary muscles are further handicapped because of the large amount of mechanical work that they carry out. For these reasons, the lesions induced by adrenergic and antihypertensive agents are most frequently located in the papillary muscles and the subendocardial area of the left ventricle. The extent of the lesions is dose-related, and with sublethal doses the right ventricle and occasionally the atria are also involved.

The lesion produced by these drugs is best elicited by dosing on two consecutive days. In dogs killed 24 hr thereafter, well demarcated grayish areas, measuring 0.2 to 0.5 cm in diameter and 0.2 to 0.4 mm in depth, are seen on the papillary muscles; similar or larger areas appear on the subendocardium of the left ventricle (Fig. 1). Microscopically, the fibers show increased eosinophilia, hypercontraction bands, granular swelling of the sarcoplasm, and loss of nuclei. Inflammatory reaction is mild. In dogs killed a few days later, focal areas of myocardial cellular loss are the sites of fibrocytic proliferation and histiocytic invasion.

The sequential development of the lesion has been followed in rats given a single dose of isoproterenol (*13–15*). The earliest changes are seen in the myofibrils. Irregular contraction bands with rupture of the myofibrils develop within a few minutes. Mitochondrial changes, consisting of swelling and the appearance of electron-dense deposits pre-

FIGURE 1. Subendocardial necroses in the left ventricle, most prominent in the papillary muscles, induced in dog by the administration of salbutamol, an adrenergic beta-receptor agonist.

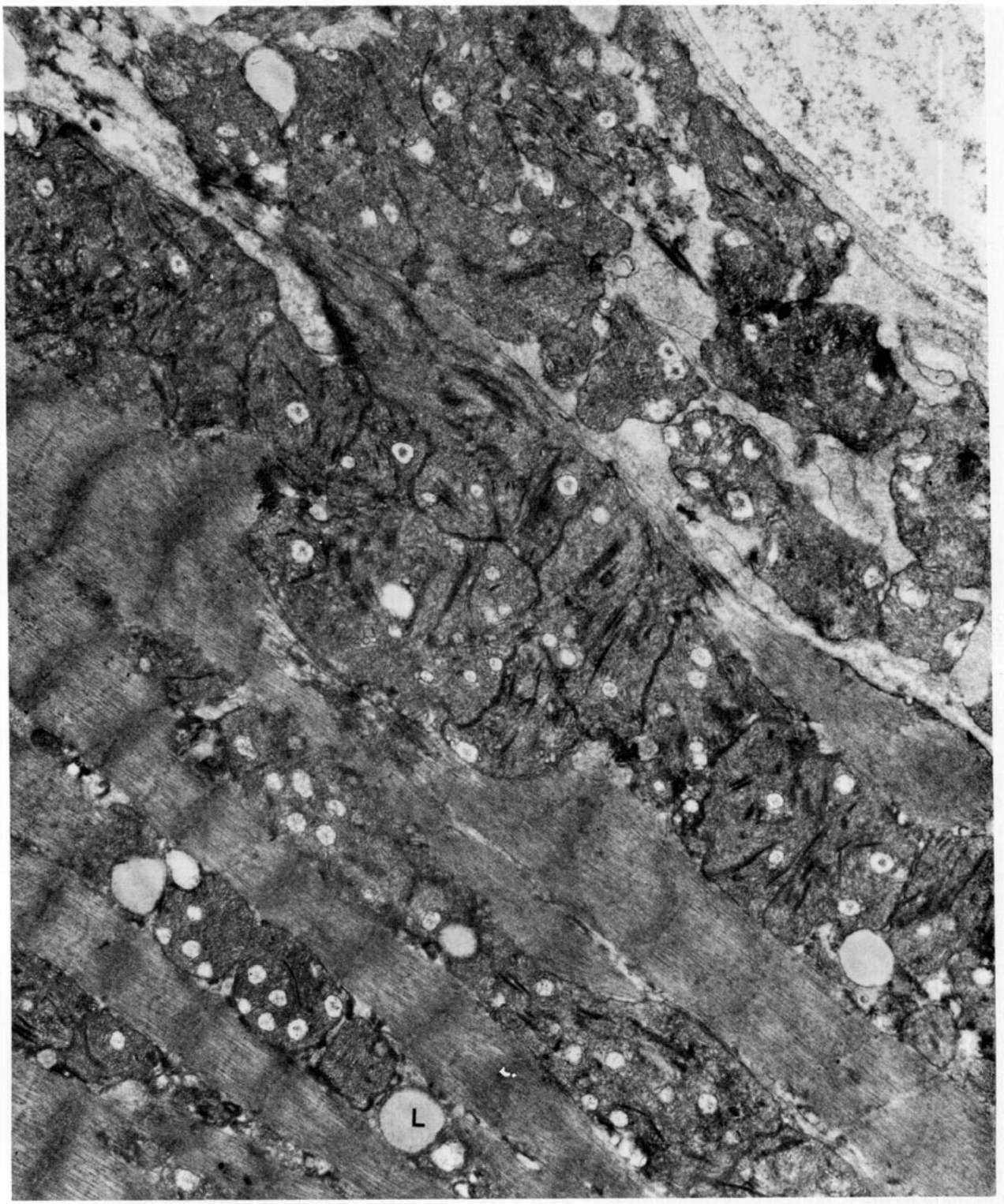

FIGURE 2. Electron micrograph (courtesy of Dr. George Rona, Montreal) of left ventricular muscle cell from rat sacrificed 3 hr after administration of isoproterenol. The myofibrils are hypercontracted. Lipid droplets (L) are present, and the mitochondria contain numerous inclusions characterized by a dense center and a lucent periphery. These inclusions are thought to represent calcium deposits. ×16,500.

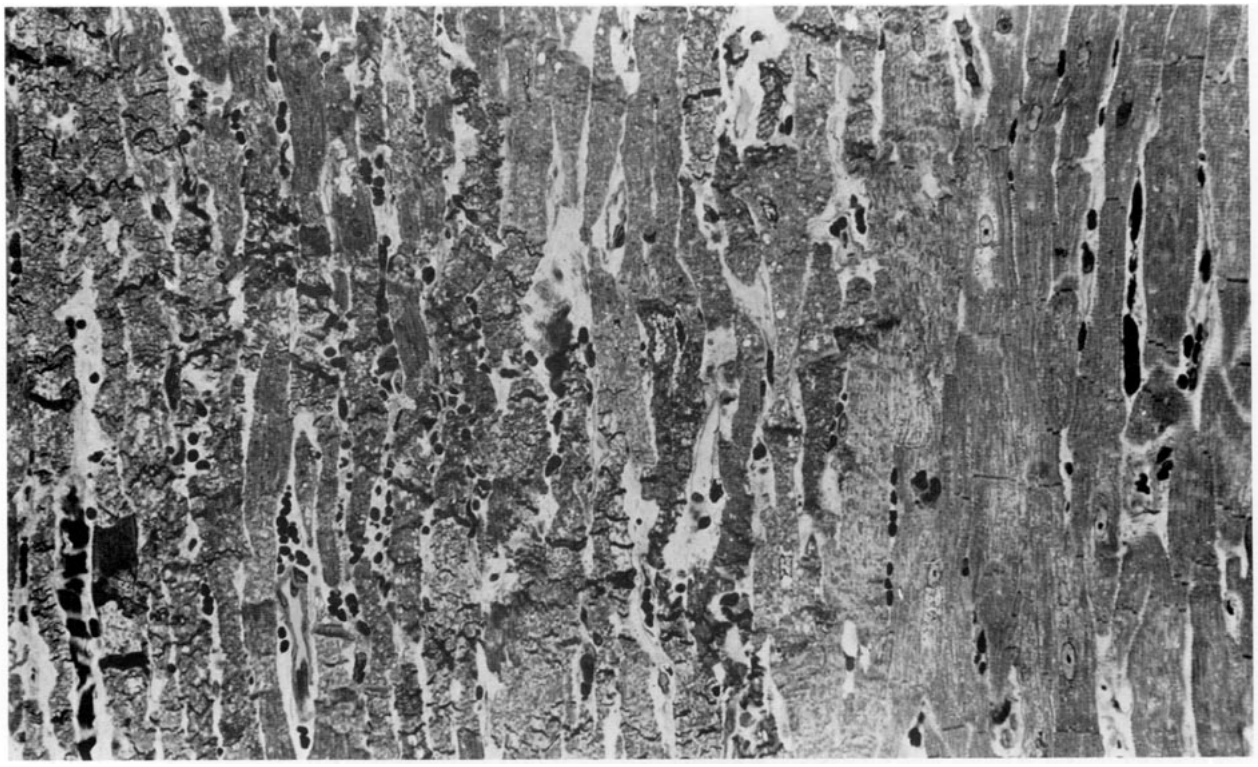

FIGURE 3. Myocardial necrosis with hypercontraction bands and cellular disruption is seen in left ventricular papillary muscle of dog sacrificed 24 hr after administration of minoxidil. Section of plastic-embedded tissue, 0.5 μm thick, alkaline toluidine blue stain. ×300.

sumed to contain calcium, occur soon thereafter (Fig. 2). Other organelles become displaced, and then disintegration of the sarcolemma and of entire fibers supervenes. By 8–24 hr after treatment, areas of hyaline necrosis and of myocytolysis are present in association with macrophages and fibroblasts. Similar ultrastructural changes have been found to be produced by minoxidil, one of the vasodilating antihypertensives (Figs. 3 and 4). The lesions produced by multiple dosing with any of the drugs mentioned above are not more extensive than those caused by one or two doses. In fact, the lesions heal and may not recur during continuous dosing. A tolerance develops which lasts for a short period, even after discontinuation of the dosing (*16*). A decrease in the adrenergic receptor population may be surmised to be involved in the mechanism of the tolerance. Such a phenomenon has been demonstrated in erythrocyte membranes of frogs treated for 24 hr with isoproterenol (*17*). The excessive calcium influx into myocardium that follows the initial dose of isoproterenol does not recur with multiple dosing when the myocardium becomes tolerant to the cardiotoxic effect (*18*).

Electrocardiographic examination is contributory in the assessment of cardiac effects. Marked sinus tachycardia, arrhythmias, and ST segment depression are seen in dogs soon after treatment with isoproterenol or diazoxide (*11*, *19*) (Fig. 5). Ventricular extrasystoles occurring 24 hr after treatment correlate with the presence of necrosis. ST segment depression is the main electrocardiographic change that occurs after development of the lesion in the rat.

Serum aspartate aminotransferase and creatine phosphokinase activities increase during the development of the myocardial lesion induced by isoproterenol. These activities are higher during the first or second day of treatment than they are 24 hr post-treatment, when values may return to normal (*20*), indicating that the degenerative changes are subsiding 24 hr after the end of dosing.

In a few instances, isoproterenol, hydralazine and diazoxide also have been reported to produce myocardial lesions in man (*21–23*). This is surprising, because multiples of the pharmacologic doses are required, particularly in the case of isoproterenol and hydralazine, to cause lesions in animals. However, several conditions (e.g., obesity, stress, pretreatment with mineralocorticoids) that greatly increase the susceptibility of the myocardium to the cardiotoxicity of these agents have been identified

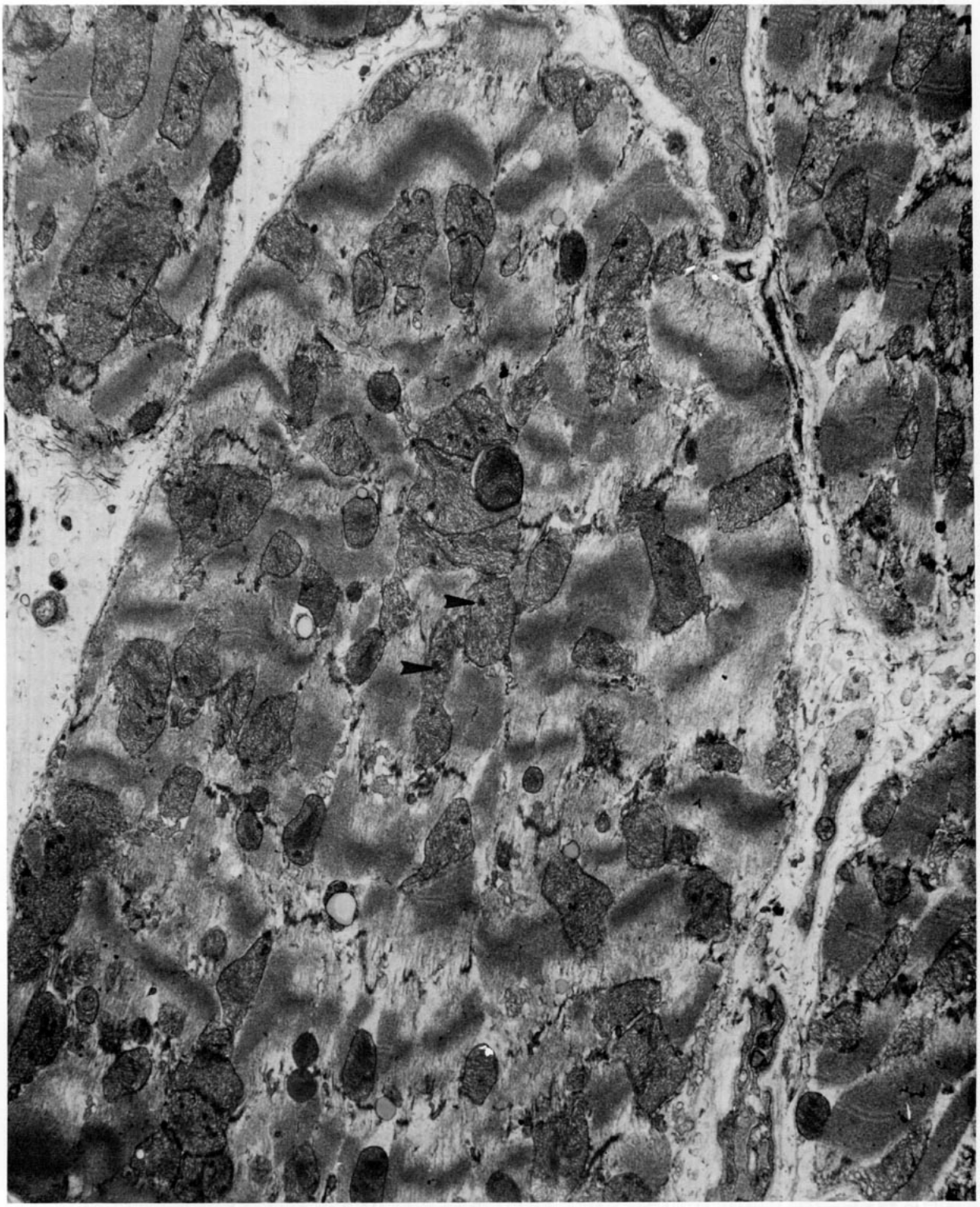

FIGURE 4. Electron micrograph of same tissue shown in Fig. 3. Note hypercontraction bands and electron-dense mitochondrial inclusions (arrowheads) ×11,000.

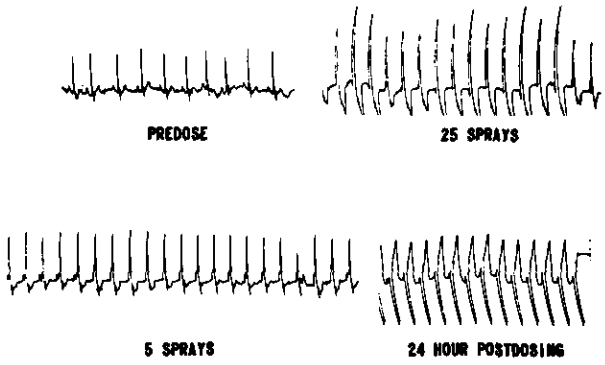

FIGURE 5. Tachycardia and A-V nodal (5 sprays), ventricular (25 sprays) arrhythmia with ST segment depression in dog following intratracheal spraying with pressurized aerosol isoproterenol. The ventricular tachycardia 24 hr after dosing suggests the presence of myocardial lesions. From Balazs et al. (*19*) with permission of Academic Press.

in experimental animals (*8, 24*). These or other factors (e.g., anemia, preexisting cardiovascular disease) could have a sensitizing influence in man. Propranolol, which blocks beta-adrenergic receptors, protects against the lesions induced by isoproterenol, hydralazine, and diazoxide in rats and in dogs (*11, 25*). These findings are consistent with the concept presented above on the mechanism of the lesion. These antihypertensive drugs generally are used for clinical treatment in combination with propranolol. Verapamil, an agent which blocks calcium influx, also provides protection against the necrosis induced by isoproterenol and hydralazine in the rat (Balazs, unpublished data), supporting the role of calcium influx in the pathogenesis of this lesion.

Cardiomyopathy Related to Direct Cardiotoxicity of Chemicals

The problems encountered in the evaluation of cardiotoxic effects of chemicals are illustrated by the following description of the cardiomyopathy produced by daunorubicin (DNR) and doxorubicin (DXR) (Adriamycin), two highly effective antineoplastic agents of the anthracycline type. The therapeutic usefulness of both of these compounds is limited by the development of acute and chronic cardiotoxicity. Acute cardiotoxic effects consist of hypotension, tachycardia, and various arrhythmias, which develop within minutes after intravenous administration (*26, 27*). Chronic toxicity is manifested by the insidious onset of severe, often fatal congestive heart failure; this may develop only after several weeks or months of treatment, sometimes after the course of therapy has been completed. The chronic cardiotoxicity is dose-dependent and generally occurs following a cumulative dose in excess of 500 mg/m^2 of body surface.

Anthracyclines induce complex biochemical effects on myocardium, including binding of anthracyclines to nuclear and mitochondrial DNA, with subsequent inhibition of the synthesis of RNA and proteins (*28*), inhibition of Na-K-dependent ATPase activity (*29*), inhibition of reactions utilizing coenzyme Q (*30*) and interference with other aspects of mitochondrial functions (*31*), alterations in calcium transport and in intracellular electrolyte balance (*32*), chelation of divalent cations (*32*), and promotion of lipid peroxidation by means of reactions involving free radicals (*33*). The relative importance of these effects in the pathogenesis of the acute and the chronic cardiotoxicity remains to be determined.

Acute Cardiotoxicity of Anthracyclines

Some of the acute effects of anthracyclines, i.e., the arrhythmias and the peripheral vascular effects, may be consequences of drug-induced release of histamine and catecholamines. Morphologic changes related to the acute arrhythmias have not been observed, although in chronic toxicity of DXR the specialized conducting cells of the rabbit heart show lesions similar to those in ordinary myocardium (*34*). Nucleolar segregation in the myocytes is the only cardiac morphologic change that has been found very soon (i.e., within minutes) after administration of DXR (*35, 36*). This change is in accord with observations showing that DXR and DNR penetrate into nuclei, where they can be detected by the reddish fluorescence that they impart to nuclei (*37, 38*), and that the nuclear binding involves intercalation of the drugs into nuclear DNA, thereby inhibiting nucleic acid and protein synthesis (*28*). The long-term significance of nucleolar segregation is unclear because this alteration disappears by 14 hr after DXR administration (*35*). Nuclear lesions have been observed only in a small percentage of cardiac muscle cells in patients who died from chronic anthracycline toxicity (*37, 39*). These lesions consists of various degrees of unraveling of nuclear chromatin fibers into the fine fibrils and filaments. Although these changes are not specific, as they occur in conditions other than anthracycline toxicity, they can be reproduced *in vitro* (*39*) by incubating pieces of myocardium with anthracycline-containing solutions. These observations suggest that cumulative damage to DNA in cardiac muscle cells (which cannot reproduce themselves, thus diluting damage to the genetic material) can result from the administration of repeated doses of anthracyclines, and that

such damage cannot be repaired properly, thus leading to interference with synthetic processes. These effects may be of crucial importance in the pathogenesis of anthracycline-induced cardiomyopathy, because the half-life of contractile proteins in myocardium is short (one to two weeks).

Chronic Cardiotoxicity of Anthracyclines

The morphologic changes in chronic anthracycline cardiotoxicity are cardiac dilatation and, less frequently, mural thrombosis; degeneration and atrophy of cardiac muscle cells; and interstitial edema and fibrosis. The first two of these changes are similar to those seen in patients with congestive (ventricular-dilated) cardiomyopathy. The degeneration of cardiac muscle cells can assume two forms: the first is characterized by loss of myofibrils, so that by light microscopy the affected cells appear pale-staining but nonvacuolated, and the second is manifested by marked cytoplasmic vacuolization, usually associated with myofibrillar loss. These features are basically similar in humans (*37, 39–41*) and in rat (*42*), mouse (*35, 43*) and rabbit (*32, 44*) models of DXR cardiotoxicity. These changes are related to total cumulative dose and also to the time scheduling of the individual doses. Such changes begin within 24 hr after the administration of a large, single dose of DXR (*35*) but take several weeks or months to develop when smaller, repeated doses are given. No significant variations have been found in the severity of morphologic changes demonstrated by different patients or experimental animals in response to a given total cumulative dose level. In histologic preparations the cytoplasmic vacuolization is detected more easily than is the myofibrillar loss. At the light microscopic level, both of these changes are seen most clearly by examining tissues fixed with glutaraldehyde, embedded in plastic resins, sectioned at a thickness of 0.5–1.0 μm and stained with alkaline toluidine blue (Fig. 6).

Electron microscopic studies (*35–37, 39–44*) have shown that degeneration of cardiac muscle cells in chronic anthracycline toxicity is a complex phenomenon that involves the myofibrils, the nuclei, the T tubules, the sarcoplasmic reticulum, the intercellular junctions, and the mitochondria. The myofibrils show lysis of the myofilaments, changes which account, at least in part, for the cellular atrophy. The vacuolization of the cytoplasm is mainly due to pronounced swelling of the sarcoplasmic reticulum (Fig. 7); accumulation of lipid and dilatation of the transverse tubular system also contribute to the vacuolated appearance. The intercellular junctions undergo dissociation, with formation of hemidesmosomes, intracytoplasmic junctions and spherical microparticles. These three types of change are also seen in myocardial degeneration of other causes (*45, 46*). The mitochondria show pleomorphism, decrease in size, alterations in the density of the matrix, and concentric lamellae (myelin figures) composed of electron-dense material. Calcium-containing intramitochondrial inclusions have not been demonstrated unequivocally in DXR or DNR toxicity. The interstitial edema is in accord with observations showing that cardiac tissues in DXR toxicity have an increased content of water, sodium, and calcium (*32*). The interstitial fibrosis is difficult to evaluate, because the cellular atrophy exaggerates the prominence of the interstitial connective tissue. Inflammatory reaction usually is absent or minimal and limited to the presence of small numbers of macrophages. Endothelial damage has been observed in rats (*42*) and mice (*43*) but not in rabbits.

Pathogenesis of Cardiac Morphologic Changes Induced by Anthracyclines

It seems likely that several different drug effects are important in the pathogenesis of the changes enumerated above. The myofibrillar loss probably results from interference with protein synthesis; the nuclear changes probably result from the binding of DXR or DNR to nuclear DNA. The pathogenesis of changes involving the membrane systems of the cell is less clear. Such changes also may be related to interference with normal synthesis and turnover of proteins in membranes, but other evidence suggests that peroxidation of membrane lipids may be an important factor. DXR and DNR can initiate lipid peroxidation by facilitating the transfer of electrons from endogenous compounds such as NADPH to oxygen, resulting in the formation of superoxides that can decompose to hydroxy radicals, peroxy radicals, and hydrogen peroxide. These, in turn, can oxidize unsaturated fatty acids in membranes to lipid peroxides (*47*).

The following three observations indicate that lipid peroxidation may play a role in the pathogenesis of anthracycline toxicity: (1) the administration of very large doses of α-tocopherol (vitamin E, a free radical scavenger) significantly reduces the acute toxicity and mortality of DXR in the mouse (*47*); (2) malondialdehyde, a product of the peroxidation and subsequent decomposition of unsaturated fatty acids, is readily detected in the hearts of mice for 2–6 days after administration of DXR, but not in the hearts of control mice or of mice treated with both DXR and α-tocopherol (*33*); and (3) ubiquinone, which acts as a free-radical

scavenger and as an antagonist to the inhibition by anthracyclines of reactions involving coenzyme Q, also has been reported to decrease the acute and chronic toxicity of DXR (*48*).

It is worthy of note that exposure of experimental animals to 100% oxygen at atmospheric pressure and room temperature for less than one week induces skeletal and cardiac muscle lesions (*49*) that resemble in several respects (particularly in the pronounced swelling of the sarcoplasmic reticulum) those produced by anthracyclines. It is possible that the oxygen-induced lesions are mediated by peroxidation damage to membrane systems. Nevertheless, the cardiac morphologic changes in DXR and DNR toxicity differ from those in radiation injury and in deficiency of selenium and vitamin E (Se-E), two conditions in which free-radical damage and peroxidation phenomena are thought to play a role in the pathogenesis of the cardiac damage. In radiation injury the initial cardiac damage is most prominent in capillary endothelial cells, which become edematous or necrotic; platelet and fibrin thrombi are frequent. Severe interstitial fibrosis develops subsequently, but at no time do the cardiac myocytes show alterations similar to those in chronic DXR toxicity (*50*). Comparison of the pathologic changes produced by DXR and by Se-E deficiency is of interest because selenium and vitamin E, in conjunction with glutathione peroxidase, form an antioxidant system that prevents the peroxidation of membrane lipids. Cardiac lesions in Se-E deficiency (*51, 52*) have been best characterized in the pig, and consist of: multiple foci of necrosis, with hyalinization or with hypercontraction bands and mitochondrial swelling, disruption, and calcification; intramyocardial hemorrhage ("mulberry heart"); fibrinoid necrosis of small intramural coronary arteries; and capillary microthrombi composed of fibrin and platelets. Thus, it would seem from the preceding comparisons that the cardiac morphologic features of the toxicity produced by peroxidation and free radical phenomena will vary depending upon the nature and site of release of the offending compounds.

Predictive Value of Animal Tests for Detection of Cardiac Lesions

The primary task of safety evaluation studies is the detection of toxic effects on the various organ systems. The complexity of this task is illustrated by the failure of detection of the myocardial lesions in preclinical studies with several of the compounds

FIGURE 6. Light micrograph of left ventricular myocardium of rabbit with doxorubicin cardiotoxicity. Some cells (center) are greatly vacuolated, whereas others (upper right) have a pale cytoplasm and have lost most of their myofibrils; the interstitium is edematous. Section of plastic-embedded tissue, 0.5 μm thick, alkaline toluidine blue stain. ×1000.

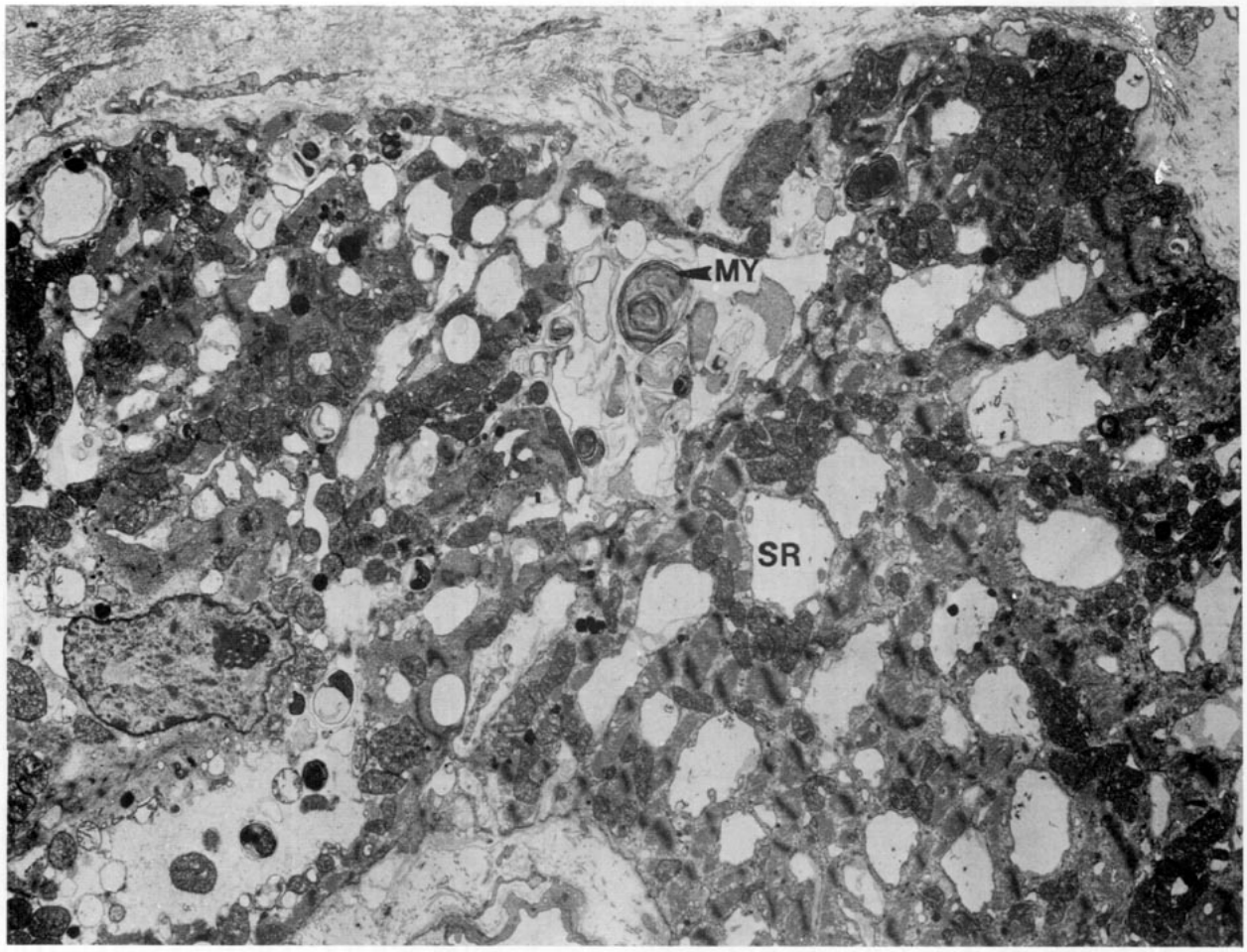

FIGURE 7. Electron micrograph of vacuolated cardiac muscle cell from same tissue as in Fig 6. Vacuolization is mainly due to marked dilatation of sarcoplasmic reticulum (SR). Myelin figures (MY) are present in moderate numbers. ×5000.

described above. Although isoproterenol is the model compound most widely used to produce myocardial necrosis in experimental animals, this effect was overlooked in the preclinical study (*53*). Similarly, the preclinical tests failed to detect the cardiotoxicity of anthracyclines, adrenergic beta-receptor agonists, and vasodilating antihypertensives. In the subacute study with isoproterenol, the failure to detect these effects may have been due to the fact that young rats were used, which are less sensitive to this drug than are older ones. Morever, the development of tolerance handicapped the detection of lesions in these studies.

The cardiotoxicity of the adrenergic beta-receptor agonist type of agent is best detected in acute studies. Treatment of two consecutive days is sufficient. The best time to record the electrocardiogram is during the peak of the pharmacological effect and 24 hr after the end of treatment. Animals are killed 24 hr after the end of treatment for gross and histological examinations. Examination of the papillary muscles should not be neglected; special staining techniques aid the detection of changes at an early stage (*54*).

The cardiotoxicity of anthracyclines was first discovered in patients and only thereafter was reproduced in animals. It is conceivable that animals on a daily treatment schedule with high doses died because of other toxic effects before heart lesions developed. The duration of tests was most likely too short for the development of cardiac lesions in animals given low dose levels. The clinical dosage is an intermittent one, e.g., once every 3 weeks. With intermittent dosing, the cardiotoxicity seen in humans was reproduced in rabbits and in rats. This finding indicates that the clinical dosage schedule

should influence the design of the animal experiments. Additional testing in animals appears to be in order when the clinical dose schedule differs from that used in preclinical testing. Electrocardiograms and measurements of serum enzymes of cardiac origin are also of value in evaluating anthracycline-induced cardiomyopathy in experimental animals.

The scope and design of a toxicity study are functions of the intended use of the chemical. The conditions encountered in the utilization of the chemical should be kept in mind, particularly with food additives, household products, etc., which, unlike pharmaceuticals, are not tested in humans prior to marketing. Their safety evaluation is based solely on data obtained from animals. Several conditions, e.g., the nutritional factors described above, can increase the susceptibility of the heart to the cardiotoxic effects of chemicals. The conditions associated with the use of the chemical should be incorporated in the toxicity study. For example, when cobalt was considered as a beer additive, it would have been prudent to test its cardiotoxicity in animals kept on alcohol and also given diets deficient in protein and thiamine, as test model conditions for heavy beer drinkers.

In a lecture on the predictive value of animal tests in relation to drugs affecting the cardiovascular system in man, Black (55) said: "When we consider animal tests as a means of assessing these risks, we must clearly distinguish between the predictions which could have been made from animal tests and the predictions which in fact were made before human experimentation."

Generally, animal tests can provide reliable information on the potential cardiotoxicity of chemicals. However, the cardiomyopathies described above demonstrate that carefully designed testing is necessary to improve the predictability of toxicity studies for these effects.

REFERENCES

1. Tiller, J. R., Schilling, R. S. F., and Morris, J. N. Occupational toxic factor in mortality from coronary heart disease. Brit. Med. J. 4: 407 (1968).
2. Raab, W. Neurogenic multifocal destruction of myocardial tissue (pathogenic mechanism and its prevention). Rev. Can. Biol. 22: 217 (1963).
3. Rona, G., and Chappel, C. I. Pathogenesis and pathology of cobalt cardiomyopathy. In: Recent Advances in Studies of Cardiac Structure and Metabolism. Vol. 2, Cardiomyopathies, E. Bajusz and G. Rona, Eds., University Park Press, Baltimore, Maryland, 1973, p. 407.
4. Boudoulas, H., et al. Hypersensitivity to adrenergic stimulation after propranolol withdrawal in normal subjects. Ann. Intern. Med. 87: 433 (1977).
5. Glaubiger, G. A., and Lefkowitz, R.J. Increased β-adrenergic receptor number in rat hearts after chemical sympathectomy or propranolol treatment. Circulation 56 (Part II, Suppl. III): I-158 (1977).
6. Selye, H. The Pluricausal Cardiopathies. C. C Thomas, Springfield, Ill., 1961.
7. Wenzel, D. G. Drug-induced cardiomyopathies. J. Pharm. Sci. 56: 1209 (1967).
8. Rona, G., Kahn, D. S., and Chappel, C. I. Studies on infarct-like myocardial necrosis produced by isoproterenol: A review. Rev. Can. Biol. 22: 241 (1963).
9. Balazs, T. Cardiotoxicity of sympathomimetic bronchodilator and vasodilating antihypertensive drugs in experimental animals. In: Experimental Model Systems in Toxicology and Their Significance in Man (Excerpta Medica, International Congress Series No. 311), Proceedings of the European Society for the Study of Drug Toxicity, 1973, p. 71.
10. Balazs, T., and Payne, B. J. Myocardial papillary muscle necrosis induced by hypotensive agents in dogs. Toxicol. Appl. Pharmacol. 20: 442 (1971).
11. Balazs, T., Herman, E. H., and Earl, F. L. Myocardial necroses induced by diazoxide and minoxidil in dogs and the effects of propranolol and digoxin on the minoxidil-induced lesions. In: New Antihypertensive Drugs, A. Scriabine and C. S. Sweet, Eds., Spectrum Publishing Co., Hollinswood, N. J., 1976, p. 535.
12. Fleckenstein, A., et al. Key role of Ca in the production of noncoronarogenic myocardial necroses. In: Recent Advances in Studies of Cardiac Structure and Metabolism, Vol. 6, Pathophysiology and Morphology of Myocardial Cell Alteration, A. Fleckenstein and G. Rona, Eds., University Park Press, Baltimore, 1975, p. 21.
13. Csapo, Z., Dusek, J., and Rona, G. Early alterations of the cardiac muscle cells in isoproterenol-induced necrosis. Arch. Pathol. 93: 356 (1972).
14. Bloom, S., and Cancilla, P. A. Myocytolysis and mitochondrial calcification in rat myocardium after low doses of isoproterenol. Am. J. Pathol. 54: 373 (1969).
15. Ferrans, V. J., et al. Isoproterenol-induced myocardial necrosis: a histochemical and electron microscopic study. Am. Heart J. 68: 71 (1964).
16. Balazs, T., Ohtake, S., and Noble, J. F. The development of resistance to the ischemic cardiopathic effect of isoproterenol. Toxicol. Appl. Pharmacol. 21: 200 (1972).
17. Mukherjee, C., Caron, M. G., and Lefkowitz, R. J. Regulation of adenylate cyclase coupled β-adrenergic receptors by β-adrenergic catecholamines. Endocrinology 99: 347 (1976).
18. Arndts, D. Drug effects on myocardial ^{45}Ca uptake in conscious rats. Arzneim. Forsch. 25: 1279 (1975).
19. Balazs, T., et al. The cardiotoxic effects of pressurized aerosol isoproterenol in the dog. Toxicol. Appl. Pharmacol. 26: 407 (1973).
20. Sadek, S. E., and Pfitzer, E. A. Correlation of histologic and serum enzyme changes of isoproterenol-induced myocardial lesions in dogs. Toxicol. Appl. Pharmacol. 33: 156 (1975).
21. Winsor, T. Isoproterenol toxicity. Am. Heart J. 89: 814 (1975).
22. Moyer, J. H. Hydrallazine (apresoline) hydrochloride: pharmacological observations and clinical results in the therapy of hypertension. Arch. Intern. Med. 91: 419 (1953).
23. Anonymous. Diazoxide: a review of its pharmacological properties and therapeutic use in hypertensive crises. Drugs 2: 78 (1971).
24. Balazs, T. Cardiotoxicity of isoproterenol in experimental animals. Influence of stress, obesity, and repeated dosing. In: Recent Advances in Studies of Cardiac Structure and Metabolism, Vol. 1, Myocardiology, E. Bajusz and G. Rona,

Eds., University Park Press, Baltimore, 1972, p. 770.
25. Dorigotti, L., et al. Competitive antagonism of isoprenaline-induced cardiac necroses by β-adrenoreceptor blocking agents. J. Pharm. Pharmacol. 21: 188 (1969).
26. Herman, E. H., et al. A comparison of the cardiovascular actions of daunomycin, Adriamycin and N-acetyldaunomycin in hamsters and monkeys. Pharmacology 6: 229 (1971).
27. Zbinden, G., and Brändle, E. Toxicologic screening of daunorubicin (NSC-82151), Adriamycin (NSC-123127), and their derivatives in rats. Cancer Chemother. Repts. 59: 707 (1975).
28. Arena, E., et al. DNA, RNA and protein synthesis in heart, liver, brain of mice treated with daunomycin or Adriamycin. IRCS Med. Sci. 2: 1053 (1974).
29. Gosalvez, M., and Blanco, M. Inhibition of Na-K ATPase by the antitumor antibiotic Adriamycin. Paper presented at 5th Int. Biophysics Congr. (abstract), (1975).
30. Iwamoto, Y., et al. Inhibition of coenzyme Q_{10}-enzymes, succinoxidase and NADH-oxidase, by Adriamycin and other quinones having antitumor activity. Biochem. Biophys. Res. Commun. 58: 633 (1974).
31. Bachmann, E., Weber, E., and Zbinden, G. Effect of seven anthracycline antibiotics on electrocardiogram and mitochondrial function of rat hearts. Agents Actions 5: 383 (1975).
32. Olson, H. M., et al. Electrolyte and morphologic alterations of myocardium in Adriamycin-treated rabbits. Am. J. Pathol. 77: 439 (1974).
33. Myers, C. E., et al. Adriamycin: The role of lipid peroxidation in cardiac toxicity and tumor response. Science 197: 165 (1977).
34. Gandolfi, A. Cardiotossicità cronica da Adriamicina: studio morfologico ultrastrutturale sul miocardio ventricolare e sul sistema de conduzione del cuore di coniglio. Ateneo Parmense (Acta Biomed.) 47: 69 (1976).
35. Lambertenghi-Deliliers, G., et al. Myocardial injury induced by a single dose of Adriamycin: an electron microscopic study. Tumori 62: 517 (1976).
36. Merski, A., Daskal, I., and Busch, H. Effects of Adriamycin on ultrastructure of nucleoli in the heart and liver cells of the rat. Cancer Res. 36: 1580 (1976).
37. Buja, L. M., et al. Cardiac ultrastructural changes induced by daunorubicin therapy. Cancer 32: 771 (1973).
38. Egorin, M. J., et al. Cytofluorescence localization of Adriamycin and daunorubicin. Cancer Res. 32: 2243 (1974).
39. Buja, L. M., Ferrans, V. J., and Rabson, A. S. (Letter). Unusual nuclear alterations. Lancet 1: 402 (1974).
40. Lefrak, E. A., et al. A clinicopathologic analysis of Adriamycin cardiotoxicity. Cancer 32: 302 (1973).
41. Bristow, M. R., et al. Endomyocardial biopsy and systolic time intervals in detection of Adriamycin cardiotoxicity. Circulation 53/54 (Suppl. II): II-80 (1976).
42. Chalcroft, S. C. W., Gavin, J. B., and Herdson, P. B. Fine structural changes in rat myocardium induced by daunorubicin. Pathology 5: 99 (1973).
43. Rosenoff, S. H., et al. Adriamycin-induced cardiac damage in the mouse. J. Natl. Cancer Inst. 55: 191 (1975).
44. Jaenke, R. S. An anthracycline antibiotic-induced cardiomyopathy in rabbits. Lab. Invest. 30: 292 (1974).
45. Buja, L. M., Ferrans, V. J., and Maron, B. J. Intracytoplasmic junctions in cardiac muscle cells. Am. J. Pathol. 74: 613 (1974).
46. Ferrans, V. J., et al. Spherical microparticles in human myocardium. An ultrastructural study. Lab. Invest. 35: 349 (1976).
47. Myers, C. E., McGuire, W., and Young, R. Adriamycin: amelioration of toxicity by α-tocopherol. Cancer Treat. Repts. 60: 961 (1976).
48. Bertazzoli, C., et al. Experimental Adriamycin cardiotoxicity prevented by ubiquinone *in vivo* in rabbits. IRCS Med. Sci. 3: 468 (1975).
49. Caulfield, J. B., Shelton, R. W., and Burke, J. F. Cytotoxic effects of oxygen on striated muscle. Arch. Pathol. 94: 127 (1972).
50. Fajardo, L. F., and Stewart, J. R. Pathogenesis of radiation-induced myocardial fibrosis. Lab. Invest. 29: 244 (1973).
51. Van Vleet, J. F., Ferrans, V. J., and Ruth, G. R. Ultrastructural alterations in nutritional cardiomyopathy of selenium-vitamin E deficient swine. I. Fiber lesions. Lab. Invest. 37: 188 (1977).
52. Van Vleet, J. F. Ferrans, V. J., and Ruth, G. R. Ultrastructural alterations in nutritional cardiomyopathy of selenium-vitamin E deficient swine. II. Vascular lesions. Lab. Invest. 37: 201 (1977).
53. Dertinger, B. L., Beaver, D. C., and Lands, A. M. Toxicity of 1-(3,4-dihydroxyphenyl)-2-isopropylaminoethanol hydrochloride (Isuprel). Proc. Soc. Exp. Biol. Med. 68: 501 (1948).
54. Lie, J. T., et al. New histochemical method for morphologic diagnosis of early stages of myocardial ischemia. Mayo Clin. Proc. 46: 319 (1971).
55. Black, J. W. The predictive value of animal tests in relation to drugs affecting the cardiovascular system in man. In: Drug Responses in Man, CIBA Foundation Symposium, G. Wolstenholme and R. Porter, Eds., Little, Brown and Co., Boston, 1967, p. 111.