Environmental Health Perspectives
Vol. 26, pp. 225–231, 1978

Pathophysiology of the Atherosclerotic Rabbit

by Robert J. Lee,* Intestar H. Zaidi,† and Sherrin H. Baky‡

The pathophysiology and histopathology caused by feeding rabbits a diet containing 2% cholesterol is described. Cholesterol deposition was seen in almost all organs after 15 weeks on the diet. Lesions were seen as early as 7 weeks in the aorta and pulmonary vessels and by 11 weeks in the small intramyocardial arteries and arterioles. Evidence of myocardial ischemia could be elicited by stressing the heart by electrical pacing at rapid rates or by administration of pharmacological agents which increased oxygen consumption (isoproterenol) or decreased oxygen supply (ergonovine). Susceptibility to such stress was increased by isovolumic hemodilution which decreased the oxygen-carrying capacity of the blood. Myocardial fibrosis and infarction were evident by 15 weeks on the diet and cardiac reserve was depleted by 25 weeks as evidenced by the presence of ascites in all animals examined.

The preliminary results reported here suggest that further evaluation of the atherosclerotic rabbit as a cardiac toxicity model is warranted.

Introduction

Stein (*1*) reported that intravenous administration of ergonovine maleate to patients with coronary artery disease precipitated an attack of angina pectoris accompanied by ischemic S-T segment changes in the electrocardiogram (ECG). In the search for an animal experimental model of coronary artery disease, this ergonovine stress test was later employed in atherosclerotic rabbits (*2*). These authors reported that rabbits fed diets high in cholesterol content for 2.5 to 5 months were susceptible to ergonovine-induced ischemic S-T segment depression. This paper describes more recent studies utilizing this model, including physiological and pharmacological stress testing and a pathophysicological study.

Methods

All physiological and pharmacological studies were performed in the absence of general anesthesia. Male New Zealand White rabbits were obtained at approximately 3 months of age and placed on a 2% cholesterol diet for 7 to 25 weeks. The experimental methods for surgical preparation of the animals have been described in detail elsewhere (*3*). Briefly, the rabbits were lightly restrained on their backs and a 14-gauge polyvinyl catheter was implanted into the superior vena cava via the anterior facial branch of the external jugular vein under local anesthesia (procaine HCl). The catheter was filled with heparinized saline and the wound closed.

On subsequent experimental days the animal was restrained as above without anesthesia. Surface leads were placed over the spine and sternum for recording the ECG at a sensitivity of 1 mV/cm on a physiological recorder and on magnetic tape for computer analysis of S-T segment deviation.

For those experiments in which right atrial pacing at rapid rates was the stress employed, a pacing electrode was inserted via the indwelling catheter into the right atrium. Stimuli were supplied by a Grass S-8 stimulator at approximately 1.5 times threshold voltage. The pacing rate chosen was at least 100 beats/min above the intrinsic heart rate to a maximum of approximately 400 beats/min.

* Department of Pharmacology, Arnar-Stone Laboratories Inc., 1600 Waukegan Rd., McGaw Park, Illinois 60085.
† Department of Pathology, Squibb Institute for Medical Research, Georges Road, New Brunswick, New Jersey.
‡ Medical Department, Knoll Pharmaceutical Company, 30 North Jefferson Road, Whippany, New Jersey 07981.

The effects of the added stress of serial isovolumic hemodilution on pacing-induced ischemia were studied in 24 atherosclerotic and 14 normal rabbits. For these studies the right femoral artery was cannulated under local anesthesia for measurement of blood pressure and for the hemodilution procedure. After a control pacing stress, 10 ml of blood was removed and replaced with 10 ml of Dextran 75. The pacing stress was then repeated. This procedure was repeated up to four times in a given animal. Hematocrit values of the withdrawn blood were determined after each hemodilution.

When isoproterenol (Isuprel) infusion was used to stress the heart a constant volume of 0.2 cc/min for 10 min was infused. The concentration of isoproterenol in the solution was such that 1, 2 or 3 μg/kg-min was infused. The dose chosen was that which caused significant ischemic S-T segment deviation.

For the histopathology study rabbits were sacrificed after eating the high cholesterol diet for 7 weeks (4 rabbits), 11 weeks (4 rabbits), 15 weeks (8 rabbits), and 25 weeks (3 rabbits). Eight additional rabbits of the same age were fed an identical diet except for the addition of cholesterol and served as normal controls. The rabbits were examined for ocular and other external lesions. Approximately 10 ml blood was collected through cardiac puncture, and the animals were sacrificed by injection of Euthanasia solution (containing sodium butabarbital, sodium pentobarbital, and isopropyl alcohol). Post-mortem examination was conducted on all animals. Hematoxylin-eosin-stained paraffin sections of the following organs were prepared and examined microscopically: trachea, lungs, aorta, heart, esophagus, stomach, small intestine, large intestine, liver, thymus, adrenal gland, skin, bone (femur), spleen, eye, kidney, and brain. Frozen

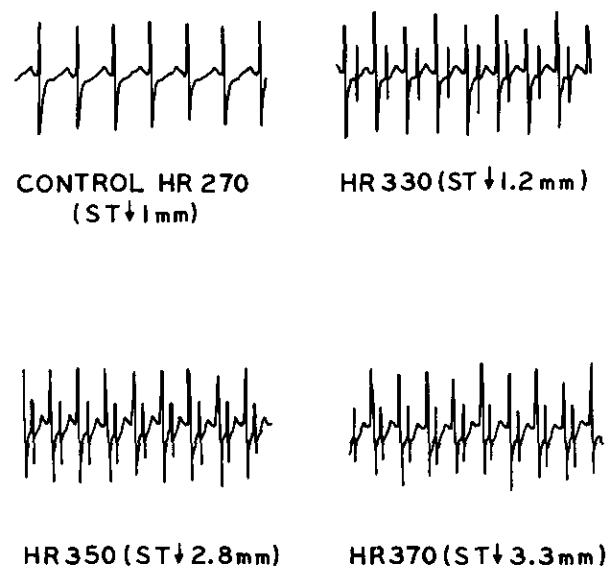

FIGURE 1. Electrocardiographic tracings from a rabbit after 20 weeks on the high cholesterol diet. The S-T segment was depressed 1 mm in the control at a heart rate of 270 beats/min. Each increment in rate during pacing caused a further depression of the S-T segment. The small spikes during pacing represent the stimulus artifact.

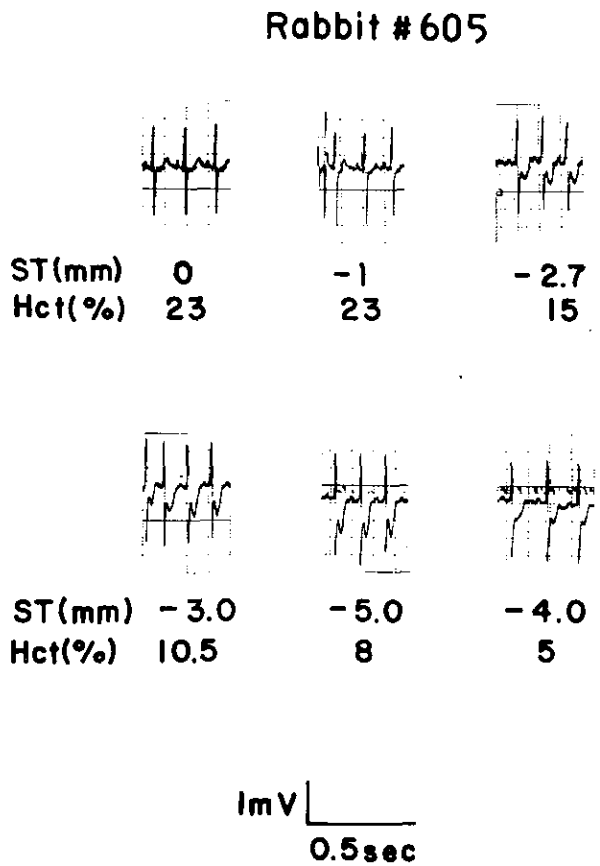

FIGURE 2. Effects of serial hemodilution on the S-T segment response to pacing (390 beats/min) in an atherosclerotic rabbit. The upper left tracing represents the control ECG prior to pacing. The S-T segment was isoelectric and the control hematocrit was 23%. The middle trace shows the first few beats after cessation of 90 sec of pacing which caused S-T segment depression of 1 mm. The upper right trace shows the effects of the identical pacing stress after one hemodilution. The hematocrit was 15% and the S-T segment depression increased to 2.7 mm. The lower traces show the effects of subsequent hemodilution.

sections of liver, kidney, and adrenal gland were prepared and stained with Oil Red O for fat.

Results

Pacing-Induced S-T Segment Depression

S-T segment depression, presumably a manifestation of subendocardial ischemia (*4*), could be elicited by atrial pacing at rapid rates in some animals after 7 weeks on the high cholesterol diet (*3*). Prolonged feeding of this diet increased the incidence and degree of S-T segment depression. Several animals exhibited spontaneous S-T segment depression without the stress of pacing (Fig. 1). Increasing the heart rate by pacing intensified the S-T segment depression in these animals.

The effects of serial hemodilution on pacing-induced S-T segment depression is illustrated in Fig. 2. This animal had been on the high cholesterol diet for 10 weeks. The control hematocrit was 23% and pacing at 390 beats/min caused an S-T segment depression of 1 mm. After the first hemodilution, the hematocrit was reduced to 15% and the S-T segment depression elicited by the same pacing stress increased to 2.7 mm. Subsequent hemodilutions further increased the susceptibility of the heart to pacing-induced ischemia.

The fact that the atherosclerotic rabbits as a group were anemic may be seen in Figure 3, which compares the hematocrit values with those of the normal rabbits.

Effects of Isoproterenol Infusion

Infusion of isoproterenol caused an increase in heart rate accompanied by ischemic S-T segment depression in approximately half of the animals and S-T segment elevation in the rest. An example of isoproterenol-induced S-T segment depression is seen in Figure 4. Administration of the coronary vasodilator dipyridamole (Persantin) caused a further depression of the S-T segment indicating an exacerbation of the underlying ischemia.

Isoproterenol-induced S-T segment elevation is illustrated in Figure 5. Administration of the beta-adrenergic blocking agent nadolol blocked the tachycardiac effects of isoproterenol causing a return of the S-T segment to control values.

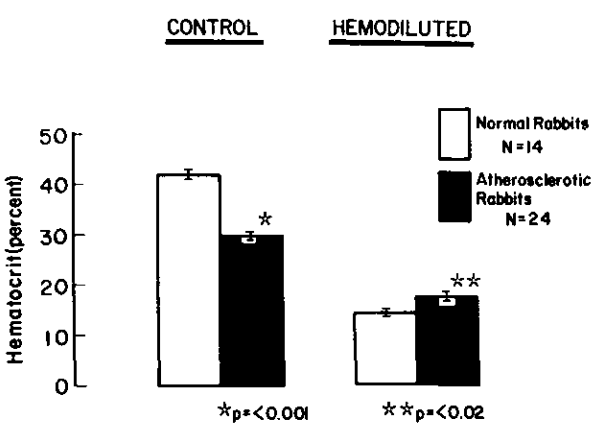

FIGURE 3. Hematocrit values of normal and atherosclerotic rabbits before (control) and after hemodilution sufficient to cause susceptibility to pacing-induced S-T segment depression. The atherosclerotic rabbits are clearly anemic.

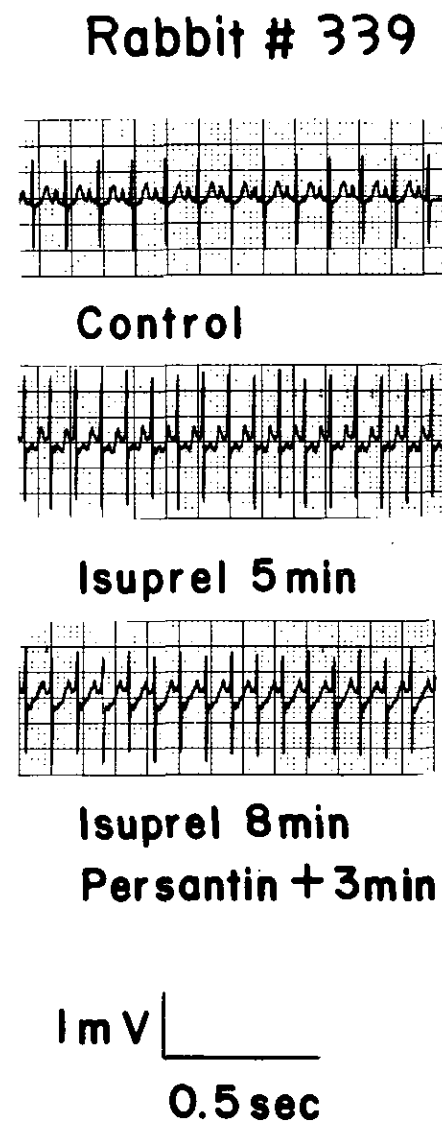

FIGURE 4. Example of S-T segment depression caused by infusion of isoproterenol (Isuprel). The coronary vasodilator Persantin (dipyridamole) was injected intravenously during the isoproterenol infusion and caused an exacerbation of the S-T segment depression.

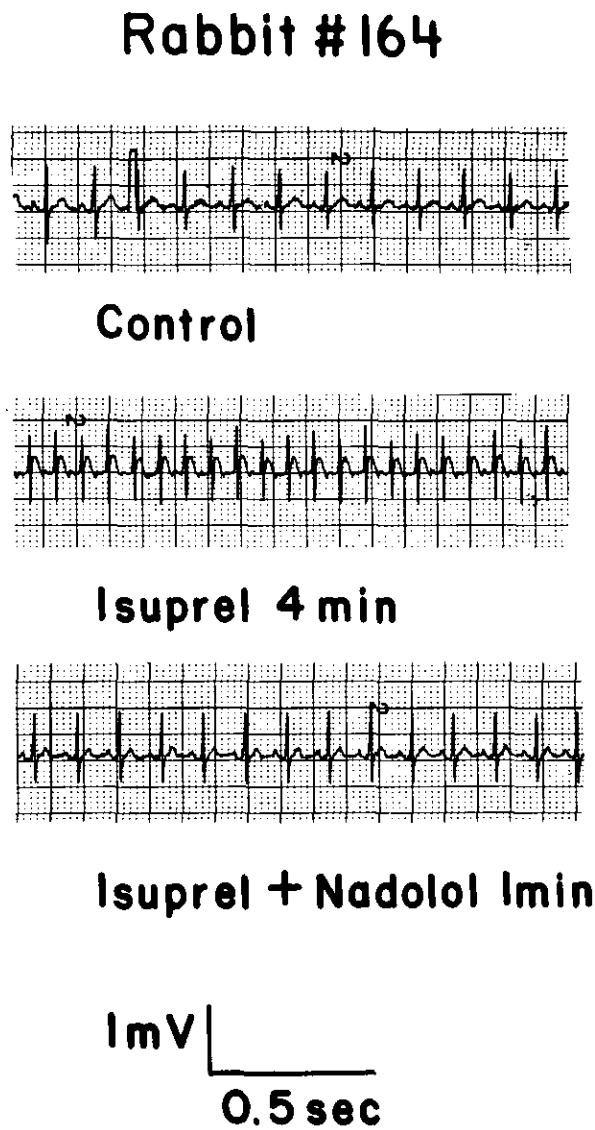

FIGURE 5. ECG tracings from an experiment in which isoproterenol infusion caused S-T segment elevation. The effects of isoproterenol are blocked by the beta-adrenergic blocking agent nadolol.

Histopathological Results

The serum cholesterol levels of the test rabbits were greater than 1,420 mg/100 ml, whereas those of controls were less than 71 mg/100 ml. A summary of the sequence of pathological changes seen in cholesterol-fed rabbits is presented in Table 1.

Cardiovascular System. The earliest atheromatous changes were seen in the thoracic aorta and pulmonary vessels after seven weeks of feeding the atherogenic diet. The aortic plaques were whitish, slightly raised, streaks with well-defined margins. Histologically, they showed intimal thickening by phagocytic cells with a large, foamy cytoplasm, sometimes containing cholesterol clefts. These "lipoidal histiocytes" were generally confined to intima but were, in some cases, seen in the media, suggesting phagocytosis of the lipid material by smooth muscle cells of the aorta. No lesions were seen in the abdominal aorta.

Table 1. Pathological changes seen in atherosclerotic rabbits.

Organ	Change[a] 7 Wk	11 Wk	15 Wk	25 Wk
Heart				
Atheromatosis, large arteries	−	−	±	+
Atheromatosis, small arteries	−	+	+	+
Myocardial fibrosis and infarction	−	−	+	+
Aorta				
Atheromatosis, thoracic aorta	+	+	+	+
Atheromatosis, abdominal aorta	−	−	−	−
Lungs				
Atheromatosis, large arteries	+	+	+	+
Atheromatosis, small arteries	+	+	+	+
Atheromatosis, veins	+	+	+	+
Atheromatosis, venules	−	−	+	+
Spleen				
Atheromatosis, Central arteries	−	±	+	+
Lipoidal histiocytes	+	+	+	+
Liver				
Atheromatosis of hepatic arteries	−	±	+	+
Lipoidal infiltration, hepatocytes	+	+	+	+
Eyes				
Lipoidal histiocytes	−	+	+	+
Other changes:				
Jaundice	−	+	+	+
Ascites (milky)	−	−	+	+
Hydropericardium	−	−	−	+
Bone marrow necrosis	−	−	+	+

[a] Changes: − = absent; + = present.

The pulmonary vessels involved were large arteries, arterioles, and some veins, the arterioles being the most severely affected. These vessels were almost completely or partially occluded by intimal thickening (Fig. 6). After 15 weeks of dosing some veins in the lung showed a perivascular cuffing by lipoidal histiocytes.

The changes in cardiac vessels were first observed after 11 weeks of dosing and affected small intramyocardial arteries predominantly in the subendocardial region. Within 15 weeks on the diet, this resulted in almost complete occlusion of the small intramyocardial (Fig. 7) and partial occlusion of the large intramyocardial and coronary arteries (Fig. 8). Multiple foci of myocardial fibrosis (Fig. 7), usually involving the papillary muscles, were seen in most and myocardial infarction (Fig. 9) in some of the hearts. After 25 weeks of dosing, the vascular and myocardial changes were more severe. In addition, hydropericardium was seen in all animals treated for 25 weeks.

Small arteries of spleen, liver, bone, and bone marrow also showed atheromatous occlusion after

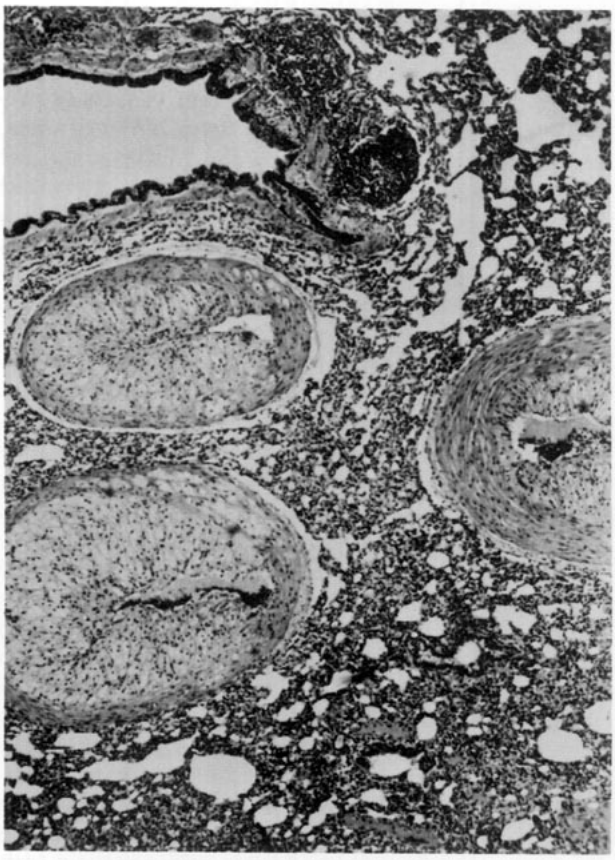

FIGURE 6. Photomicrograph of lung of a rabbit fed 2% cholesterol in the diet for 15 weeks. The lumina of the arterioles are completely or almost completely obliterated due to intimal thickening by lipid-laden cells. Similar cells are also seen in the smooth muscle layer of the media. × 35.

15 weeks. No such changes were seen in the renal or cerebral vessels of the rabbits dosed for up to 25 weeks.

Kidneys. Cytoplasm of the epithelial cells was granular, eosinophilic, and contained many vacuoles and clefts. Under polarized light, epithelium of most of the renal tubules and some glomeruli displayed numerous birefringent, acicular, cholesterol crystals. Although changes in the tubules were primarily infiltrative in nature, necrosis of some of the distal tubules was also evident.

Liver. The livers of all cholesterol-fed animals were enlarged and grayish in color. The hepatocytes were swollen and their cytoplasm distended with vacuoles of different sizes. In addition, cholesterol crystals were seen in the cytoplasm of many of the cells. These changes were more pronounced in the centrolobular region with some of the cells showing necrotic changes. Jaundice was seen in the animals treated for 11 weeks or more.

Other Organs. Spleen, bone marrow, skin (dermis), adrenal gland, choroid plexus, stomach (lamina propria), eyes (ciliary body, iris, choroid plexus), and thymus contained numerous lipoidal histiocytes. Nodular lesions containing cholesterol were seen at the esophagogastric junction and choroid plexus of the rabbits given cholesterol for 25 weeks. Four of the eight rabbits treated for 15 weeks had ascites.

No pathological changes were seen in the 8 rabbits fed a normal diet without the addition of cholesterol.

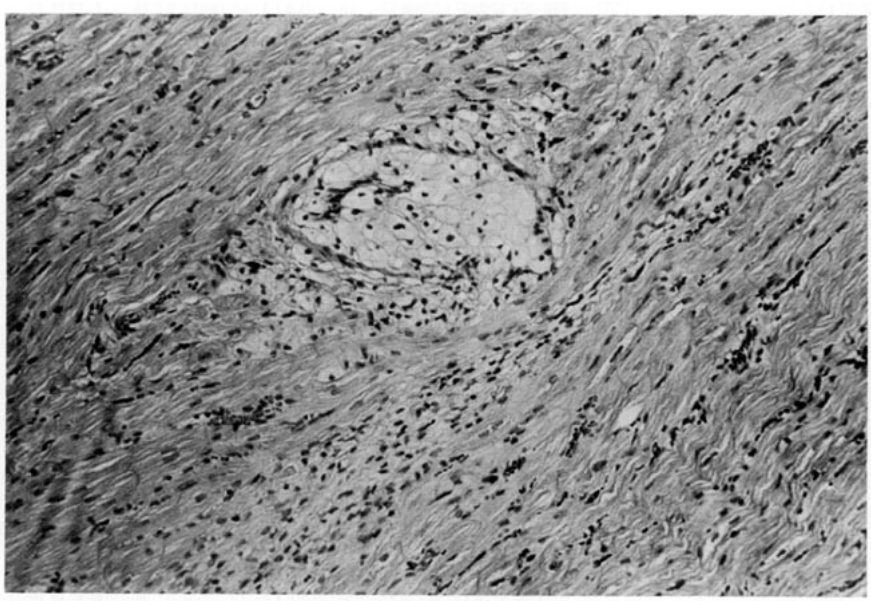

FIGURE 7. Photomicrograph of the heart of a rabbit fed 2% cholesterol in the diet for 15 weeks. An intramyocardial arteriole is almost completely occluded by intimal thickening. A streak of fibrosis is seen below the vessel. × 88.

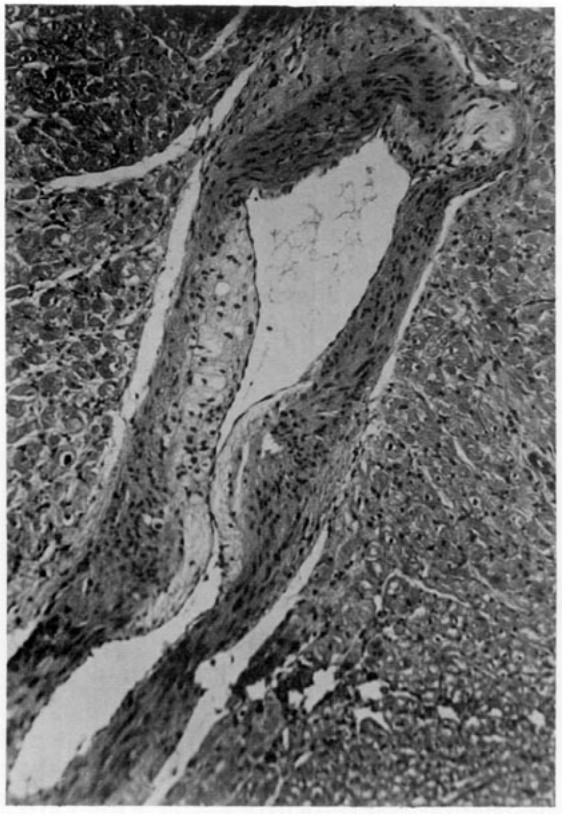

FIGURE 8. Photomicrograph of the heart of a rabbit fed 2% cholesterol in the diet for 15 weeks. Several plaques are seen in an intramyocardial artery. A small branching arteriole (top left) is completely occluded. × 100.

Discussion

Feeding a diet pelleted with 2% cholesterol produced plaques in the aorta and other vessels of rabbits. These lesions primarily involved the aorta, pulmonary and coronary vessels. In the aorta, the lesions remained confined to the thoracic part in the rabbits dosed for up to 25 weeks. They did not show significant fibrosis or calcification but were grossly similar to the fatty streaks of early human lesions. Some of the smooth muscle cells of the media of pulmonary arteries and aorta contained lipid material similar to that seen in the intima.

In the heart, the vascular changes were progressive in nature. They first affected the small intramyocardial arteries towards the endocardium and were observed after 11 weeks of dosing. By the 15th week, larger arteries, including the major coronaries became involved. This period (approximately 10–16 weeks) corresponds to the period during which the most consistent results were obtained with pacing-induced cardiac stress testing and nitroglycerin administration (3). Early involvement of the subendocardial vessels undoubtedly resulted in subendocardial ischemia as oxygen consumption was increased as a result of pacing at rapid heart rates.

As involvement of the larger coronary arteries progressed, vascular occlusions occurred resulting in areas of myocardial fibrosis and necrosis, presumably following atrophy of cardiac muscle fibers. After 25 weeks of dosing, the coronary reserve was



FIGURE 9. Photomicrograph of the heart of a rabbit fed 2% cholesterol in the diet for 15 weeks. An area of myocardial infarction with dystrophic calcification is seen at right. × 84.

apparently utilized to maintain the needs of the heart at rest since ischemic S-T segment depression was easily elicited with pacing and, in some cases, was present without stressing the heart (Fig. 1). Under these conditions, prior administration of nitroglycerin was without effect on the pacing-induced S-T segment depression (*3*). The amount of viable myocardium remaining after 25 weeks of dosing was probably marginal as indicated by the presence of ascites in all 3 animals examined.

The histopathological findings support our hypothesis of an accelerated progression of coronary artery disease and help to explain our findings with atrial pacing and nitroglycerin administration.

Whether or not the atherosclerotic rabbit model is useful as a cardiac toxicity model must be determined by qualified toxicologists. Our early results using atrial pacing at rapid heart rates to stress the heart (*3*) suggested that a pharmacological agent which increased oxygen consumption to a sufficient degree would cause ischemic S-T segment changes. This was borne out by the findings reported here with isoproterenol which suggest that the model may be useful if electrocardiographic S-T segment changes can be considered toxic manifestations. There is no question that they represent transient myocardial ischemia, with S-T segment depression believed to signify a less severe subendocardial ischemia and S-T segment elevation a more severe transmural ischemia (*4*).

Since there is a delicate balance between oxygen supply and demand in these compromised hearts, an agent which caused a decrease in oxygen supply might be expected to cause ischemic S-T segment changes. Rinzler, et al. have, in fact, shown that administration of ergonovine, which presumably causes coronary arterial spasm, causes S-T segment depression in the atherosclerotic rabbit (*2*). A more subtle drug effect of this nature might be seen if the agent was administered during a cardiac stress procedure. An example of this is demonstrated in Figure 4, in which dipyridamole (Persantin) was given during isoproterenol infusion and caused an exacerbation of the S-T segment depression probably due to "coronary steal." When the beta-adrenergic blocking agent propranolol was administered to paced rabbits it caused a worsening of the S-T segment depression (*5*) probably due to blockade of coronary artery beta receptors causing alpha constriction.

REFERENCES

1. Stein, I. Observations on the action of erganovine on the coronary circulation and its use in the diagnosis of coronary artery insufficiency. Am. Heart J. 37: 36 (1949).
2. Rinzler, S., et al. Detection of coronary atherosclerosis in the living rabbit by the erganovine stress test. Am. J. Physiol. 184: 605 (1956).
3. Lee, R. J., and Baky, S. H. The influence of nitroglycerin and dipyridomole on pacing-induced S-T segment depression in unanesthetized, atherosclerotic rabbits. J. Pharmacol. Exptl. Therap. 184: 205 (1972).
4. Prinzmetal, M., et al. Angina pectoris. III. Demonstration of a chemical origin in S-T deviation in classic angina pectoris, its variant form, early myocardial infarction and some noncardiac conditions. Am. J. Cardiol. 3: 276 (1959).
5. Baky, S. H., and Lee, R. J. Effects of several antianginal agents on pacing-induced S-T segment depression in the atherosclerotic rabbit. Proc. Soc. Exptl. Biol. Med. 148: 834 (1975).