Environmental Health Perspectives
Vol. 44, pp. 1-8, 1982

The Eye and Visual Nervous System: Anatomy, Physiology and Toxicology

by Connie S. McCaa*

The eyes are at risk to environmental injury by direct exposure to airborne pollutants, to splash injury from chemicals and to exposure via the circulatory system to numerous drugs and bloodborne toxins. In addition, drugs or toxins can destroy vision by damaging the visual nervous system.

This review describes the anatomy and physiology of the eye and visual nervous system and includes a discussion of some of the more common toxins affecting vision in man.

Anatomy of the Eyeball

The eye consists of a retinal-lined fibrovascular sphere which contains the aqueous humor, the lens and the vitreous body as illustrated in Figure 1.

The retina is the essential component of the eye and serves the primary purpose of photoreception. All other structures of the eye are subsidiary and act to focus images on the retina, to regulate the amount of light entering the eye or to provide nutrition, protection or motion. The retina may be considered as an outlying island of the central nervous system, to which it is connected by a tract of nerve fibers, the optic nerve.

As in the case of the brain and the spinal cord, the retina is within two coats of tissue which contribute protection and nourishment. On the outside of the sphere, corresponding to the dura mater, a layer composed of dense fibrous tissue serves as a protective envelope, the fibrous tunic. The posterior part of the fibrous tunic, the sclera, is white and opaque. Although it retains its protective function, the anterior portion, the cornea, is clear and transparent.

Immediately internal to the sclera, and between it and the retina, lies the uvea, a vascular tunic analogous to the pia-arachnoid of the central nervous system. Primarily, the uvea provides nutrients to the eye. The posterior portion of the uvea is the choroid, a tissue composed almost entirely of blood vessels. A second portion of the uvea, the ciliary body, lies just anterior to the choroid and posterior to the corneoscleral margin and provides nutrients by forming intraocular fluid, the aqueous humor. In addition, the ciliary body contains muscles which provide a supporting and focusing mechanism for the lens. The most anterior portion of the uveal tract, the iris, is deflected into the interior of the eye. The iris acts as a diaphragm with a central rounded opening, the pupil, which dilates to allow more light to the retina in dim lighting and constricts in bright lighting. The iris also has some degree of nutritive function, since it acts to help regulate the fluid flow in the eye.

The lens, the focusing mechanism of the eye, is located immediately behind the iris and is supported from the ciliary body by a suspensory ligament, the zonule. The space between the iris and the lens is called the posterior chamber. The anterior chamber consists of the space between the iris and the cornea. Behind the lens is the vitreous, a gel-like, transparent body which occupies the space between the lens and the retina.

The Cornea

The cornea, the window of the eye, is unique because of its transparency. Corneal transparency is dependent on a special arrangement of cells and collagenous fibrils in an acid mucopolysaccharide

*Division of Ophthalmology, University of Mississippi School of Medicine, Jackson, Mississippi 39216.

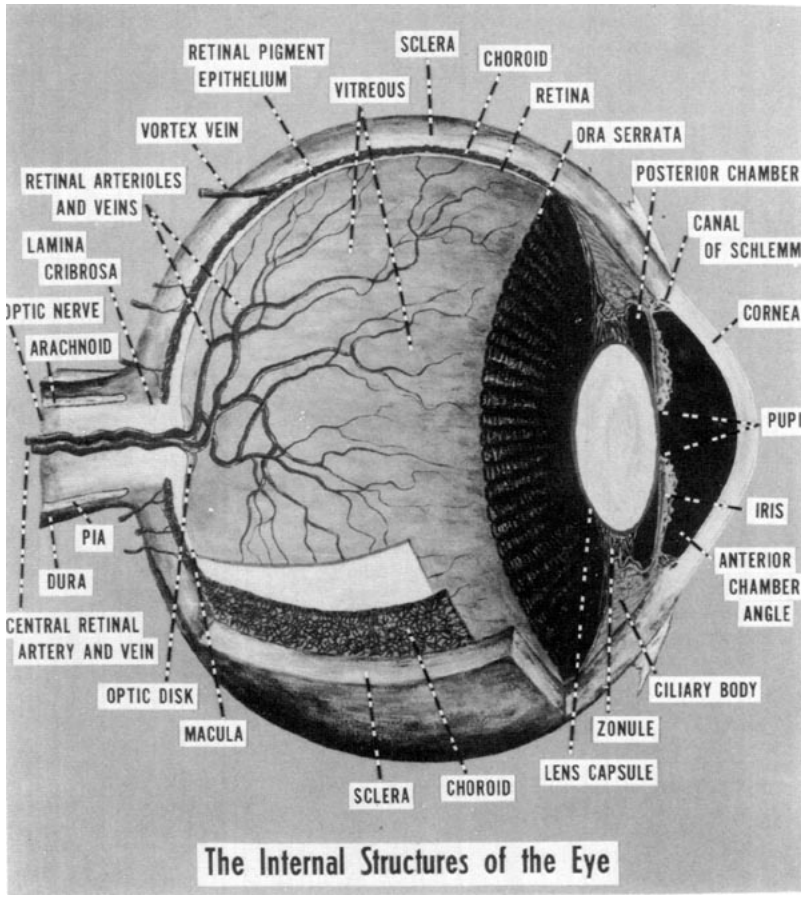

FIGURE 1. The internal structure of the eye.

environment, to an absence of blood vessels, and to deturgescence (the state of relative dehydration of corneal tissue). Any toxin interfering with any one of these factors may result in corneal opacification.

Structure of the Cornea

As illustrated in Figure 2, the cornea is composed of five distinct layers: (1) epithelium, (2) Bowman's membrane, (3) stroma, (4) Descemet's membrane and (5) endothelium. In addition, a tear film always covers the cornea of a healthy eye.

The Tear Film. The tear film is made up of three layers. The portion immediately next to the epithelium is rich in glycoprotein produced by the goblet cells of the conjunctival epithelium; a middle, watery layer is secreted by the lacrimal glands; an outside oily layer is produced by the meibomian glands and the glands of Moll and Zeis of the lid. The tear film is essential for the maintenance of the proper optical qualities of the cornea and its deficiency may result in corneal damage.

Corneal Epithelium. The corneal epithelium consists of five or six layers of cells which rest on a basement membrane. It is replaced by growth from its basal cells with perhaps greater rapidity than any other stratified epithelium (*1*).

Bowman's Membrane. Bowman's membrane is not a true basement membrane but is a clear acellular layer which is a modified portion of the superficial stroma. It is a homogenous layer without cells and has no capacity to regenerate if injured.

Corneal Stroma. The stroma makes up approximately 90% of the thickness of the cornea. It consists of alternating lamellae of collagenous tissue parallel to the surface of the cornea. The corneal cells, or keratocytes, are relatively few and lie within the collagen lamellae (*1*).

Descemet's Membrane. Descemet's membrane

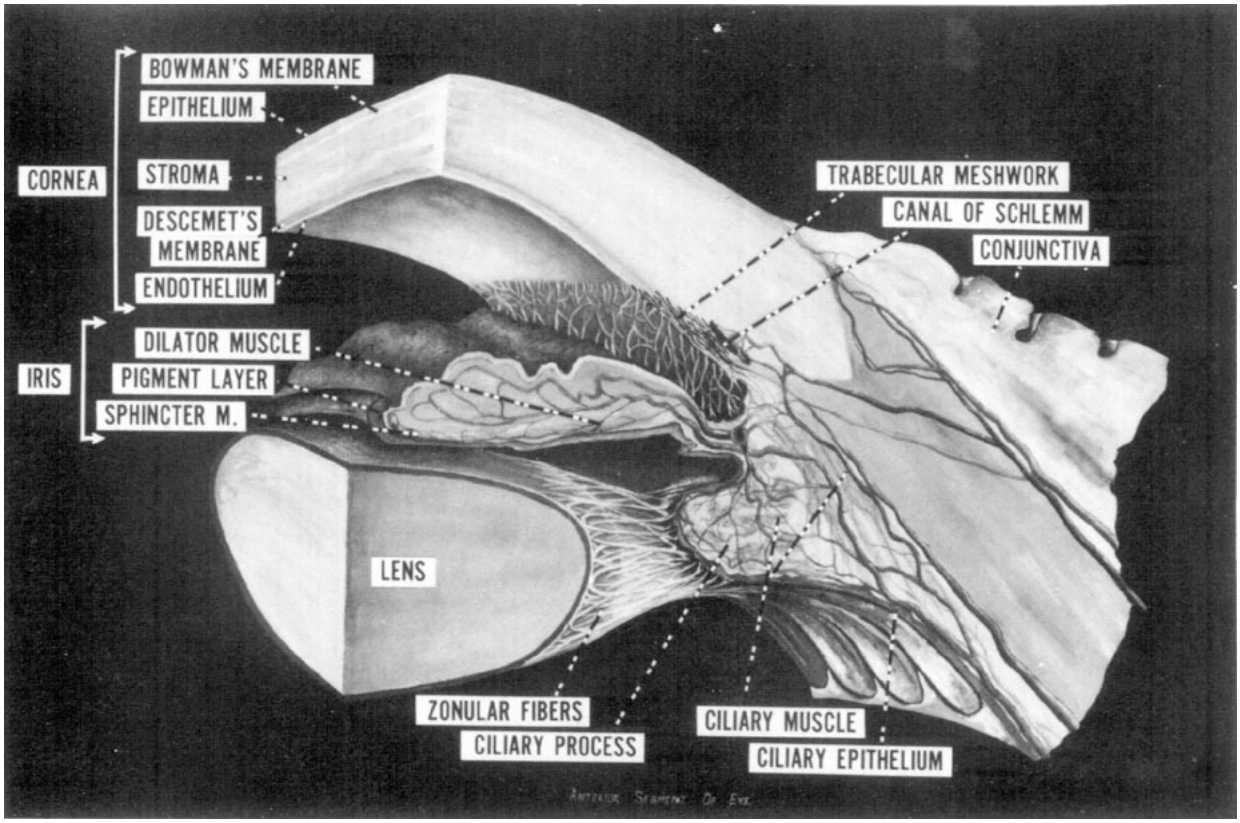

FIGURE 2. Structure of the anterior compartment of the human eye.

is a strong, homogeneous true basement membrane. It is produced by the endothelial cells and can be regenerated if injured. Descemet's membrane is elastic and is more resistant than the remainder of the cornea to trauma and disease.

Corneal Endothelium. The corneal endothelium consists of a single layer of flattened cuboidal cells. The endothelium does not regenerate and is essential for maintaining dehydration of corneal tissue. Therefore, chemical or physical damage to the endothelium of the cornea is far more serious than epithelial damage. Destruction of the endothelial cells may cause marked swelling of the cornea and result in loss of its transparency.

Permeability of the Cornea to Drugs or Toxins

The penetration of drugs through the cornea is by differential solubility. The epithelium and endothelium will allow the passage of fat-soluble substances, and the stroma will allow the passage of water-soluble substances. All drugs that readily enter the eye after topical application have the ability to exist in equilibrium in solution as ionized and nonionized forms. In the nonionized form they traverse the endothelium and epithelium and in the ionized form penetrate the stroma (*2*).

Toxic Agents Affecting the Cornea

Caustic Agents. Accidental splashing of substances into the eyes is the most common cause of toxic eye injuries. Alkalies and acids may result in rapid, deep, penetrating damage to cornea and deeper eye structures. The injuries produced by alkalies and acids are principally a result of extreme change of the pH within the tissue, an almost immediate action which can be treated only by rapid emergency action. There may be rapid dissolution of epithelium and clouding of corneal stroma from alkalies or coagulation of epithelium by acids,

but many changes appear later, including edema, further opacification, vascularization and degeneration of the cornea. Alkali injury notoriously results in late changes with extreme corneal injury and opacification.

Organic Solvents. Organic solvents, especially those which are good fat solvents, may cause loss of some or all of the corneal epithelium. Yet, even if all the epithelium is lost from the cornea as a result of organic solvents, it generally regenerates in a few days without residual permanent damage (*3*).

Gases, Vapors and Dusts. A great many gases, vapors and dusts induce stinging sensations in the eyes and stimulate tearing. Some of these may cause permanent corneal damage. For example, scarring and distortion of the cornea have disabled workmen many years after chronic industrial exposure to the dusts or vapors resulting from the manufacture of hydroquinone, a chemical used in photographic film development (*3*).

Deposits in the Cornea. Some drugs such as chloroquine, hydroxychloroquine and chlorpromazine produce deposits in the corneal epithelium. These deposits generally appear as fine granules scattered throughout the epithelium. Usually the deposits do not interfere with vision but may defract light and produce an appearance of halos around light. These deposits are generally reversible when the drugs are discontinued.

The Sclera

The sclera is hydrated and has large collagen fibrils arranged haphazardly; therefore, it is opaque and white rather than clear. The sclera has three layers: the episclera, the outer layer; the sclera; and the melanocytic layer, the inner lamina fusca. The episclera, a highly vascular connective tissue, attaches Tenon's capsule to the sclera. The sclera proper is relatively avascular and contains considerable elastic tissue. The sclera is approximately 1 mm thick posteriorly and gradually thins to about 0.3 mm just posterior to the insertions of the recti muscles. Therefore, these sites posterior to the insertion of the muscles are the areas of the eye which are most liable to rupture with trauma to the globe.

The Retina

The sensory retina covers the inner portion of the posterior two-thirds of the wall of the globe. It is a thin structure which in the living state is transparent and of a purplish-red color due to the visual purple of the rods. The retina is a multilayered sheet of neural tissue closely applied to a single layer of pigmented epithelial cells. The sensory retina is attached only at two regions; the anterior extremity is firmly bound to the pigment epithelium at its dentate termination, the ora serrata. Posteriorly, the optic nerve fixes the retina to the wall of the globe. This potential space between the sensory retina and the retinal pigment epithelium may fill with fluid and result in retinal detachment. The fluid usually comes from the vitreous and enters the subretinal space through a tear or hole in the retina (rhegmatogenous or tear-induced retinal detachment). Less commonly, fluid may leak from blood vessels and cause an exudative retinal detachment.

The retina is 0.1 mm thick at the ora serrata and 0.23 mm thick at the posterior pole. It is thinnest at the fovea centralis, the center of the macula. The fovea may suffer irreparable damage in a brief period of separation from its only blood supply, the underlying choriocapillaris, during retinal detachment.

Composition of the Sensory Retina

The sensory retina is composed of highly organized tissue consisting of nine histologic layers resting on pigment epithelium. From the outside of the eye the layers are in the following order: (1) the layer of rods and cones; (2) the external limiting membrane; (3) the outer nuclear layer; (4) the outer plexiform layer; (5) the inner nuclear layer; (6) the inner plexiform layer; (7) the ganglion cell layer; (8) the nerve fiber layer; (9) the internal limiting membrane.

Retinal Pigment Epithelium

The pigment epithelium consists of a single layer of cells which is firmly attached to the basal lamina of the choroid and loosely attached to the rods and cones. Microvilli form the apical parts of the cells and project among the rods and cones. The pigment granules consist of melanoprotein and lipofuscin.

The functions of the pigment epithelium are not completely understood. It produces pigment which acts to absorb light. Also, it has phagocytic functions and provides mechanical support to the processes of the photoreceptors.

Photoreceptor Cells of the Retina

The rods and cones, the light receptive elements of the retina, transform physical energy into nerve impulses. Transformation of light energy depends on alteration of visual pigments contained in the rods or cones.

Rhodopsin, a derivative of vitamin A, is the visual pigment of the rods. Rhodopsin is composed of retinal (vitamin A aldehyde) bound to a large protein, opsin. The retinal is the same in both rods and cones but the protein moiety differs. Light isomerizes the retinal from the 11-*cis* to an all-*trans* shape, releasing the retinal from the opsin. The chemical sequence following the isomerization of retinal produces a transient excitation of the receptor which is propagated along its axon. The bipolar cell transmits this information to the inner plexiform layer where it is modified through connections between amacrine, bipolar, and ganglion cells. The ganglion cells pass this analyzed information to the brain (*4*).

Toxins Affecting the Retina

Chloroquine. A definite association of retinopathy with chloroquine was made in 1959 (*5*), and subsequently more than 200 cases have been reported. There is a definite relationship with retinopathy and daily and total doses. Most cases of chloroquine retinopathy occur at a dosage level of 500 mg per day or more. A total dosage of 100 g can be retinopathic. The risk, however, significantly increases as the total dose becomes greater than 300 g (*6*).

Disturbance of the macula is almost always present in chloroquine retinopathy. Initially it may present as edema followed by development of pigmentary changes. The latter may vary from an extremely subtle abnormality to one having a "bull's eye" appearance to complete loss of macular pigment.

Chloroquine-induced retinal damage occurs primarily at the level of the pigment epithelium and rods and cones. There is loss of the rods and cones with migration of pigment from the adjacent epithelium into the inner retinal layer. Electron microscopic examination has shown additional abnormalities of the ganglion cells consisting of membranous cytoplasmic bodies and clusters of curvilinear tubules (*7*).

The visual prognosis is guarded when a retinopathy secondary to chloroquine develops. In a significant number of cases there is a progressive loss of visual acuity which can continue for several years following the discontinuation of chloroquine (*8*). Hydroxychloroquine causes a retinopathy similar to that of chloroquine (*9*). Visual field testing with a red test object has been recommended as the most reliable indicator of impending retinal toxicity to chloroquine in man (*10*).

Thioridazine. Thioridazine is one of the most commonly used phenothiazines in the treatment of serious psychiatric illness. Its principal ocular toxicity is retinopathy. There is a 75% incidence of retinopathy at a daily dosage level of 1200-2100 mg/day (*11*). A pigmentary mottling of the macula and posterior pole can be observed associated with decreased visual acuity and pericentral and central scotomata (*12*). Improvement in visual acuity is common after the drug is stopped.

Quinine. Quinine may cause ocular damage when taken in large doses. It affects the ganglion cells and nerve fibers resulting in degeneration.

Aqueous Humor

Aqueous humor, contained in the anterior compartment of the eye, is produced by the ciliary body and drained through outflow channels into the extraocular venous system. The aqueous circulation is a vital element in the maintenance of normal intraocular pressure (IOP) and in the supply of nutrients to avascular transparent ocular media, the lens and the cornea. Circulatory disturbance of the aqueous humor leads to abnormal elevation of the IOP, a condition known as glaucoma, which can ultimately lead to blindness.

Aqueous Humor Formation

Formation of aqueous humor is dependent upon the interaction of complex mechanisms within the ciliary body, such as blood flow, transcapillary exchange and transport processes in the ciliary epithelium. Maintenance of the IOP is controlled by a delicate equilibration of aqueous humor formation and outflow; aqueous formation and ocular blood flow are in turn influenced by the IOP (*13*).

Formation of Aqueous by the Ciliary Epithelium

The ciliary epithelium is composed of two layers, the outer pigmented and the inner nonpigmented epithelium. ATPase is responsible for sodium transport to the posterior chamber and for aqueous formation. It is found predominantly in the nonpigmented epithelium (*14*).

Chemical analysis of the aqueous humor indicates that this fluid is not a simple dialysate or ultrafiltrate of the blood plasma (*15*). Continuous aqueous production by the ciliary processes requires an active mechanism demanding metabolic energy. Aqueous humor formation is thereby thought to be due to a secretory mechanism in the ciliary epithelium together with ultrafiltration from the capillaries in the ciliary processes. The secretory mechanism involves active transport of electrolytes, coupled fluid transport, and carbonic anhydrase action.

Aqueous Humor Circulation and Drainage

The anterior ocular compartment containing aqueous humor consists of two chambers of unequal volume, the anterior and posterior chambers (Fig. 2). Communication between the anterior and posterior chambers occurs through the pupil. The aqueous humor is secreted by the ciliary processes into the posterior chamber from which it flows into the anterior chamber. It is drained from the anterior chamber into the extraocular venous systems through porous tissue in the iridocorneal angle and Schlemm's canal (in man and primates) or venous plexus (in lower mammals). This drainage system is called the conventional drainage route. In man and primates, some aqueous leaves the eye by bulk flow via the ciliary body, suprachoroid, and sclera to the episcleral space; this route is called the uveoscleral drainage route or unconventional route.

Effect of Corticosteroids on Intraocular Pressure

Topical application of corticosteroids to normal human eyes occasionally results in IOP elevation accompanied by an increase in the outflow resistance (*16*). After discontinuation of steroids, the IOP usually returns to normal levels but may remain irreversibly elevated. The hypertensive IOP response to steroids appears to be genetically determined (*17*).

The Lens

The lens is a biconvex, transparent, and avascular structure. It is suspended behind the iris by the zonule of Zinn, a suspensory ligament, which connects it with the ciliary body. The lens capsule is a semipermeable membrane which will admit water and electrolytes. A subcapsular epithelium is present anteriorly. Subepithelial lamellar fibers are continuously produced throughout life. The nucleus and cortex of the lens are made up of long concentric lamellae each of which contains a flattened nucleus in the peripheral portion of the lens near the equator.

Function of the Lens

The lens acts to focus light rays upon the retina. To focus light from a near object, the ciliary muscle contracts, pulling the choroid forward and releasing the tension on the zonules. The elastic lens capsule then molds the pliable lens into a more spherical shape with greater refractive power. This process is known as accommodation. With age, the lens becomes harder and the ability to accommodate for near objects is decreased.

Composition of the Lens

The lens consists of about 65% water and about 35% protein (the highest protein content of any tissue of the body). Potassium is more concentrated in the lens than in most body tissues and ascorbic acid and glutathione are both present in the lens. It contains no nerve fibers or blood vessels; therefore, its nutrition is derived from the surrounding fluids. Mechanical injury to the lens or damage from altered nutrient concentration in the aqueous may result in cataract formation.

Cataract

A cataract is a lens opacity. Senile cataract is the most common type and is usually bilateral. Traumatic cataract, congenital cataract, and cataracts secondary to diabetes mellitus, galactosemia, other systemic diseases, and toxins are less common.

Cataract Formation. Cataractous lenses exhibit protein alteration, lens edema, vacuole formation, necrosis, and disruption of the lens fibers. Cataract formation is characterized by a reduction in oxygen uptake and an initial increase in water content followed by dehydration. Sodium and calcium content is increased while potassium, ascorbic acid, protein, and glutathione content is decreased.

Sugar Cataracts. Examples of sugar type cataracts are those produced by galactose, xylose and glucose. Galactose and xylose administered in large amounts to animals and blood glucose in excess, as in severe diabetes with persistent severe hyperglycemia, can produce cataract.

Sugars in high concentration in the aqueous humor readily enter the lens and are converted to sugar alcohols by aldose reductase (galactose to dulcitol or galactitol, glucose to sorbitol, and xylose to xylitol). The sugar alcohols accumulate in the lens and have an osmotic effect causing water to enter the lens and causing lens cells and fibers to swell and become disrupted. These changes lead to formation of cataract (*18*).

Corticosteroid Cataracts. Posterior subcapsular cataracts have been produced by a variety of glucocorticoids used medically for long periods either systemically or applied to the surface of the eye. The toxicologic mechanism of cataract induction by the corticosteroids has not been defined.

Toxic Cataracts. Many cases of toxic cataract appeared in the 1930s as a result of ingestion of

dinitrophenol, a drug taken to suppress appetite. Triparanol (MER/29) was also found to cause cataract. Echothiophate iodide, a strong miotic used in the treatment of glaucoma, has also been reported to cause cataract.

The Vitreous

The vitreous is a clear, avascular, gel-like body which comprises two-thirds of the volume and weight of the eye. It fills the space bounded by the lens, retina, and optic disc. Its gelatinous form and consistency is due to a loose syncytium of long-chain collagen molecules capable of binding large quantities of water. The vitreous is about 99% water; collagen and hyaluronic acid make up the remaining 1%.

The Visual Pathway

The visual pathway from the retina may be divided into six levels: (1) the optic nerve, (2) the optic chiasm, (3) the optic tract, (4) the lateral geniculate nucleus, (5) the optic radiation and (6) the visual cortex.

Anatomy of the Optic Nerve

The optic nerve consists of about 1 million axons arising from the ganglion cells of the retina. The nerve fiber layer of the retina is comprised of these axons and they converge to form the optic nerve. The orbital portion of the nerve travels within the muscle cone to enter the bony optic foramen to gain access to the cranial cavity. The optic nerve is made up of visual fibers (80%) and afferent pupillary fibers (20%).

The Optic Chiasm

After a 10 mm intracranial course, the optic nerves from each eye join to form the optic chiasm. At the optic chiasm the nasal fibers, constituting about three-fourths of all the fibers, cross over to run in the optic tract of the opposite side.

The Optic Tract

In the optic tract, crossed nasal fibers and uncrossed temporal fibers from the chiasm are rearranged to correspond with their position in the lateral geniculate body. All of the fibers receiving impulses from the right visual field are projected to the left cerebral hemisphere; those from the left field to the right cerebral hemisphere. Each optic tract sweeps around the hypothalamus and cerebral peduncle to end in the lateral geniculate body with a smaller portion carrying pupillary impulses continuing to the pretectal area and superior colliculi.

The Lateral Geniculate Nucleus

The visual fibers synapse in the lateral geniculate body. The cell bodies of this structure give rise to the geniculocalcarine tract, the final neuron of the visual pathway.

The Optic Radiation

The geniculocalcarine tract passes through the posterior limb of the internal capsule and then fans into the optic radiation which traverses parts of the temporal and parietal lobes en route to the occipital cortex.

The Visual Cortex

Optic radiation fibers representing superior retinal quadrants terminate on the superior lip of the calcarine fissure, and those representing inferior retinal quadrants end in the inferior lip. The macula is represented in a large region posteriorly, and retinal areas close to the macula are represented more anteriorly.

Toxins Affecting the Visual Nervous System

Methanol. Methyl alcohol (wood alcohol) has long been used as an intoxicating drink either accidentally or as an adulterant of ethyl alcohol. Its metabolic product, formaldehyde, can cause marked destruction of the ganglion cells of the retina as well as degeneration of nerve fibers in the optic nerve resulting in permanent blindness.

Nutritional Amblyopia (Tobacco-Alcohol Amblyopia). Nutritional amblyopia is the preferred term for the entity sometimes referred to as tobacco-alcohol amblyopia. Persons with poor dietary habits, particularly if the diet is deficient in thiamine, may develop centrocecal scotomas that are usually of constant density. Bilateral loss of central vision is present in over 50% of patients, reducing visual acuity below 20/200. Reduction in alcohol and tobacco usage plus adequate diet and thiamine is usually effective in curing the disease.

Drugs or Toxins Causing Papilledema. Papilledema as a toxic manifestation of drugs or chemicals can occur as an accompaniment of optic neuritis or as a manifestation of elevation of intracranial pressure. The substances that have most clearly

produced papilledema by causing increase in intracranial pressure are the corticosteroids, ethylene glycol, nalidixic acid, tetracycline and vitamin A.

Drugs or Toxins Causing Optic Neuritis. The diagnosis of optic neuritis has usually been made on the basis of clinical observations of reduction of vision associated with central scotomas combined with ophthalmoscopically visible changes in the optic nerve head, particularly hyperemia with variable degrees of edema. Some of these agents are ethambutol, lead, chloramphenicol, isoniazid and digitalis.

REFERENCES

1. Warwick, R. Eugene Wolfe's Anatomy of the Eye and Orbit. W. B. Saunders Co., Philadelphia and Toronto, 1976.
2. Havener, W. H. Ocular Pharmacology. C. V. Mosby Co., St. Louis, 1978.
3. Grant, W. M. Toxicology of the Eye. Charles C Thomas, Springfield, Ill., 1974.
4. Moses, R. A. Adler's Physiology of the Eye. C. V. Mosby Co., St. Louis, 1975.
5. Hobbs, H., and Calnan, C. The ocular complications of chloroquine therapy. Lancet 1: 1207-1209 (1958).
6. Nylander, U. Ocular damage in chloroquine therapy. Acta Ophthal. 44: 335-348 (1966).
7. Ramsey, M., and Fine, B. Chloroquine toxicity in the human eye. Am. J. Ophthal. 72: 229-235 (1972).
8. Krill, A., Potts, A., and Johanson, C. Chloroquine retinopathy, investigation of discrepancy between dark adaptation and electroretinographic findings in advanced stages. Am. J. Ophthal. 71: 530-543 (1971).
9. Crews, S. Chloroquine retinopathy with recovery in early stages. Lancet 7337: 436-438 (1964).
10. Percival, S., and Behrman, J. Ophthalmological safety of chloroquine. Brit. J. Ophthal. 53: 101-109 (1969).
11. Hagopian, V., Stratton, D., and Busiek, R. Five cases of pigmentary retinopathy associated with thioridazine administration. Am. J. Psychiat., 123: 97-100 (1966).
12. Bernstein, H. N. Ocular side-effects of drugs. In: Drugs and Ocular Tissues. S. Dikstein, Ed., S. Karger, Basel, 1977.
13. Mishima, S., Masuda, K., and Tamura, T. Drugs influencing aqueous humor formation and drainage. In: Drugs and Ocular Tissues. S. Dikstein, Ed., S. Karger, Basel, 1977.
14. Cole, D. F. Localization of ouabain-sensitive adenosine triphosphatase in ciliary epithelium. Exptl. Eye Res. 3: 72-75 (1964).
15. Kinsey, V. E. The chemical composition and the osmotic pressure of the aqueous humor and plasma of the rabbit. J. Gen. Physiol. 34: 389-401 (1951).
16. Armaly, M. Effect of corticosteroids on intraocular pressure and fluid dynamics, I and II. Arch. Ophthal. 70: 482-491 (1963).
17. Becker, B., and Hahn, K. Topical corticosteroids and heredity in primary open-angle glaucoma. Am. J. Ophthal. 57: 543-551 (1964).
18. Chylack, L. T., and Kinoshita, J. H. Biochemical evaluation of a cataract induced in high glucose medium. Invest. Ophthal. 8: 401-412 (1969).