Environmental Health Perspectives
Vol. 44, pp. 31-34, 1982

Embryology of the Eye

by Richard M. Hoar*

A brief description of the basic patterns of mammalian development of the eye is presented based on events as they occur in human beings. The emphasis is not on the details of this development, but rather on its organization and timing, with a figure of comparative development providing a comparison of similar events in man, rat, mouse, and chick.

To an individual struggling to understand some basic mechanisms associated with normal embryology, the development of the eye is well worth study. Here induction has been clearly established as an essential mechanism, and one can discover examples of both primary and secondary inductive forces. Here, too, one finds examples of early developmental "steps" or events whose persistence (or absence) results in either congenital abnormalities or future "disease states." In this system one encounters examples of those unexplained "spontaneous events" which are so common in an embryologist's lexicon. An examination of the development of the eye will serve to remind us that embryogenesis is a continuum. Although discursive presentations such as this tend to emphasize the pieces rather than the puzzle, one should not lose sight of the whole when discussing its parts, for each event we shall discuss is part of an interdependent continuum which can be totally disrupted by the failure of any one of its components either to appear on time or to develop normally. Finally, the development of the eye serves to remind us that there are many instances in normal embryology in which development continues after birth and can be significantly altered by events in postnatal life. The presentation which follows is intended only as an outline of the development of the human eye. For those who wish to pursue to subject, a list of references has been supplied, and a figure of comparative development has been provided to remind you how rapidly these events occur in rodents as compared to man.

*Department of Toxicology and Pathology, Hoffmann-La Roche Inc., Nutley, New Jersey 07110.

Now let us turn out attention specifically to the development of the eye. We see the optic primordia first in man on about day 22 as bilateral evaginations of the neuroectoderm of the forebrain (prosencephalon) which still remains open as bilateral neural folds. These evaginations, the optic peduncles, continue to proliferate laterally as the forebrain closes so that at about day 27 they have become large, single-layered vesicles, the primary optic vesicles, which are continuous with the third ventricle. As they reach the surface ectoderm, these hollow balls of neuroectoderm, connected to the brain through hollow optic stalks, induce the formation of lens primordia, the lens placodes. This is the classical example generally offered as evidence for primary induction in normal development for, unless the optic vesicle reaches the surface ectoderm, no lens vesicle will develop. A groove appears on the inferior surface of each optic stalk and optic vesicle at about 29 days. This retinal (choroid or optic) fissure incorporates both mesenchyme and the hyaloid artery and vein by 33 days, vascularizing the optic stalk and the optic vesicle which itself is undergoing further structural modifications. The hollow ball (vesicle) has become indented creating the appearance of a cup with two layers, an internal and external retinal layer, separated by an intraretinal space that is still continuous through the optic stalk with the third ventricle.

The differentiation of this secondary optic vesicle continues with the fusion of the retinal layers and the disappearance of the intraretinal space except for anterior and posterior cul-de-sacs located at the ora serrata and the intraocular portion of the optic nerve, respectively. The external retinal layer becomes the pigmented layer of the retina by the sixth week and the internal layer differentiates into the neural

layer, modification of which becomes obvious by 40 days and continues through the seventh month; one can visualize the definitive retinal pattern at approximately 175 days. The changes which occur in the neural layer are similar to those seen as the brain itself develops. At about 40 days, an internal germinal epithelial or ependymal layer may be found next to the pigmented layer, still separated from it by an occasional remnant of the intraretinal space. By 130 days, the ependymal layer gives rise to an external neuroblastic layer, an internal neuroblastic layer and a ganglionic cell layer. By about 175 days, the internal neuroblastic layer has differentiated into the interneuron or bipolar cellular layer. Rudimentary neurosensory rods and cones appear during the twelfth week and continue development after birth. Thus, because of the invagination of the primary optic vesicle to form the optic cup, the neural layer of the retina is inverted and the light sensitive rods and cones are located adjacent to the pigmented epithelium so that light must cross the neural retina to reach the receptors.

In man, from day 35 to day 210 of gestation, the optic stalk has undergone a parallel modification, creating an external layer continuous with the external retinal layer, thus providing the axons from the neural retina a pathway for easy access to the brain. By about the ninth week, the hyaloid vessels are incorporated within the optic stalk and as it fills with axons, the retinal fissure fuses (sixth week); continuity with the intraretinal space and the third ventricle disappears and the hyaloid vessels become the central retinal vessels.

By turning our attention now to the anterior region of the secondary optic vesicle, we can consider the development of the iris, ciliary bodies, lens, vitreous body and aqueous chamber of the eye. As the optic vesicle doubles back on itself (invaginates) forming the optic cup and an inner and outer retinal layer, the point where the two layers meet anteriorly tends to extend over the developing lens to form a pupillary opening. These two layers in front of the lens will become the iris, a process which commences about the seventh week. The internal retinal layer (the neural layer) remains thin in this location and the external layer provides a pigmented epithelium. I wonder what determines the failure of the neural retina in this area to thicken and undergo cell division as it did on the posterior surface of the cup? Could it be the presence of the lens?

The ciliary bodies appear on the inner surface of the developing iris during the ninth week and begin secreting aqueous humor. It should be noted that this system develops from neuroectoderm and functions in a manner similar to that of the choroid plexus.

The lens itself may now be seen as a lens vesicle (hollow ball) having lost its connection to the surface ectoderm during the sixth week. The inner cells of the lens vesicle multiply and extend primary lens fibers towards the opposite external cells, gradually occluding the lumen of the lens vesicle. By the seventh week, the fibers extend between the walls of the vesicle, filling it; forming the nucleus of the lens. New fibers arise throughout life from cells positioned in the equatorial plane. The equatorial plane is located near the origin of the aqueous humor which will become its principal source of nutrients after the hyaloid vessels disappear. Loose bundles of fibers derived from the vitreous framework appear between the ciliary body and the lens forming the suspensory ligament (zonule of Zinn) of the lens.

Posterior to the lens, in an area surrounded by the developing retina, in the lentiretinal space, the primary vitreous body is developing from mesenchyme that infiltrated through the retinal fissure. The retinal fissure begins to close at about 37 days, creating a circular optic cup with no inferior gap, and completely encloses the primary vitreous body by about 47 days. The primary vitreous body and the rapidly developing lens are both supplied by the hyaloid artery. However, the intravesicular vessels degenerate, and the mesenchyme of the primary vitreous body becomes an acellular jelly, the secondary vitreous body, which fills the optic cup behind the lens—a process which is completed about the ninth week. The hyaloid vessels within the optic stalk do not degenerate, but remain as the central retinal artery and vein.

The aqueous chamber of the eye develops during the seventh week between the cornea and iris (anterior chamber) and between the iris and the lens (posterior chamber) under the influence of the lens. The anterior chamber develops as a space in the mesenchyme located between the developing lens and the overlying ectoderm. This space separates the mesenchyme into two layers, a thick outer layer which will become the cornea and a spidery combination of mesenchyme and developing choroid (the iridopupillary membrane) which covers the pupil but regresses and disappears before birth. The fluid medium of the two chambers, the aqueous humor, is produced by the ciliary body and is drained by a large vessel, the canal of Schlemm, located in the iridocorneoscleral angle, the drainage angle or angular sinus.

This complex structure which has formed between the third and ninth weeks of gestation needs protective layers and muscles. Responding to the

inductive forces of the pigmented outer layer of the optic cup during the sixth to seventh week, the surrounding mesenchyme forms a vascularized pigmented layer, the choroid (which is analagous to the pia-arachnoid layer of the brain) and a tough white, collagenous sclera which surrounds the optic cup with tissue that is continuous with the dura mater of the brain. The cornea which is continuous with the sclera is created from mesenchyme (vide supra) which invades between the developing lens and the surface ectoderm and is covered with a multilayered epthelium anteriorly and a single-layered "endothelium" posteriorly. Under the influence of the lens, the cornea and the covering ectoderm (epithelium) become clear. The extrinsic ocular muscles and the ciliary muscles which control convergence of the lens are established *in situ* from mesenchyme between the fourth to tenth week. The dilator and constrictor muscles of the iris are of neuroectodermal origin, for they develop *in situ* from the pigmented layer of the iris, which was the external retinal layer.

The eyelids appear during the sixth week as folds of ectodermal tissue with a mesenchymal core. They grow until they meet and fuse, during the ninth week, obliterating the palpebral opening, and they remain joined until about the seventh month. Upon fusion of the eyelids, a closed conjunctival sac is formed between the eyelids and the cornea. The lacrimal gland primordia begins to develop from the surface ectoderm in the upper lateral part (superior fornix) of the conjunctival sac during the seventh week. The morphogenesis of the eyelids and lacrimal apparatus is said to be independent of that of the eye, but there is no question that the "wetting action" of the eyelid is absolutely essential to the integrity of the cornea.

Having considered the development of the eye during its major period of organogenesis, between the third and ninth week of gestation, one should remember that development of the eye continues into postnatal life. The fovea centralis of the retina is not differentiated until 4 months after birth. The cones which, after appearing during the twelfth week, remain poorly developed until about 4 months after birth. The dilator pupillae muscle continues its development until the fifth year of life, and the lens keeps adding fibers to its circumference throughout life at a pace which decreases with age.

I believe that a discussion of this vital system should include commentary on the origin of a few representative birth defects. Coloboma iridis is the result of failure of the retinal fissure to completely close during the seventh week. We now know why a gap in the iris may be indicative of damage to such structures as the ciliary body, the retina, or the optic nerve. A persistent iridopupillary membrane, on the other hand, need not be accompanied by a plethora of other defects, for its development appears to be an isolated event. Although the pigmented epithelium of the retina, the internal retinal layer, becomes firmly attached to the surrounding choroid layer, the retina itself may be separated from the pigmented layer along the lines of that fusion plane which was the intraretinal space. This separation may be assisted by the presence of a persistent hyaloid artery or vitreoretinal adhesions.

DEVELOPMENT OF THE EYE

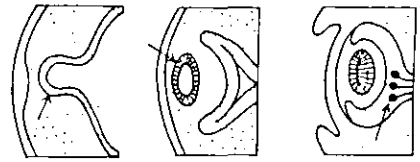

	Optic Vesicle Forming	Lens Separated	Optic Nerve Fibers Present
Man	24	35	48
Rat	10.5	12.5	14
Mouse	9.5	11.5	13
Chick	1.3	2.5	4

FIGURE 1. Selected developmental stages of the ocular system accompanied by the age in days on which a particular event occurs in the rat, mouse and man based on fertilization age and in the chick based on incubation age. Modified from Monie (*8*, *9*).

Do not suppose that this presentation has more than scratched the surface of the intricacies of the developing eye. However, I hope it has provided you with the stimulus necessary to pursue your investigation of its complexities. To further your efforts, a figure of ocular development has been provided (Fig. 1) comparing the approximate timing of a particular event in the rat, mouse, and man, giving the age in days based on fertilization age, and in the chick according to its incubation age, also in days. In addition, some general references (*1-11*), which should aid your study of the development of the eye, are appended.

REFERENCES

1. Duke-Elder, S., and Cook, C. Embryology. In: System of Ophthalmology, Vol. III. Normal and Abnormal Development. S. Duke-Elder, Ed., C. V. Mosby, St. Louis, 1963.

2. Mann, I. The Development of the Human Eye. Grune and Stratton, Inc., New York, 1950.
3. O'Rahilly, R. The early development of the eye in stage human embryos. Contrib. Embryol. 38: 1-36 (1966).
4. Fine, B. S., and Yanoff, M. Ocular Histology, a Text and Atlas. Harper and Row, Hagerstown, Md., 1979.
5. Tuchmann-Duplessis, H., Auroux, M., and Haegel, P. Illustrated Human Embryology, Vol. 3. Nervous System and Endocrine Glands. Springer-Verlag, New York, 1974, pp. 98-105.
6. Langman, J. Medical Embryology. Williams and Wilkins, Baltimore, 3rd Ed., 1974, pp. 368-377.
7. Moore, K. L. The Developing Human. W. B. Saunders, Philadelphia, 1973, pp. 335-342.
8. Monie, I. W. Comparative development of rat, chick and human embryos. In: Teratologic Workshop Manual (Supplement). Pharmaceutical Manufacturers Association, Berkeley, Calif., 1962.
9. Otis, E. M., and Brent, R. Equivalent ages in mouse and human embryos. Anat. Rec. 120: 33-63 (1954).
10. Shepard, T. H. Catalogue of Teratogenic Agents. Johns Hopkins University Press, Baltimore and London, 3rd ed. 1980.
11. Hoar, R. M. Comparative developmental aspects of selected organ systems. II. Gastrointestinal and urogenital systems. Environ. Health Perspect. 18: 61-66 (1976).