Environmental Health Perspectives
Vol. 66, pp. 31-35, 1986

Animal Model of Grain Worker's Lung

by Nate Stepner,* Irvin Broder,* and Reuben Baumal*

We examined the light microscopic changes in the lungs of rabbits exposed to grain dust for variable periods of time, to determine whether an animal model of grain worker's lung could be developed. Experimental animals were exposed to grain dust at a concentration of 20 mg/m^3 for 7 hr/day, 5 days/week, for up to 6 months. The lungs of these rabbits demonstrated a granulomatous interstitial pneumonitis associated with exudation of mononuclear cells into the alveoli and conducting airways. These changes appeared within 5 days of the onset of exposure and reached a peak at 3 weeks but were sustained through the longest exposure interval. No abnormalities were observed in the lungs of control rabbits. These results show three points of consistency with those obtained in epidemiologic studies of grain elevator workers. First, the rapid appearance of the experimental changes suggests that the mechanism of tissue injury may not be immunologic. Second, the occurrence of the histopathologic alterations in the interstitium, alveoli, and airways corresponds with the combined restrictive and obstructive ventilatory defect described in the human epidemiologic studies. Third, the absence of lung fibrosis in rabbits exposed to dust for 6 months suggests that the pneumonitis is reversible. Thus this experimental model shows promise of helping to clarify the nature and mechanism of the adverse pulmonary effects of grain dust.

Introduction

A number of epidemiologic studies have shown that employment as a grain elevator worker is associated with a variable increase in respiratory symptoms and an adverse effect on pulmonary function (*1–5*). The pulmonary function changes are both acute and chronic and show exposure–response relationships with the level of respirable dust (*6*). The respiratory symptoms and pulmonary function changes develop within the initial 3 months of employment (*7*) and improve over a 2-month period of lay-off (*8*).

There have been occasional reports of grain workers who were allergic to grain dust (*9*). However, allergy or hypersensitivity would not appear to explain the collective abnormalities detected in epidemiologic studies (*10,11*). On the other hand, there have been two reports of a generalized increase in serum α-1-antitrypsin levels in grain elevator workers (*11,12*). This observation, together with the apparent absence of an immunologic mechanism, has been interpreted as suggesting that the pulmonary abnormalities that occur in this occupational group may be due to a nonimmunologic inflammatory process (*11*).

Grain elevator dust and grain-dust extracts have been shown both to activate complement (*13,14*) and to form a nonimmunologic precipitate with human IgG (*14*). These properties suggest the basis for a possible nonimmunologic inflammatory process which may be activated when grain dust is inhaled into the lung.

An animal model would provide the potential to characterize further the nature and mechanism of the adverse pulmonary effects of grain dust. Mice exposed to 1.2–5.4 g/m^3 of grain dust for 8–24 hr/day, 5 days/week for up to 4 months have been reported to develop an increased number of macrophages in their airways (*15*). However, rats exposed to 60 mg/m^3 of grain dust for 2 hr/day for up to 2 months, demonstrated a granulomatous interstitial pneumonitis (*16*). The concentration of grain dust used in these studies would be considered extreme by usual industry standards (*6,10,17*).

The following report describes an animal model of grain worker's lung in rabbits exposed to grain dust under conditions that more closely approximate those in the contemporary grain industry. Light microscopic examination of the lungs of exposed rabbits shows an inflammatory process in both the airways, alveoli, and interstitium that is well developed after only 5 days, reaches a peak at 3 weeks, and is still present at 6 months. The results obtained in this model show a number of features which parallel those reported in epidemiologic studies of grain elevator workers.

Methods

Rabbits

New Zealand White rabbits weighing 2 kg were obtained in a single batch from one supplier. The controls were housed continuously in the animal quarters, while the experimentals were moved into a separate room on the days when they were exposed to grain dust.

*The Gage Research Institute, Department of Medicine and the Department of Pathology, The Hospital for Sick Children, University of Toronto, Toronto, Ontario, Canada M5T 1R4.

Dust Exposure Chambers

Two exposure chambers were used which consisted of a one cubic meter working area supplied with grain dust from a fluidized bed. The chamber has been described in detail previously (*18*). The dust delivery rate was adjusted to maintain a dust level of about 20 mg/m^3 in the chambers.

Grain Dust

A single batch of grain dust was used in these studies. This was obtained from the air exhaust collectors of two large grain elevators in Thunder Bay, Canada (Saskatchewan Wheat Pool 4 and Pool 7). These elevators process several species of grain, often simultaneously; they handle wheat predominantly and to a lesser extent oats, rye, and barley. The stock dust was thoroughly mixed and stored at 4°C. Prior to use, the largest dust particles were removed on a 65 mesh sieve.

The level of grain dust in each chamber was measured using a Bendix 44 pump and a Millipore filter cassette holding a 37-mm polytetrafluoroethylene filter (Millipore, Flouropore, 1.0-μm pore size). The filters were desiccated and weighed in a standard manner before and after use (*6*). The chambers were monitored during most days when the rabbits were exposed, and a time weighted average was obtained covering the full 7-hr period. The airborne dust in the chambers was further characterized on several occasions using an Andersen cascade impactor (*19*).

Experimental Design

A total of 47 rabbits were employed, of which 23 were controls and 24 experimentals. Both groups were subdivided into five subgroups containing four or more animals each. Animals in excess of four per subgroup were included to allow for premature deaths. The experimental animals were exposed to 20 mg/m^3 of grain dust for 7 hr/day, 5 days/week, for a duration of 1, 3, 6, 12, or 24 weeks. Exposures were staggered so that all rabbits were approximately the same age at the time of sacrifice. Four control animals were sacrificed on each occasion that a subgroup of experimental rabbits reached the end of their exposure period. This study was approved by the Animal Care Committee of the University of Toronto.

Histopathology

The rabbits were euthanized with an overdose of sodium nembutol. The trachea was ligated and a catheter tied in proximally that was connected to a water manometer. Air was injected into the trachea to maintain a pressure of 20 cm H_2O. The chest cavity was opened and catheters tied into the right atrium and aorta. The pulmonary artery was perfused free of blood with cold heparinized saline and then with cold universal fixative. The trachea, right atrium, and aorta were tied off, and the heart and lungs removed and left in universal fixative overnight, and then in 10% buffered formalin. Tissue sections were prepared for light microscopy from lungs of both the control and experimental rabbits. These were obtained from blocks which contained both central and peripheral portions of lung in a single section. The sections were stained using hematoxylin and eosin.

Results

Chamber Conditions

The average monthly temperature in the chambers ranged from 16 to 24°C, with a daily minimum of 10 and maximum of 27 (Table 1). The average monthly total dust concentration was similar in both chambers and approximated 20 mg/m^3. The lowest dust concentration on any day was 15.4 and the highest 29.3. The dust inside the chamber was analyzed using an Andersen cascade impactor on three occasions at monthly intervals. About 45% of the particles were greater than 9 μm in size while the majority of the remainder were between 3.3 and 5.8 μm and a small proportion were 1.1 μm or smaller (Table 2).

Rabbit Weights and Survival

The initial weights of the experimental and control rabbits were comparable (Table 3). Both groups gained to about the same degree and approximately doubled their weight over the experimental period. A total of three animals died spontaneously during the course of the experiment, all of which were controls.

Histopathology

Sections of lung from the control and experimental rabbits were examined by light microscopy. All experimental animals demonstrated histopathologic changes after 5 days of exposure to grain dust. The extent of the tissue involvement reached a peak at 3 weeks and was sustained through the longest exposure interval of 24 weeks. The changes consisted of an interstitial pneumonitis that extended into the walls of some blood vessels and airways (Fig. 1). The interstitial pneumonitis was patchy but widespread and was characterized by vascular congestion, edema, and a cellular infiltrate composed predominantly of mononuclear and giant cells often forming granulomata. Neutrophils and eosinophils also were evident, more so within the initial 3 to 6 weeks. In addition, there was extensive cellular exudation into the alveolar spaces and conducting airways. The cellular exudate present in the airways was comparable to the tissue infiltrate. The lungs of the control rabbits showed no abnormalities (Fig. 2).

Additional Studies

In additional studies, the histopathologic changes in the lungs have been examined in greater detail, including the use of scanning and transmission electron microscopy.

Table 1. Temperature and dust concentrations in exposure chambers, given as monthly averages and daily minima and maxima.

	Month						
	1	2	3	4	5	6	7
Temperature, C°							
No.	4	20	23	20	21	20	23
Average	24	24	22	19	18	16	17
St. dev.	0	1	2	3	2	3	3
Minimum	23	21	18	13	14	12	10
Maximum	24	26	27	23	22	24	22
Total dust, chamber 1, mg/m³							
No.	4	15	17	11	10	10	13
Average	20.5	20.5	20.2	21.3	22.3	20.8	19.7
St. dev.	1.3	2.7	1.6	3.1	3.0	1.3	1.0
Minimum	18.7	15.4	18.2	16.3	19.7	19.3	18.0
Maximum	21.6	26.7	23.0	26.7	27.8	22.8	21.5
Total dust, chamber 2, mg/m³							
No.	3	4	20	12	16	2	0
Average	20.7	20.1	19.9	22.1	21.4	20.5	
St. dev.	1.1	1.4	2.7	2.0	2.3	0.1	
Minimum	19.5	18.7	17.1	20.7	19.3	20.4	
Maximum	21.8	22.0	28.9	27.0	29.3	20.5	

Table 2. Size distribution of chamber dust measured with an Andersen cascade impactor on three occasions.

Stage no.	Particle size range (μm)	% of total dust		
		Time 1	Time 2	Time 3
1	>9	48.1	50.4	35.7
2	5.8–9.0	6.8	8.1	12.7
3	4.7–5.8	15.3	15.5	19.1
4	3.3–4.7	14.9	14.1	18.7
5	2.1–3.3	11.4	8.8	9.9
6	1.1–2.1	3.5	3.2	3.3
7	0.7–1.1	—	—	0.6
8	0.4–0.7	—	—	—

Also, the pulmonary function of the control and experimental rabbits has been measured at the beginning and end of the study period. Further, bronchoalveolar lavage has been performed at the end of the experiment, and the cells obtained have been characterized both morphologically and functionally by their phagocytic activity and migration out of capillary tubes. These results will be published separately.

Discussion

The daily and weekly exposure intervals utilized in the foregoing study were selected to represent those of terminal grain elevator workers. The concentration of grain dust employed was twofold greater than the federally regulated level in Canada (*20*), but equal or higher levels are not infrequently encountered (*10,17*). The size distribution of the grain dust preparation employed, indicated that approximately 50% of the particles were capable of gaining access to the pulmonary air space (Table 2).

The histopathologic changes seen in the lungs of the exposed rabbits were characterized by an interstitial granulomatous pneumonitis. This was similar to a type 4 reaction (*21*) and also to a hypersensitivity pneumonitis (*22*), but the rapidity of onset seems to weigh strongly against the involvement of an immunological mechanism. There was no indication even after 5 days of exposure of a predominantly eosinophilic response suggestive of a type 1 allergic reaction (*23*). Also, the acute inflammation and hemorrhagic necrosis of a type 3 reaction was not seen at any time point (*24*).

We and others have hypothesized that the adverse pulmonary effects of inhaled grain dust may be due to the known complement activating properties of this material (*11,25*). Nevertheless, the histopathologic changes seen in our model did not resemble the acute changes described when a complement derived chemotactic factor has been instilled intratracheally in rabbits (*26*). This difference does not necessarily exclude the possible role of complement in the response to grain dust, since a chronic, diffuse effect of low levels of complement activation may

Table 3. Rabbit numbers, weight, and survival.

Exposure, wk	No. of rabbits starting		Body weight, kg				No. of rabbits finishing	
			Initial		Final			
	Exptl	Control	Exptl	Control	Exptl	Control	Exptl	Control
1	4	4	2.0	2.0	4.8	4.8	4	4
3	4	5	2.2	2.0	4.0	3.9	4	4
6	5	5	1.9	2.0	4.1	4.1	5	4
12	5	5	2.1	1.9	4.0	4.1	5	4
24	6	4	2.0	2.2	4.1	4.7	6	4

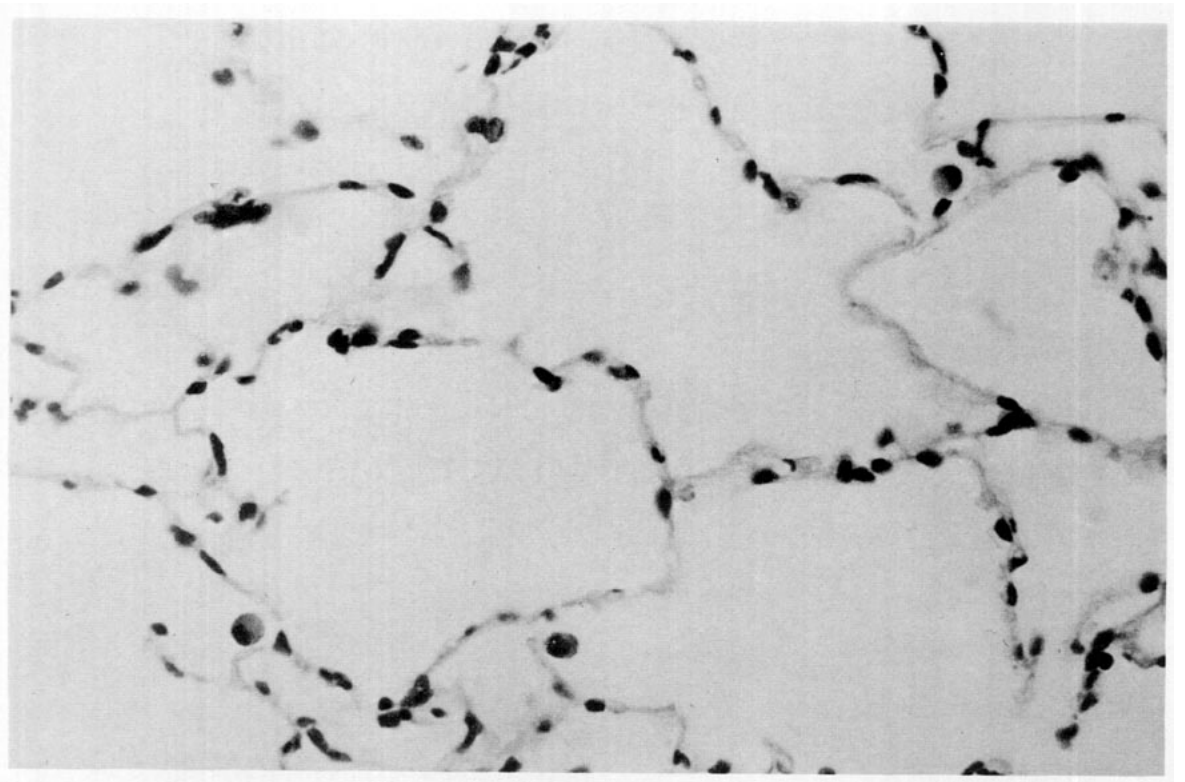

FIGURE 1. Light microscopy at magnification of 320× of lung section obtained from rabbit exposed to grain dust for 3 weeks.

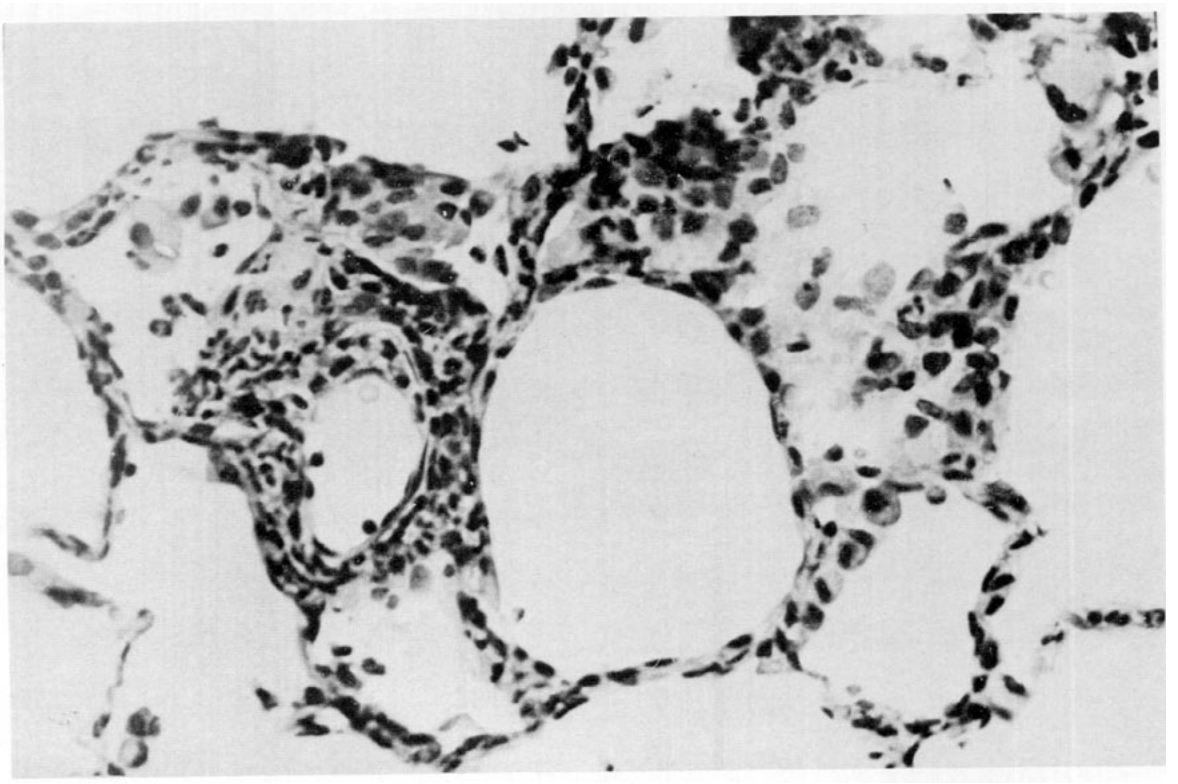

FIGURE 2. Light microscopy at magnification of 320× of lung section obtained from control rabbit.

differ from that of a single instillation of a large bolus. The response to grain dust may be conditioned additionally by the simultaneous presence of particulates. However, our results cannot be entirely explained on this basis, since the effect of particulates alone tends to be manifested by macrophage exudation into the air spaces and sometimes by the evolution of fibrosis (*27*).

The morphology of the histopathologic lung changes in our exposed rabbits was indicative of an inflammatory response in both the pulmonary airways and the interstitium. This is consistent with our epidemiologic findings in grain elevator workers, which showed pulmonary function changes suggestive of both an obstructive and restrictive ventilatory defect (*6*).

The experimental pneumonitis observed in our rabbits was not associated with obvious fibrosis by light microscopy. However, examination of sections by polarized light or using the picrosirius stain showed a small increase in the amount of fibrous tissue in some alveolar septae. This slight increase in fibrous tissue would be consistent with our demonstration that the adverse effects of chronic grain dust exposure in humans are at least partially reversible after a period of absence from exposure (*8*).

The consistency of our findings in rabbits and humans chronically exposed to grain dust suggests that the experimental model has the potential to provide clinically meaningful information about the nature and mechanism of the adverse pulmonary effects of grain dust.

This work was supported by grants from Physicians' Services Incorporated Foundation and the Ontario Thoracic Society.

REFERENCES

1. Broder, I., Mintz, S., Hutcheon, M., Corey, P., Silverman, F., Davies, G., Leznoff, A., and Peress, L. Comparison of respiratory variables in grain elevator workers and civic outside workers of Thunder Bay, Canada. Am. Rev. Resp. Dis. 119: 193–203 (1979).
2. Chan-Yeung, M., Schulzer, M., MacLean, L., Dorken, E., and Grzybowski, S. Epidemiologic health survey of grain elevator workers in British Columbia. Am. Rev. Resp. Dis. 121: 329–338 (1980).
3. Becklake, M. R., Jodoin, G., Lefort, L., Rose, B., Mandl, M., and Frazer, R. G. A respiratory health study of grainhandlers in St. Lawrence River Ports. In: Occupational Pulmonary Disease—Focus on Grain Dust and Health. (J. Dosman and D. Cotton, Eds.), Academic Press, New York, 1980, pp. 239–256.
4. Cotton, D. J., Graham, B. L., Li, K. Y. R., Froh, F., Barnett, G. D., and Dosman, J. A. Effects of grain dust exposure and smoking on respiratory symptoms and lung function. J. Occup. Med. 25: 131–141 (1983).
5. DoPico, G. A., Reddan, W., Tsiatis, A., Peters, M. E., and Rankin, J. Epidemiologic study of clinical and physiologic parameters in grain handlers of northern United States. Am. Rev. Resp. Dis. 130: 759–765 (1984).
6. Corey, P., Hutcheon, M., Broder, I., and Mintz, S. Grain elevator workers show work-related pulmonary function changes and dose-effect relationships with dust exposure. Brit. J. Ind. Med. 39: 330–337 (1982).
7. Broder, I., Hutcheon, M. A., Mintz, S., Davies, G., Leznoff, A., Thomas, P., and Corey, P. Changes in respiratory variables of grain handlers and civic workers during their initial months of employment. Brit. J. Ind. Med. 41: 94–99 (1984)..
8. Broder, I., Mintz, S., Hutcheon, M. A., Corey, P. N., and Kuzyk, J. Effect of layoff and rehire on respiratory variables of grain elevator workers. Am. Rev. Resp. Dis. 122: 601–608 (1980)..
9. Warren, P., Cherniack, R. M., and Tse, K. S. Hypersensitivity reactions to grain dust. J. Allergy Clin. Immunol. 53: 139–149 (1974).
10. DoPico, G. A., Reddan, W., Anderson, S., Flaherty, D., and Smalley, E. Acute effects of grain dust exposure during a work shift.. Am. Rev. Res. Dis. 128: 399–404 (1983).
11. Broder, I., Davies, G., Hutcheon, M., Leznoff, A., Mintz, S., Thomas, P., and Corey, P. Variables of pulmonary allergy and inflammation in grain elevator workers. J. Occup. Med. 25: 43–47 (1983)..
12. Ashley, M. J., Corey, P., and Chan-Yeung, M. Smoking, dust exposure, and serum alpha-1-antitrypsin. Am. Rev. Resp. Dis. 121: 783–788 (1980).
13. Olenchock, S. A., Mull, J. C., Major, P. C., Peach, M. J., III, Gladish, M. E., and Taylor, G. *In vitro* activation of the alternative pathway of complement by settled grain dust. J. Allergy Clin. Immunol. 65: 295–300 (1978).
14. Broder, I., and McAvoy, D. Characterization of precipitation reaction between grain dust and normal human serum and comparison of reactive and nonreactive grain handlers. Clin. Immunol. Immunopathol. 21: 141–153 (1981).
15. Armanious, M., Cotton, D., Wright, J., Dosman, J., and Carr, I. Grain dust and alveolar macrophages: an experimental study of the effects of grain dust on the mouse lung. J. Pathol. 136: 265–272 (1982).
16. Friborsky, V., Ulrich., L, Tesik, L., and Malik, E. Morphological changes of rat lung after exposure to plant dust. Acta Morphol. Acad. Sci. Hung. 20: 191–197 (1972).
17. Chan-Yeung, M., Schulzer, M., MacLean, L., Dorken, E., Tan, F., Lam, S., Enarson, D., and Grzybowski, S. A follow-up study of the grain elevator workers in the port of Vancouver. Arch. Environ. Health 36: 75–81 (1981).
18. Nelson, H. M., Rajhans, G. S., Morton, S., and Brown, J. R. Silica flour exposures in Ontario. Am. Ind. Hyg. Assoc. J. 39: 261–269 (1978).
19. Rajhans, G. S. Inertial and gravitational collectors. In: Air Sampling Instruments for Evaluation of Atmospheric Contaminants, Fifth Ed. American Conference of Governmental Industrial Hygienists, 1978, pp. 1–21.
20. Labour Canada, 1978. Guidelines for Environmental and Medical Surveillance Programs in the Grain Industry. Occupational Safety and Health Branch, January 26, 1978 (file No. 895-7-11).
21. Hay, J. B. Delayed (cellular) hypersensitivity. In: Inflammation, Immunity and Hypersensitivity, Second Ed. (H. Z. Movat, Ed.), Harper & Row, Maryland, 1979, pp. 271–318.
22. Roberts, R. C., and Moore, V. L. Immunopathogenesis of hypersensitivity pneumonitis. Am. Rev. Resp. Dis. 116: 1075–1090 (1977).
23. Baumal, R., Hooi, C., McAvoy, D., and Broder, I. Time course of morphometric changes after acute allergic bronchoconstriction in the guinea pig. Int. Archs. Allergy Appl. Immun. 71: 131–136 (1983).
24. Kaplan, R. L., Schocket, A. L., King, T. E., Maulitz, R. M., Good, J. T., Jr., Stanford, R. E., and Sahn, S. A. A model of immune complex-mediated pleuropulmonary injury. Am. J. Pathol. 100: 115–128 (1980).
25. Olenchock, S. A., and Major, P. C. Immunological studies of grain dust. J. Environ. Pathol. Toxicol. 2: 9–22 (1979).
26. Shaw, J. O., Henson, P. M., Henson, J., and Webster, R. O. Lung inflammation induced by complement-derived chemotactic fragments in the alveolus. Lab. Invest. 42: 547–558 (1980).
27. Gross, P., deTreville, R. T. P., Cralley, L. J., Granquist, W. T., and Pundsack, F. L. The pulmonary response to fibrous dusts of diverse compositions. Am. Ind. Hyg. Assoc. J. 31: 125–132 (1970).