Environmental Health Perspectives
Vol. 71, pp. 139-146, 1987

Normal Versus Abnormal Structure: Considerations in Morphologic Responses of Teleosts to Pollutants

by David E. Hinton,*† R. Clark Lantz,* James A. Hampton,*‡ Patricia R. McCuskey,* and Robert S. McCuskey*

Consideration of newer more quantitative morphologic approaches to the study of aquatic pollutants can provide opportunity for collaborative/integrated studies with other subdisciplines in toxicology. Current commonly employed morphologic approaches result largely in subjective findings difficult to analyze statistically and often are directed at levels of structural organization inconsistent with biochemical and physiological approaches. We review some of the methods and approaches available for correlated structure/function studies and present examples from normal and altered skin, gill, and liver of teleosts.

Introduction

Truly an interface sphere of science, toxicology is composed of collective interaction of pharmacologists, chemists (analytical and biochemical), physiologists, microbiologists including immunologists, and morphologists (pathologists and anatomists/cell biologists). When we consider aquatic toxicology, the interaction also includes at least fisheries biologists. Perhaps the single most important factor limiting the potential integration of morphologists with the more quantitatively oriented disciplines has been the subjective nature of the micrograph (*1*). However, methods are available that permit the acquisition of quantitative, more objective data directly from the microscopic image or from micrographs (*2–5*). Applied to pathology and toxicity studies of mammalian lung, liver, adrenal, and intramural digestive system, the applicability of this approach has been demonstrated repeatedly. With the entry of small computers to most laboratories and the ready availability of software programs for morphometry, the time and ease with which these data can be collected have made the technique feasible for integrative toxicologic investigations. From these investigations, not only have quantitative data been realized but a systematic approach to structural investigation at progressive levels of organization (organ, tissue, cell, and organelle) has arisen.

Despite the above, relatively little usage of these potentially powerful tools has been made in aquatic toxicology. In this paper we review morphometric principles and findings from mammalian and teleost studies which are revelant to analysis of normal and toxicant-altered teleost anatomy. In addition, by using examples from ongoing investigations in liver of rainbow trout (*Salmo gairdneri*, Richardson), considerations for morphologic assessment of pollutant injury are provided.

Stereology/Morphometry Approach to Morphology

Stereology is defined as "a body of mathematical methods relating three-dimensional parameters of a structure to two-dimensional measurements obtainable on sections of the structure" (*2*). When applied to the biological investigation, this permits quantitative objective determination of average three-dimensional values from measurements made on sections (*5*). Typically, stereological parameters are in terms of densities, i.e., volume density, the fraction of the reference space occupied by an object, or surface density, the surface area in a unit of reference volume. Conversion of densities to absolute values is performed by independently determining the volume of the reference space. Because the determination of densities is the ratio of two measurements, the object and the reference space, the most efficient manner of collecting data for stereological eval-

*Department of Anatomy, School of Medicine, West Virginia University, Morgantown, WV 26506.
†Present address: Department of Veterinary Medicine, University of California, Davis, CA 95616.
‡Present address: Department of Pathology, Medical College of Ohio, Toledo, OH 43699.

uation is to use a multitiered design (Fig. 1) (*4*). In this design, the determination of parameters begins at the light microscopic level with the whole organ as the reference volume. As the level of detail of structural analysis advances to the tissue and cellular level, the reference volumes are also changed to maximize the efficiency of data collection. For example, in teleost liver (Fig. 1), the total parenchyma and nonparenchyma are referenced to the whole organ, the cells and extracellular spaces are referenced to the parenchyma, the hepatocytes and nonhepatocytes are referenced to total cellular volume, the nuclei and cytoplasm are referenced to the total hepatocyte volume and the cellular organelles and spaces are referenced to the cytoplasm. Although data are referred to different reference volumes at different levels of analysis, the interdependent nature of the multitiered design permits any value to be referred to the whole organ volume.

The quantitative nature of data obtained from stereological investigations permits correlation with biochemical and physiological measurements (*6–8*). At first, it may appear that morphological data are not important to an understanding of the biochemical events occurring in an organ. However, when we consider that these biochemical events are occurring in particular cellular compartments, information on volume, surface area, number, and size of these structures or of the cells themselves is important for elucidating the events at the cellular level.

The cell biology literature contains examples of correlated structure/function studies some of which are briefly described below. Phenobarbital exposure was studied in rat liver (*9*). Surface density of hepatocyte smooth endoplasmic reticulum, the cellular locus for the microsomal mixed function oxidase system (MFOS), increased as enzyme induction occurred. The pathway of protein movement and sites of concentration were studied during plasma membrane protein synthesis. Coupled morphometric and biochemical approaches were used to determine how proteins are sorted and concentrated during this process (*10,11*). Similarly, coupled biochemical, cytochemical, and morphometric studies revealed changes in the proteoglycan component of the matrix in colon carcinoma (*12*). In normal colon, hyaluronate heparan sulfate and dermatan sulfate were high. By contrast, in neoplasm, chondroitin sulfate was by far the most abundant. By combining stereology with biochemistry of isolated mitrochondria, the architecture of the inner mitochondrial membrane of rat liver was determined (*8*). Usage of morphometric approaches to investigation of xenobiotic (7,12-dimethylbenzanthracene)-induced alteration in adrenal gland illustrated the applicability of this approach to endocrine toxicity (*13*).

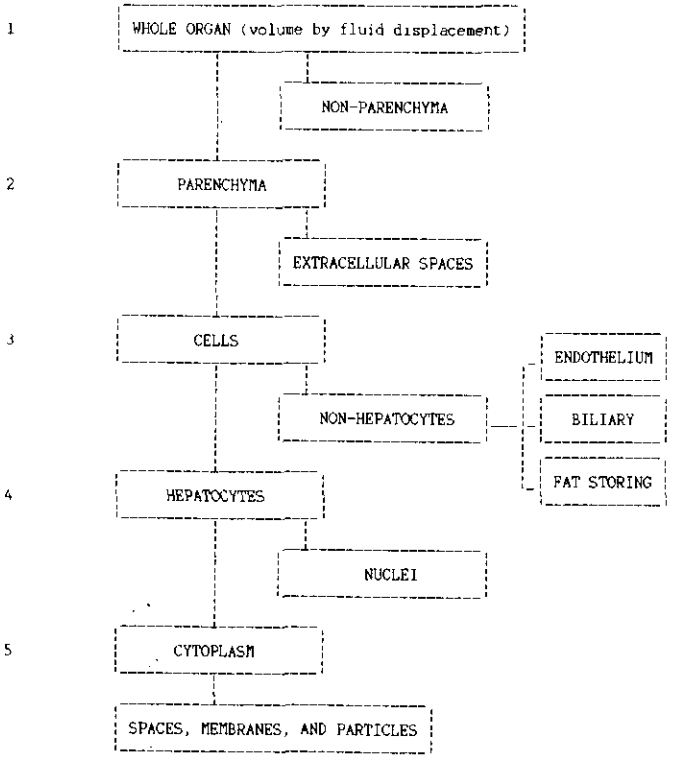

FIGURE 1. Multitiered approach to stereological analysis of teleost liver.

Morphologic alteration of hepatic endoplasmic reticulum has been reported after exposure of fish to various xenobiotics (*14*). These include 3-methylcholanthrene (*15*) and chlorobiphenyls (*16,17*) and drugs (*18*). Additional studies with other inducing agents such as the coplanar isomers of polychlorinated biphenyl (*19*) are needed. The effect of carbon tetrachloride, CCl_4, on rainbow trout liver has been studied histologically (*20–23*), and toxicity was observed. CCl_4 hepatotoxicity in trout was also demonstrated by increases in levels of serum enzymes, especially glutamate-pyruvic transaminase (*20,21,23*). The retention of sulfobromophthalein (BSP) in plasma also forms a useful index by which to evaluate liver dysfunction. Although Gingerich et al. (*22*) showed decreased biliary clearance of BSP in trout after CCl_4, they concluded that morphologic changes were not correlated with the serum probe. Similarly, in kidneys of trout treated with CCl_4 (*24*) light microscopic subjective morphologic evaluation failed to show correlation with elevated serum enzyme levels and urine parameters, respectively. Serum enzyme elevation, diminished BSP clearance and proteinuria are the result of alteration within specific cell types (liver-hepatocytes and bile ductular epithelium; kidney-cells of glomerulus and of proximal tubule). For correlation of morphological and biochemical data measurements must be referred to the same structural reference (*6,7*) (Fig. 1). It would not be appropriate, for example, to compare biochemical data per gram of tissue with stereological data referenced to an average cell. Routine histologic techniques provide little if any information at the cellular level of organization. For a common unit of reference (*6, 7*) to exist, morphologic probes at the cellular and/or organelle level would be necessary.

Various additional techniques may be used to improve correlation between morphological and biochemical approaches. Cell separation by flow cytometry or differ-

ential elutriation can isolate specific cell types. These techniques could also be used in conjunction with compounds that fluorescently label particular enzymes or markers in cells thus isolating cells that are functionally different from each other. In addition, correlation could be achieved using specific labels (special stains or polymonoclonal antibodies) that can be visualized at the light and electron microscopic levels (*12*). For example, these techniques may prove important for separating oval cells (bile preductular and ductular cells) and hepatocytes for analysis in studies on development of liver carcinogenesis.

Normal Versus Altered Structure

Disease is not associated with new different structure and function; rather quantitative alteration of existing structure and function occurs (*25*). To date, morphometric evaluation in fishes has been confined primarily to three organs: skin, gill, and liver. In each of these, *quantitative structural data have been obtained and* have proved important in improving our understanding of the response(s) of organs to injury. Each of these also illustrates varying microscopic levels of examination, which have proved appropriate for answering questions about site(s) and mechanism of action of toxicants.

Morphometric Study of Skin

The epidermis of fishes is in intimate contact with their surroundings and as such is a prime site for evaluation of effects and responses of epithelia to toxicant exposure. Evidence suggests that changes in structure and cellular composition of skin may influence the ability of fish to resist disease organisms (*26*). Most notable of the changes are sex-related differences in structure observed during maturation when the skin of mature males thickens and almost completely becomes devoid of mucous in some species (*27*). Sexual dimophorism is not restricted to salmonids but occurs in the winter flounder (*28*) and the fathead minnow (*29*). Maturational changes in skin structure are thought to occur as a result of stimulation by androgenic steroids (*30–32*). Schwerdtfeger (*33, 34*) used morphometric methodology to quantitatively examine epidermis of guppy, *Poecilia reticulata*, following treatment with prolactin, thyroxine, and testosterone. When freshwater-adapted guppies were treated with prolactin, morphologic parameters in epidermis that were increased included the number of mucous cells, the number of cell layers, and the number of subepidermal capillaries. Upon adaptation to sea water, epidermis of guppies showed increased surface extent of superficial cells, increase in the number of small, electron-dense vesicles, and increased occurrence of chloride cells. Thyroxin in low doses caused the same plus increased height of glycocalyx (*34*). One environmentally important toxic condition affecting fish populations is acid rain. Zuchelkowski et al. (*35*) sought to determine how acid stress affects the structure of fish epidermis. Previous work had demonstrated that increased mucous production was involved in the response to acid stress. Specific mucous stains in paraffin-embedded tissue from the abdominal epidermis of brown bullhead catfish were used to label mucosubstance. Initial evaluation determined that, following acid stress, epidermis responded acutely (first 5 days) with a hyperplasia of mucous cells (*35*). Subsequent analysis, combined with additional information, led to a more complete description of the response and also indicated parameters that must be considered in design of toxicity bioassay involving fishes. First, Zuchelkowski et al. (*36*) found that the number and size of mucous cells differed between control males and females, indicating sexual dimorphism of this species and confirming prior studies in other species. Second, the response to acid stress differed in the two sexes. Males responded with a hypertrophy and hyperplasia, whereas females responded with only a slight but significant hyperplasia. Last, autoradiography did *not demonstrate increased mitosis, suggesting that hy*perplasia was due to recruitment of existing cell types to form mucous cells rather than by mitosis of existing mucous cells. In order to determine which cell types might be involved in the recruitment, electron microscopic examination was conducted. Coexistence of small mucous granules and cytofilaments suggested that the initial hyperplasia can be explained on the basis of recruitment from existing differentiated cells, a process known to occur in hamster tracheal epithelium after mechanical injury (*37*).

Morphometric Analysis of Normal and Altered Teleost Gill

The importance of this organ in respiration and in ion regulation has led to numerous investigations on effects of alteration in environmental factors on: relative abundance and morphology of chloride cells, hyperplasia of surface epithelium, fusion of secondary lamellae, uptake of toxicants, effects of pollutants on respiratory physiology and alterations of water/blood barrier thickness and resultant effects on oxygen transport.

The morphology of the gill presents numerous examples of structure tightly linked to function at organ, tissue, and cellular levels of organization. For example, each of the four branchial arches on each side is a curved pathway from midline ventral to midline dorsal pharynx initially conducting a large afferent and small efferent branchial artery. The relationship is changed, however, at the dorsal midline where the efferent artery is much larger and reflects the abundance of oxygenated blood flow now directed to the dorsal aorta. The arrangement of the pharyngeal wall into arches with intervening spaces rather than the solid wall of the remainder of the digestive system no doubt facilitates flow of water from pharynx over respiratory surfaces of gills. Similarly, a staggered arrangement at sites of attachment of filaments to arch increases exposure of surface of

filament and their attached lamellae to water. Within lamellae, blood cells within pillar system are separated from the water by a thin barrier of pillar cell, basal lamina, potential space, inner epithelial cell, and outer epithelial cell. The thickness of this barrier is directly related to the oxygen diffusion capacity of the structure.

One of the more direct uses of stereology in assessing the functional state of tissues and organs has been its application to evaluation of gas exchange capabilities of mammals and fishes. The ability of the lungs or gills to extract oxygen from their surroundings (air or water) and transport it to the blood and erythrocytes depends on the ease with which the gas can be transported through the tissues, the thickness of the barrier, and the surface available for transport. Although diffusibility of gases in the various tissues must be determined independently, estimation of surface areas and thicknesses of tissues can be determined stereologically. These techniques, originally developed by Weibel (*38*), have been applied to a number of mammalian species to determine the maximum oxygen diffusion capacity of lungs. Similar techniques have been developed by Hughes (*39,40*) to determine effect of waterborne metals on oxygen diffusion capacity of gills (*40,41*). An independently determined value for the oxygen diffusion through tissues, and therefore the absolute oxygen diffusion capacity, may not always be easily obtained. Hughes therefore developed a relative change in diffusion capacity from control to exposed fish based solely on morphological criteria. With this scheme, measurements were made to determine the total epithelial surface area of secondary lamellae (S_0), total surface area of the basement membrane between the inner epithelial layer and the pillar system of secondary lamellae (S_i) and the harmonic mean thickness of the air-water barrier (τ) in both control and exposed fish. Determination of the relative change in diffusion capacity was then taken by the relationship:

$$\frac{(S_0/S_i)_{\text{exp}}}{\tau_{\text{exp}}} \Big/ \frac{(S_0/S_i)_{\text{con}}}{\tau_{\text{con}}}$$

Any change from a value of one would indicate a relative change in diffusion capacity. It should be noted that the values needed for determination of relative diffusion capacity can adequately be estimated at the high resolution light microscopic level of examination. If, however, questions being asked concern the sites and mechanisms involved in alteration of the diffusion capacity, low magnification electron microscopy may be necessary. When additional morphometric data were taken concerning tissues composing the secondary lamellae, identification of site of the alteration could be determined. Hughes and Perry (*40, 41*) used this technique to determine changes in the gill, i.e., enhanced thickening of epithelial layers and associated tissue spaces following exposure to and recovery from nickel. Keller and Hinton (*42*) have also used these techniques in conjunction with water chemistry measurements in an attempt to correlate surface water quality with gill alteration in feral fishes of West Virginia streams.

Considerations in Normal and Altered Teleost Liver Structure

The liver of teleosts, the major target organ for xenobiotics, is most frequently cited as the site of parenchymal damage following exposure to various chemical agents (*43*). Metabolism of potential toxins by hepatic monooxygenases and chemical-induced carcinogenesis, predominantly liver phenonmena, further illustrate importance of this organ in research (*19,44*).

In mammalian liver toxicity, the classic lobule (*45*) is used as a means of characterizing hepatotoxicity of various agents including xenobiotics (*46*). It is well appreciated that mammalian centrilobular or zone 3 (*47*) necrosis is mediated by CCl_4 (*48*) and periportal or zone 1 necrosis is the result of exposure to an agent such as allyl formate (*49*).

In teleost liver, as well as in most nonmammalian vertebrates, the architecture of the liver is that of tubules of cells which was appreciated and defined by workers of the past century (*50*). Transversely sectioned tubules have five to seven hepatocytes arranged radially around and with their apices directed toward a bile canaliculus and/or a bile preductule. The basal aspects of hepatocytes are directed toward sinusoids (Fig. 2). More recently, Simon et al. (*51*) used serial paraffin sections to construct models of rainbow trout liver and showed that lobules were indistinct if not absent. Gingerich (*43*) concluded that the repeating mammalian mosaic of portal and central veins was not a feature of teleost liver. Trout lack lobules and portal triads (Fig. 3). Therefore, it is difficult if not impossible to differentiate portal and hepatic venules by conventional techniques. Although Schar et al. (*52*) gave no criteria for selection of specific venules in trout liver, they considered the course of the terminal afferent and efferent vessels as the most important factor in the determination of "metabolic zonation". Therefore the ability to unequivocally determine portal (afferent) versus he-

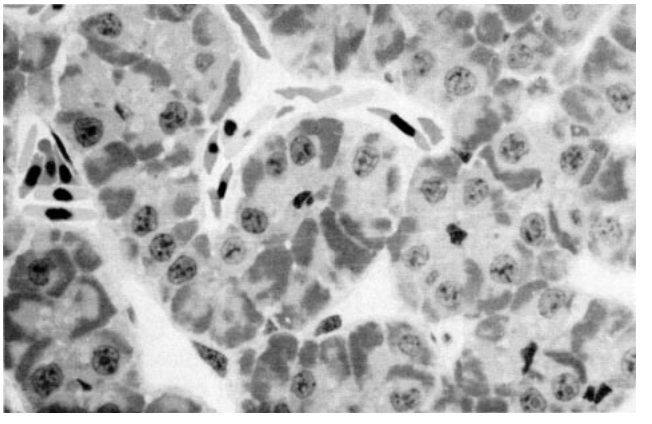

FIGURE 2. High resolution light micrograph of perfusion fixed liver from rainbow trout shows tubules of hepatocytes and associated biliary epithelial cells. Nucleated red blood cells are shown in sinusoids at base of hepatocytes. Toluidine blue-stained Epon section. × 600.

FIGURE 3. Low magnification view of trout liver processed for conventional paraffin embedment, typical of that obtained following perfusion fixation. Veins, venules and sinusoids are cleared of blood cells. Analysis of parenchyma shows no evidence of portal triads. H&E, × 60.

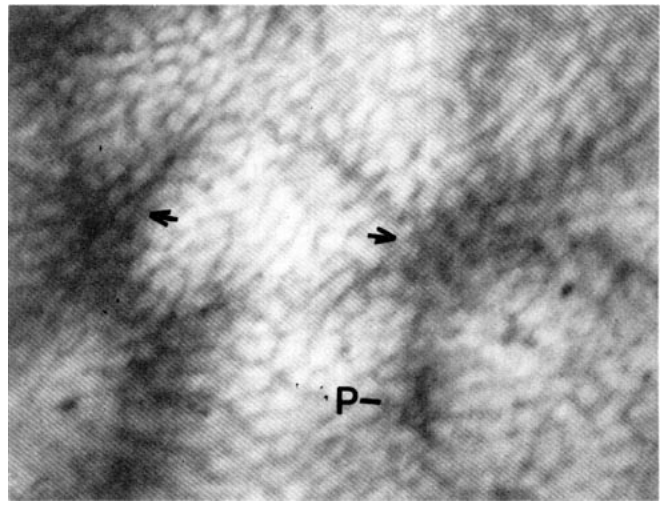

FIGURE 4. Photograph of video image from *in vivo* microscopy of rainbow trout liver. Two star-shaped patterns of veins which when viewed *in vivo* conducted blood from sinusoids adjacent to parenchymal tubules toward larger diameter hepatic veins (arrows) near the hepatic surface. Vessel P brought blood from deep in liver and is a portal vein. Epifluorescence illumination, × 5.

patic (efferent) venules and their surrounding hepatocyte is of basic importance.

In order to define precisely the trout liver microvasculature, high resolution *in vivo* microscopic methods (*53–58*) were used. Trout were anesthetized and maintained by gill suffusion of MS-222, and their livers were surgically exposed and suffused by teleost Ringer's solution. Livers were epiilluminated at various wavelengths from 350 to 700 nm through appropriate interference filters by using a Leitz Ploem-Pak illuminator. Such illumination permitted good definition of tubules, sinusoids, venules, and some cellular detail. Blood flow from venules to sinusoids positively identified the former as afferent (portal) venules and blood flow from sinusoids to venules positively identified the efferent (hepatic) venules. By using a 5× objective, microscopic images of afferent and efferent venules and sinusoids could be secured (Fig. 4). Hepatic venules and veins revealed a star-shaped pattern at the surface of the liver. Portal venules appeared to arise from deep within the liver with occasional branches lying near hepatic venules. Under higher magnification (20×), the connection of sinusoids to venules could be seen (Fig. 5). Hepatic venules were short and anastomosed with others to form larger diameter vessels which were oriented perpendicular to the surface of the liver.

The combined use of epifluorescence illumination and the intravascular injection of a nontoxic fluorochrome (Na fluorescein) permitted visualization of the microvasculature and subsequently the bile canalicular and ductular systems. Sinusoids were organized around the tortuous tubules of hepatic parenchymal cells thereby forming a high anastomotic vascular network which bathed each tubule on several sides (Fig. 6). As a result sinusoids were never arranged in a parallel array such as is typical of the centrilobular sinusoids in mammalian liver. Rather, the tortuous microvascular network

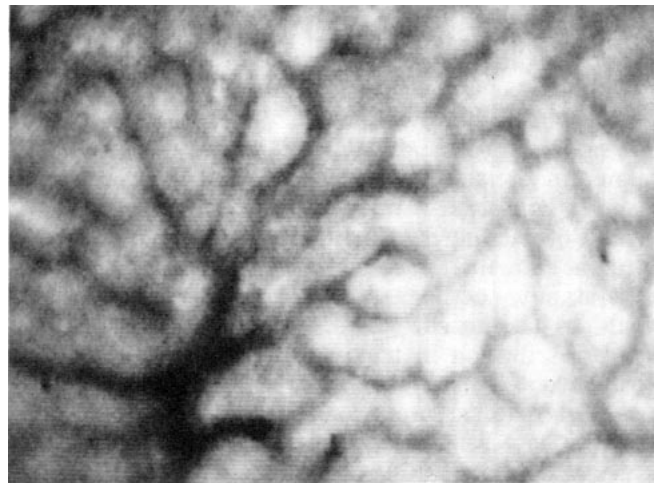

FIGURE 5. Image, obtained as in Fig. 4 above, showing confluens of sinusoids to create short initial hepatic venules. *In vivo* micrograph, × 20.

throughout the trout liver resembled the tortuous network seen in the periportal regions of the mammalian liver. As a result, intravasculary injected Na fluorescein initially is seen in the sinusoids and subsequently is excreted by the parenchymal cells into the bile cancaliculi and initial biliary ductules which it clearly delineates (Fig. 6). No dye was seen in other extravascular spaces. The injection of 1 μm fluorescent latex beads into the portal circulation revealed no evidence for a population of phagocytic Kupffer cells in the trout liver (*59*).

If we are to use aquatic species in toxicity testing it is imperative that we understand how the tubular liver

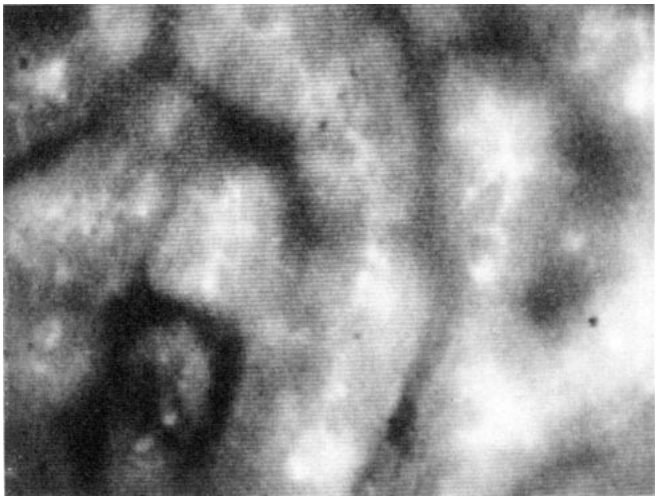

FIGURE 6. Trout liver *in vivo* micrograph showing Na fluorescein-associated fluorescence localized to bile canaliculi and ductules. Epifluorescence illumination, × 40.

of teleosts responds to various toxicants. Questions include: (1) Do subpopulations (functional units) of hepatocytes exist in the tubular liver? (2) Based on the location of the hepatocytes adjacent to defined portions of the hepatic vasculature, will some cells show toxic effects while others will not?

A major objective of work by our group has been to define functional units in rainbow trout liver. We have asked the question of whether small groups of cells are capable of carrying out the functions for which the entire organ is known. If such occur within teleost liver, our understanding of the response of this organ to pollutants would be facilitated. When enzymes known for their zonal distribution in mammalian liver were localized within trout liver, we (*60*) saw no preferential localization of reaction products. With glucose-6-phosphatase, slight accentuation was observed in perivenous locations. Although their title referred to metabolic zonation, Schar et al. (*52*) saw less evidence for selective enzyme distribution in trout than they had observed in mammalian liver.

The next step taken by our group was to define the trout liver morphometrically (Hampton et al., unpublished observations, this laboratory). Following portal venous perfusion fixation (*60*) of trout liver, a multitiered morphometric study was done in livers of male and female 5½ year old rainbow trout. Light microscopic examination revealed a 30% shrinkage artifact when paraffin embedment procedures were used. Interestingly, direct measurement of pieces of the same liver processed in glycol methacrylate for light microscopy revealed no shrinkage. Significant sex differences were seen. Females possessed significantly more hepatocytes than did males. However, individual hepatocytes of females were significantly smaller. Hepatocyte nuclear volume was equal in cells from both sexes indicating that differences were due to cytoplasmic volume. The remaining parenchymal cells and spaces were evaluated. Perisinusoidal macrophages of female trout occupied larger volumes of liver than did the same cells of males. Although occupying a relatively small portion of the parenchymal compartment, biliary epithelial cells of ductules and preductules were numerous. Ratios of hepatocytes to biliary epithelial cells ranged from 5 to 9 to 1. Such abundance of these putative stem cells in trout liver may explain the sensitivity of this species to carcinogens (*44*).

When compared to literature values for mammalian hepatocytes, trout hepatocytes were 1/3 to 1/5 the size of the former. This illustrates the need for added resolution in light microscopic examination, routine paraffin sections of 7–8 μm thickness may not suffice. To obtain reliable estimates of cell parameters in trout liver, low magnification electron microscopy proved essential.

Future Directions

Since methods were shape dependent, obtaining numerical density estimates for various structures has been difficult. In practice, structures had to be elliptical or spherical (*1–3*) or serial sections followed by three dimensional reconstruction were necessary to determine shape. A recently developed method, the disector (*61*), will no doubt prove useful in future studies. This stereological technique permits the determination of number, size and volume of arbitrarily shaped structures. All that is required is to count objects on two parallel sections a known distance apart. Thus the disector makes it possible to determine the number, size and volume of any object of interest (cells, cellular organelles, etc.).

By preparing ferritin or colloidal gold labeled antibodies to specific membrane proteins, the locations of specific enzymes can be visualized electron microscopically. As suggested by Bolender (*7*), this information may be used to construct areal distribution maps for enzymes in membranes. In this way questions concerning the heterogeneity of enzyme distribution with membranes may be approached. Similarly, interhepatocyte heterogeneities may be studied in cell suspensions.

Summary

The morphologist may continue to contribute meaningful information relevant to aquatic toxicology particularly if quantitative approaches amenable to statistical evaluation are increasingly employed. The level of structural organization at which toxic alteration is found will vary with the pollutant, the organ or tissue site, and conditions of exposure but will be approachable if a multitiered sampling procedure is initially employed. The expense inherent in collecting tissues for morphometry is not appreciably different than that for routine histopathology. Adaptation of such procedures permits the subsequent evaluation at successive tiers of organization should they be desired.

This work was supported by grant PCM-8316002 from the National Science Foundation.

REFERENCES

1. Reide, U. N., and Reith, A. Morphometry in Pathology. Gustav Fisher Verlag, New York, 1980.
2. Weibel, E. R. Stereological Methods, Vol. 1. Academic Press, New York–London, 1979.
3. Weibel, E. R. Stereological Methods. Vol. 2. Academic Press, New York–London, 1980.
4. Rohr, H. P., Oberholzer, M., Bartsch, G., and Keller, M. Morphometry in experimental pathology: methods, baseline data and application. Int. Rev. Exptl. Pathol. 15: 233–325 (1976).
5. Loud, A. V., and Anversa, P. Biology of disease: morphometric analysis of biologic processes. Lab. Invest. 50: 250–261 (1984).
6. Bolender, R. P. Correlation of morphometry and stereology with biochemical analysis of cell fractions. Int. Rev. Cytol. 55: 247–289 (1978).
7. Bolender, R. P. Stereology: applications to pharmacology. Ann. Rev. Pharmacol. Toxicol. 21: 549–573 (1981).
8. Schwerzmann, K., and Hoppeler, H. Stereology: a working tool for cell biologists. Trends Biochem. Sci. 10: 184–187 (1985).
9. Staubli, W., Hess, R., and Weibel, E. R. Correlated morphometric and biochemical studies on the liver cell. II. Effects of phenobarbital on rat hepatocytes. J. Cell Biol. 42: 92–112 (1969).
10. Griffiths, G., Warren, G., Quinn, P., Mathieu-Costello, O., and Hoppeler, H. Density of newly synthesized plasma membrane proteins in intracellular membranes. I. Stereological studies. J. Cell Biol. 98: 2133–2141 (1984).
11. Quinn, P., Griffiths, G., and Warren, G. Density of newly synthesized plasma membrane proteins in intracellular membranes. II. Biochemical studies. J. Cell Biol. 98: 2142–2147 (1984).
12. Iozzo, R. V., Bolender, R. P., and Wight, T. N. Proteoglycan changes in the intercellular matrix of human colon carcinoma. An integrated biochemical and stereological analysis. Lab. Invest. 47: 124–138 (1982).
13. Belloni, A. S., Mazzocchi, G., Claudia, R., Gambino, A. M., and Nussdorfer, G. G. An ultrastructural morphometric and autoradiographic study of the effects of 7,12-dimethylbenzanthracene on the rat adrenal cortex. Virchows Arch. Cell Pathol. B 26: 195–214 (1978).
14. Hawkes, J. W. The effects of xenobiotics on fish tissues: morphological studies. Fed. Proc. 39: 3230–3236 (1980).
15. Schoor, W. P. and Couch, J. A. Correlation of mixed-function oxidase activity with ultrastructural changes in the liver of a marine fish. Cancer Biochem. Biophys. 4: 95–103 (1979).
16. Hacking, M. A., Budd, J., and Hodson, K. The ultrastructure of the liver of the rainbow trout: normal structure and modifications after chronic administration of a polychlorinated biphenyl Aroclor 1254. Can. J. Zool. 56: 447–491 (1977).
17. Klaunig, J. E., Lipsky, M. M., Trump, B. F., and Hinton, D. E. Biochemical and ultrastructural changes in teleost liver following subacute exposure to PCB. J. Environ. Pathol. Toxicol. 2: 953–963 (1978).
18. Scarpelli, D. G. Drug metabolism and aflatoxin-induced hepatoma in rainbow trout (*Salmo gairdneri*). Progr. Exptl. Tumor Res. 20: 339–350 (1976).
19. Lech, J. J., Vodicnik, M. J., and Elcombe, C R. Induction of monooxygenase activity in fish. In: Aquatic Toxicology (L. J. Weber, Ed.), Raven Press, New York, 1983, pp. 107–148.
20. Pfeifer, K. F., Weber, L. J., and Larson, R. E. Carbon tetrachloride-induced hepatotoxic response in rainbow trout, *Salmo gairdneri*, as influenced by two commercial fish diets. Comp. Biochem. Physiol. 67C: 91–96 (1980).
21. Statham, C. N., Croft, W. A., and Lech, J. J. Uptake, distribution and effects of carbon tetrachloride in rainbow trout (*Salmo gairdneri*). Toxicol. Appl. Pharmacol. 45: 131–140 (1978).
22. Gingerich, W. H., Weber, L. J., and Larson, R. E. The effect of carbon tetrachloride on hepatic accumulation, metabolism, and biliary excretion of sulfabromophthalein in rainbow trout. Toxicol. Appl. Pharmacol. 41: 649–658 (1978).
23. Racicot, J. G., Gaudet, M., and Leray, C. Blood and liver enzymes in rainbow trout (*Salmo gairdneri* Rich.) with emphasis on their diagnostic use: study with CCl_4 toxicity and a case of Aermonas infection. J. Fish Biol. 7: 825–835 (1975).
24. Pfeifer, K. F., and Weber, L. J. The effect of carbon tetrachloride treatment on urine flow rate of the rainbow trout (*Salmo gairdneri*). Toxicol. Appl. Pharmacol. 52: 347–350 (1980).
25. Forbus, W. D. Reaction to Injury: Pathology for Students of Disease. Williams and Wilkins, Baltimore, MD, 1952.
26. Pottinger, T. G., and Pickering, A. D. Changes in skin structure associated with elevated androgen levels in maturing male brown trout, *Salmo trutta* L. J. Fish Biol. 26: 745–753 (1985).
27. Pickering, A. D. Seasonal changes in the epidermis of the brown trout *Salmo trutta* (L.). J. Fish Biol. 10: 561–566 (1977).
28. Burton, D., and Fletcher, G. L. Seasonal changes in the epidermis of the winter flounder, *Pseudopleuronectes americanus*. J. Mar. Biol. Assoc. 63: 273–287 (1983).
29. Smith, R. J. F. Seasonal changes in the histology of the gonads and dorsal skin of the fathead minnow *Pimephales promelas*. Can J. Zool. 56: 2103–2109 (1978).
30. Idler, D. R., Bitners, I. I., and Schmidt, P. J. 11-ketotestosterone: an androgen for sockeye salmon. Can. J. Biochem. Physiol. 39: 1737–1742 (1961).
31. Yamazaki, F. Effects of methyltestosterone on the skin and the gonad of salmonids. Gen. Comp. Endocrinol. 3 (Suppl.) 741–750 (1972).
32. Smith, R. J. F. Effects of 17 α-methyltestosterone on the dorsal pad and tubercles of fathead minnows (*Pimephales promelas*). Can. J. Zool. 52: 1031–1033 (1974).
33. Schwerdtfeger, W. K. Morphometrical studies of the ultrastructure of the epidermis of the guppy, *Poecilia reticulata* Peters, following adaptation to seawater and treatment with prolactin. Gen. Comp. Endrocrinol. 38: 476–483 (1979a).
34. Schwerdtfeger, W. K. Qualitative and quantitative data on the fine structure of the guppy (*Poecilia reticulata* Peters) epidermis following treatment with thyroxine and testosterone. Gen. Comp. Endrocinol. 38: 484–490 (1979b).
35. Zuchelkowski, E. M., Lantz, R. C., and Hinton, D. E. Effects of acid-stress on epidermal mucous cells of the brown bullherad *Ictalurus nebulosus* (LeSeur): a morphometric study. Anat. Rec. 200: 33–39 (1981).
36. Zuchelkowski, E. M., Lantz, R. C., and Hinton, D. E. Skin mucous cell response to acid-stress in male and female brown bullhead catfish, *Ictalurus nebulosus* (LeSeur). Aquatic Toxicol. 8: 139–148 (1986).
37. McDowell, E. M., Becci, P. J., and Schurch, W. The respiratory epithelium. VII. Epidermoid metaplasia of hamster tracheal epithelium during regeneration following mechanical injury. J. Natl. Cancer Inst. 62: 995–1008 (1979).
38. Weibel, E. R. Morphometric estimation of pulmonary diffusion capacity. I. Model and method. Resp. Physiol. 11: 54–75 (1971).
39. Hughes, G. M., and Morgan, M. The structure of fish gills in relation to their respiratory function. Biol. Rev. 48: 419–475 (1973).
40. Hughes, G. M., and Perry, S. F. Morphometric study of trout gills: A light microscopic method suitable for evaluation of pollutant action. J. Exptl. Biol. 64: 447–460 (1976).
41. Hughes, G. M., and Perry, S. F. A morphometric study of effects of nickel, chromium and cadmium on the secondary lamellae of rainbow trout gills. Water Res. 13: 665–679 (1979).
42. Keller, E. C., Jr., and Hinton, D. E. Effect of iron in streams on gill morphology, oxygen consumption, and phytoplankton/benthic invertebrate distribution. West Virginia University Water Research Institute, Completion Report #375202, 1983.
43. Gingerich, W. H. Hepatic toxicology of fishes. In: Aquatic Toxicology (L. J. Weber, Ed.), Raven Press, New York, 1982, pp. 55–105.
44. Hendricks, J. D. Chemical carcinogenesis in fish. In: Aquatic Toxicology (L. J. Weber, Ed.), Raven Press, New York, 1982, pp. 149–211.
45. Elias, H., and Bengelsdorf, H. The structure of the liver of vertebrates. Acta Atna. 14: 297–337 (1952).
46. Zimmerman, H. J. Experimental hepatoxicity. In: Handbook of

Experimental Pharmacology, Vol. XVI/5 (G. V. R. Born, O. Eichler, A. Farah, H. Herkin, and A. O. Welch, Eds.), Springer-Verlag, Berlin, 1976, pp. 1–120.
47. Rappaport, A. M. The microcirculatory acinar concept of normal and pathologic hepatic structure. Beitr. Pathol. 157: 215–243 (1976).
48. Rouiller, C. Experimental toxic injury of the liver. In: The Liver (C. Rouiller, Ed.), Academic Press, New York, 1964, pp. 315–476.
49. Rees, K. R., and Tarlow, M. J. The hepatotoxic action of allyl formate. Biochem. J. 104: 757–761 (1967).
50. Shore, T. W., and Jones, H. L. On the structure of the vertebrate liver. J. Physiol. (London) 10: 408–428 (1889).
51. Simon, R. C., Dollar, A. M., and Smuckler, E. A. Descriptive classification of normal and altered histology of trout livers. In: Trout Hepatoma Research Conference Papers (J. E. Halver and I. A. Mitchell, Eds.), Research Report #70, U.S. Fish and Wildlife Service, Washington, 1967, pp. 18–28.
52. Schar, M., Maly, I. P., and Sasse, D. Histochemical studies on metabolic zonation of the liver in the trout (*Salmo gairdneri*). Histochem. 83: 147–151 (1985).
53. McCluggage, S. G., Jr., and McCuskey R. S. *In vivo* microscopic study of the response of hepatic microvascular system to carbon tetrachloride poisoning. Microvas. Res. 3: 354–360 (1971).
54. McCuskey, R. S. A dynamic and static study of hepatic arterioles and hepatic sphincters. Am. J. Anat. 119: 455–487 (1966).
55. McCuskey, R. S. *In vivo* microscopy of internal organs. Opening invited lecture. XI Internat. Congr. Anat., Mexico City, 1980. Progr. Clin. and Biol. Res. 59: 79–87 (1981).
56. McCuskey, R. S., Reilly, F. D., McCuskey, P. A., and Dimlich, R. V. M. "In vivo" microscopic studies of the hepatic microvascular system. In: Symposium of Intravital Microscopy of Organs, X European Conf. on Microcirculation, Caglieri, Italy, October 23–28, 1978; Biblio. Anat. 18: 73–76 (1979).
57. McCuskey, R. S., Urbaschek, R., McCuskey, P. A., and Urbaschek B. *In vivo* microscopic observations of the responses of Kupffer cells and the hepatic microcirculation to *Mycobacterium bovis* BCG alone and in combination with endotoxin. Infect. Immunity 42: 362–367 (1983).
58. McCuskey, R. S., Vonnahme, F. J., and Grun, M. *In vivo* microscopic and electron microscopic observations of the hepatic microvascular system following portacaval anastomosis. Hepatology 3: 96–104 (1983).
59. McCuskey, P. A., McCuskey, R. S., and Hinton, D. E. Electron microscopy of cells of the hepatic sinusoids in rainbow trout (*Salmo gairdneri*). In: Cells of the Hepatic Sinusoids I (A. Kirn, D. L. Knook, and E. Wisse Eds.), Leiden, Kupffer Cell Foundation, 1986, pp. 489–494.
60. Hampton, J. A., McCuskey, P. A., McCuskey, R. S., and Hinton, D. E. Functional units in rainbow trout (*Salmo gairdneri*) liver: I. Arrangement and histochemical properties of hepatocytes. Anat. Rec. 213: 166–175 (1985).
61. Sterio, D. C. The unbiased estimation of number and sizes of arbitrary particles using the disector. J. Microscopy 134: 127–136 (1984).