Environmental Health Perspectives
Vol. 88, pp. 237–241, 1990

Induction and Progression of Human Lymphoproliferative Lesions by Epstein-Barr Virus

by Bettina Borisch Chappuis* and Hans Konrad Müller-Hermelink*

Epstein-Barr virus (EBV) is involved in numerous lymphoproliferative diseases. In addition to classical lesions such as endemic Burkitt's lymphoma and infectious mononucleosis, there are other disorders of the lymphoid system that are discussed in relation to EBV: B-cell lymphomas in immunosuppressed individuals, Hodgkin's disease and, to some extent, primary extranodal lymphomas. Studies of the EBV expression in classical and nonclassical lesions could lead to the better understanding of different EBV mechanisms in lymphomagenesis.

Introduction

Epstein-Barr virus (EBV) is intimately linked with some well-described lesions of the lymphoid system (*1*). However, the basic mechanisms of EBV-associated lymphomagenesis are not yet fully understood. The study of EBV-induced lymphoproliferative disease (LPD) in immunodeficiency (*2*) has been very helpful in this context. Recently, EBV involvement in tumors of the lymphoid system other than the classical ones is being discussed again. One of the lesions under consideration is Hodgkin's disease (*3*); another condition is T-cell lymphoma (*4*). Further, the involvement of EBV in extranodal lymphomas of various origins is suggested (*5*). In this report we discuss the distribution of EBV in lymphoid lesions. In addition, morphological evidence of different EBV expression in reactive and tumorous lesions is presented.

Materials and Methods

Five hundred thirty-nine cases with an eventual association with EBV were collected from the files of the Institute of Pathology Würzburg or were a gift from various other colleagues to whom we are greatly indebted. Most of the cases were lymphomas and LPD. Five nasopharyngeal carcinomas and six cases of infectious mononucleosis (IM) were included for control purposes. African lymphomas and lymph nodes came from Uganda, Rwanda, and Tanzania. All other lesions were from Central Europe. The results presented were obtained with lymphomas in AIDS, LPD in inborn immunodeficiencies in children, and extranodal lymphomas.

All lesions were studied morphologically and immunohistochemically. They were investigated for the presence of EBV DNA by hybridization (dot or Southern blot) with whole cellular DNA obtained from fresh or paraffin material and appropriate EBV probes. In parallel, tissue sections were used for *in situ* hybridization (ISH) to localize EBV DNA in the tissue. Molecular biology studies made use of standard techniques (*6*). DNA extraction from paraffin-embedded material was carried out as described by Goelz et al. (*7*), ISH with ^{35}S-labeled probes and consecutive autoradiographic development for 1 to 5 weeks. Controls were as follows: Raji cell DNA served as positive controls and IM and nasopharyngeal carcinoma as positive cases. Negative controls included unrelated lymphoid tissues (42 lymphadenitis) and hybridization with a cytomegalovirus probe and omission of the specific probe.

Results

Lymphomas in AIDS, African Burkitt's Lymphomas, and LPD in Inborn Immunodeficiency

Histological classification and the main clinical data are shown in Table 1. The LPD in children with inborn immunodeficiencies were diagnosed according to Frizzera's proposition (*8*). Lymphomas were evaluated using the Kiel classification. The results obtained using

*Department of Pathology, University of Würzburg, D-8700 Würzburg, Federal Republic of Germany.
Address reprint requests to Bettina Borisch Chappuis, Department of Pathology, University of Bern, CH 3010 Bern, Switzerland.

Table 1. Clinical data.

Case	Age[a]	Sex	Tissue studied	Histologic findings	Clinical presentation
Children with immune defects					
1	3 months	M	Liver, spleen	Polymorphic B-cell lymphoma, thymic hypoplasia	SCID (immunologically and clinically), abdominal tumor
2	5 years	F	Lymph node	Polymorphic B-cell hyperplasia, thymic hypoplasia	Ill-defined immune defect (*16*)
3	4 months	M	Brain, lymph node	Polymorphic B-cell hyperplasia, thymic hypoplasia	SCID (immunologically and clinically) BMT, LPS
4	8 months	F	Lymph nodes	Polymorphic B-cell lymphoma, thymic dysplasia	Immune defect mainly of the T-cell system
AIDS-associated lymphomas					
5	25 years	M	Lymph node	Immunoblastic lymphoma, T	Nodal lymphoma, AIDS
6	33 years	M	Waldeyer's ring	Burkitt's lymphoma	Extranodal lymphoma, AIDS
7	54 years	M	Waldeyer's ring	Unclassified lymphoma polymorph	Extranodal lymphoma, AIDS
8	31 years	M	Tonsil	Burkitt's lymphoma	Extranodal lymphoma, AIDS
9	31 years	M	Lymph node	Immunoblastic lymphoma, B	Nodal lymphoma, AIDS
10	33 years	M	Lymph node	Burkitt's lymphoma	Nodal lymphoma, AIDS
11	28 years	M	Lymph node	Burkitt's lymphoma	Nodal lymphoma, AIDS
12	44 years	M	Lymph node	Burkitt's lymphoma	Nodal lymphoma, AIDS
13	26 years	M	Lymph node	Burkitt's lymphoma	Nodal lymphoma, AIDS
14	38 years	M	Lymph node	Burkitt's lymphoma	Nodal lymphoma, AIDS
15	44 years	M	Small intestine	Large cell anaplastic	Extranodal lymphoma, AIDS
16	29 years	M	*os cribriforme*	Burkitt's lymphoma	Extranodal lymphoma, AIDS
17	39 years	M	Brain	Centroblastic lymphoma	Extranodal lymphoma, AIDS
18	45 years	M	Lymph node	Burkitt's lymphoma	Extranodal lymphoma, AIDS
African lymphomas (Rwanda and Uganda)					
19–26	Age, sex, and localization not always known			Burkitt's lymphomas	
Infectious mononucleosis					
27	3 years	F	Tonsils	Necrotizing polymorphic tonsillitis with lymphoid hyperplasia	
28	12 years	M	Lymph node	Lymphadenitis with follicular hyperplasia	
29	26 years	M	Tonsils	Acute tonsillitis	
30	52 years	M	Tonsils	Necrotizing lymphadenitis	
31	19 years	F	Tonsils	Acute tonsillitis	
32	16 years	F	Tonsils	Necrotizing tonsillitis	

[a] Age in years unless otherwise indicated.

ISH in all the cases already positive in blotting assays are listed in Table 2. In ISH studies two different patterns were found. In IM, the EBV-positive cells are distributed throughout the tissue section. Approximately 10 to 20% of the cells are labeled. These EBV-positive cells are often gathered around areas of necrosis. Still, the majority of the paracortical lymphoid tissue in IM cases remains unstained (Fig. 1).

The second pattern is found in classical endemic Burkitt's lymphomas. All tumor cells are labeled in a homogeneous way. Each cell shows about the same number of silver grains. Starry sky macrophages, adjacent structures, and vessels are not labeled and serve as an endogeneous negative control (Fig. 2). Of the EBV-positive AIDS-associated lymphomas, four have the homogeneous distribution pattern of EBV; in the three remaining AIDS lymphomas the EBV distribution resembles IM in that only some tumor cells are labeled intensively and that these cells are scattered. But also in the four lymphomas with a homogeneous EBV positivity there are some areas with a more scattered EBV distribution.

Four children with inborn immunodeficiencies and EBV-positive LPD had either polymorphic diffuse B-cell hyperplasia (PDBH) or polymorphic B-cell lymphoma (PBL). In both the PDBH or the PBL, the EBV pattern was heterogeneous throughout all the tissues investigated in each case. There were no differences between lymphoma and lymphoid hyperplasia. One PBL was monoclonal, the other polyclonal by immunophenotyping.

All endemic African Burkitt's lymphomas had the homogeneous pattern. These lymphomas were from malaria-free regions (Rwanda) as well as from regions with endemic malaria.

Primary Extranodal Lymphomas

From our sample of 539 cases, 37 primary lymphomas of the stomach and 7 primary lymphomas of the salivary glands were selected. Fourteen primary gastric lymphomas were of the mucosa-associated lymphoid tissue (MALT) type (*9*), 18 were high-grade non-Hodgkin lymphomas (NHL). A summary of investigations done and the results obtained is given in Table 3.

Gastric lymphomas were considered EBV positive

Table 2. Results of EBV-ISH in EBV-positive cases.

Case	Diagnosis	Pattern of EBV-ISH	
		Heterogeneous	Homogeneous
Children with immune defects			
1	SCID	+	−
2	Immune defect	+	−
3	SCID	+	−
4	Immunoblastic lymphoma	+	−
AIDS-associated lymphomas			
5	T-immunoblastic lymphoma	(+)[a]	+
6	Burkitt's lymphoma	(+)	+
7	Unclassified lymphoma	+	−
10	Burkitt's lymphoma	(+)	+
14	Burkitt's lymphoma	(+)	+
17	Centroblastic lymphoma	+	−
18	Burkitt's lymphoma	+	−
African lymphomas			
19	Burkitt's lymphoma	−	+
20	Burkitt's lymphoma	−	+
21	Burkitt's lymphoma	−	+
22	Burkitt's lymphoma	−	+
23	Burkitt's lymphoma	−	+
24	Burkitt's lymphoma	−	+
25	Burkitt's lymphoma	−	+
26	Burkitt's lymphoma	−	+
Infectious mononucleosis			
27–32	Necrotizing tonsillitis	+	−

[a] (+) Indicates that parts of the tumor show heterogeneous pattern.

when two assays (ISH and blotting) were positive. Briefly, there are hints that EBV may be present in some distinct extranodal NHL. This was found in a case with a high-grade NHL and proliferation with Hodgkin-like cells in the adjacent tissue (case 30003/86). In the surrounding of the lymphoma, ISH revealed few EBV-positive lymphoid cells. The nature of these cells remains to be determined. The seven lymphomas of salivary glands (two high-grade and five low-grade NHL) were negative for EBV.

T-Cell Lymphomas

In our material three cases of T-cell lymphomas were EBV positive. One case was a T-immunoblastic lymphoma occurring in AIDS (Table 1). A second case was from a young African woman who developed a rapidly growing anaplastic T-zone lymphoma. Finally, another T-immunoblastic lymphoma in a immunocompetent patient showed the presence of EBV-genome.

Discussion

In addition to classical EBV-associated lesions [Burkitt's lymphoma (BL), IM, nasopharyngeal carcinoma] other diseases of the lymphoid system seem to be related to EBV. Recently, the association of EBV with T-cell lymphomas in patients with chronic EBV infections (*4*) has been reported. We found EBV in two NHL of the T-phenotype where a chronic EBV infection has not been documented but could be supposed, one patient having an acquired immunodeficiency and the other patient coming from central Africa, a region with numerous environmental factors influencing the immune system. These findings suggest that T-cell tumors possess EBV DNA, which implies that T-cells support EBV-replication (*10*).

On the other hand, we presented some evidence for an involvement of EBV in the development of extranodal lymphomas. Primary extranodal lymphomas of the gastrointestinal tract have a histologically distinct

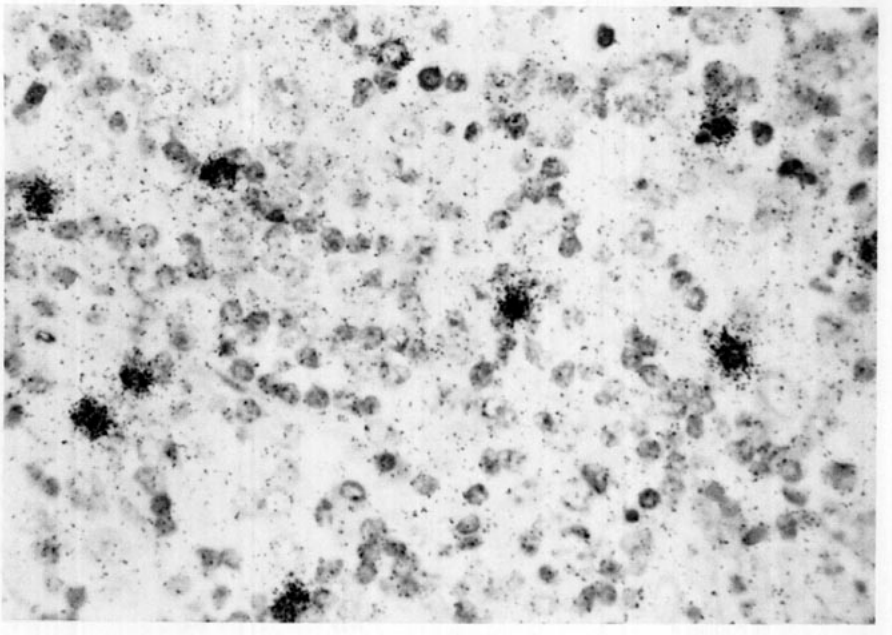

FIGURE 1. Paracortical lymphoid tissue in IM cases. *In situ* hybridization for EBV, ^{35}S-labeled probe, × 510.

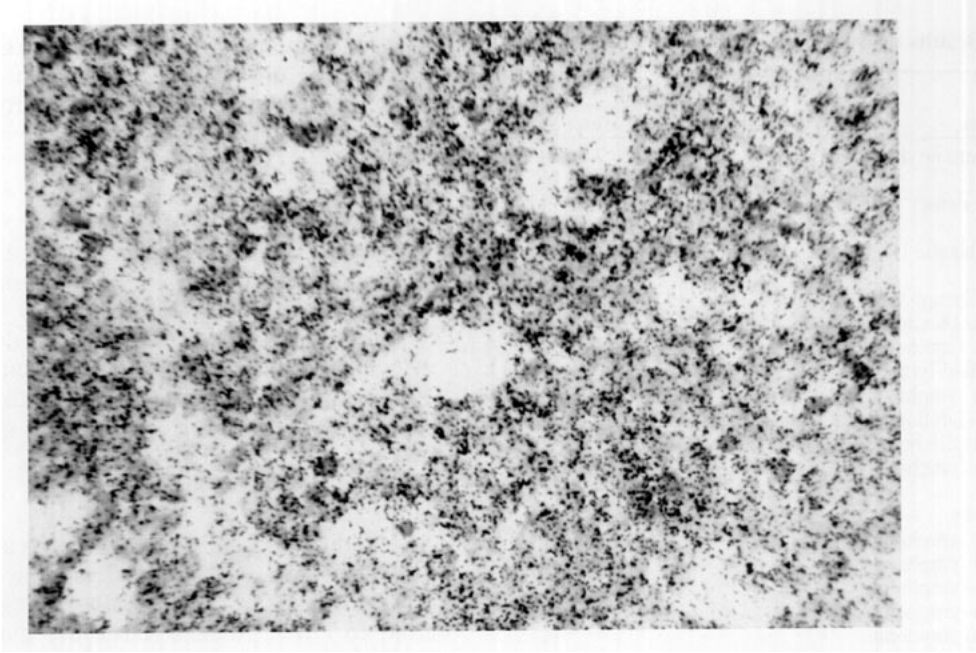

FIGURE 2. Starry sky macrophages in Burkitt's lymphoma. *In situ* hybridization for EBV, ^{35}S-labeled probe, × 510.

Table 3. Results of EBV studies in primary gastric lymphomas.

Case	Histologic diagnosis	EBV genome			
		dot W	dot H	Southern	ISH
H 30/86	MALT type	+	–	ND[a]	+
H 32/86	MALT type	+	ND	ND	–
H 14/86	Centroblastic	–	–	ND	–
H 359/86	LP immunocytoma	–	–	ND	–
H 1412/86	Centroblastic	+	–	ND	–
H 1580/86	Lymphoblastic	–	ND	ND	ND
18483/86	MALT type	–	–	ND	–
H 2244/86	LP Immunocytoma	+	+	ND	ND
H 2245/86	Immunoblastic-B	+	–	ND	–
30003/86	Centroblastic and HD	+	+	+	+
H 183/87	LP immunocytoma	–	ND	ND	–
H 274/87	Centroblastic	–	–	ND	–
H 588/87	Early phase of high-grade NHL	–	ND	ND	–
H 640/87	MALT type	+	+	ND	(+)
H 2125/87	MALT type	–	–	ND	–
H 1923/87	MALT type	–	ND	ND	–
H 2869/87	Centroblastic	–	–	ND	–
H 2951/87	MALT type	–	ND	ND	–
H 3036/87	MALT type	–	ND	ND	–
H 3229/87	MALT type, early	–	–	ND	ND
9730/87	Centroblastic	ND	ND	–	ND
16928/87	Centroblastic	ND	ND	–	ND
30666/87	Centroblastic	ND	ND	–	ND
H 26/88	MALT type	–	ND	ND	–
H 71/88	T-lymphoma, early	–	–	ND	–
H 121/88	Centroblastic	–	ND	ND	–
H 922/88	Centroblastic	–	ND	ND	–
H 995/88	Centroblastic	–	ND	ND	–
H 1007/88	MALT type	–	ND	ND	–
H 1047/88	MALT type	–	ND	ND	–
H 1140/88	MALT type	–	ND	ND	–
H 1261/88	Immunoblastic-B	–	ND	ND	–
H 1262/88	MALT type	–	–	ND	–
H 1308/88	Centroblastic	–	ND	ND	–
13847/88	Centroblastic	ND	ND	–	ND
17668/88	Centroblastic	ND	ND	–	–
6544/89	MALT type	ND	ND	–	–

[a] ND, not determined.

pattern (*9*) that has been called malignant lymphoma of mucosa-associated lymphoid tissue (MALT) because the accepted classifications of NHL were difficult to apply to these tumors. The main component of these lymphomas is the centrocytelike cell (CCL), of which the benign equivalent is characterized by a surface phenotype IgM^+, IgA^+, CD 22^+, CD 23^-, CD 5^-, and they are positive for both CD 35 (CR1) and CD 21 (CR2), the B-lymphocyte EBV receptor (*11*). We are actually investigating different forms of chronic gastritis with a preponderance of lymphoid cells for the presence of EBV or viral proteins. Up to now, we have found one case of EBV-positive gastric lymphoma, and so there may be a link between MALT lymphocytes, EBV, and the development of certain lymphomas. The fact that we have only demonstrated EBV in one case of gastric lymphoma could also be a question of sensitivity. Recently, Saito et al. (*12*) clearly demonstrated EBV DNA in tissue biopsies from patients with Sjögren's syndrome, a condition associated with the development of lymphoid tissue in salivary glands and increased frequency of NHL in these patients using the polymerase chain reaction. Using a more sensitive method, the frequency of EBV in primary extranodal lymphoma and MALT tissue could be higher than is found with normal blotting techniques.

In lymphomas and LPD of children with immunodeficiencies, as well as in lymphomas of patients with AIDS, we demonstrated two different patterns: one pattern could be called the IM-like pattern and the other one the BL-like pattern. The interpretation of these findings recalls the findings of studies with BL and lymphoblastoid cell lines (LCL) cell lines. LCL are derived from the peripheral blood of normal seropositive donors. LCLs differ from BL lines in a number of phenotypic characteristics. The LCLs represent the most likely counterpart of the EBV-transformed blasts that proliferate in IM (*13*). BL cells may represent the neoplastic counterpart of latently infected normal B-cells with a corresponding phenotype. The differences consist mainly in viral gene expression and B-cell marker expression. BL cells only express EBNA 1 and CALLA and BLA, whereas LCLs express the full set of EBNA 1–6 and LMP as well as B activation markers (*14*). Our finding of two different EBV genome patterns may reflect these two EBV-carrying cell types: the more homogeneous expression of EBV would then be related to the BL phenotype; the scattered distribution occurs when LCL-like cells are the predominant cell in the lesion. This hypothesis could be tested by extensive studies on viral gene expression and marker studies.

The acute phase of IM is comparable to a chaotic attack of specific and nonspecific killer cells against a multitude of rapidly multiplying EBV-carrying B-blasts (*14*). Our observation of an IM-like pattern in PBL and PDBH may be a further indication that the disease process in these cases is an overwhelming reaction to EBV rather than an overwhelming infection (*15*).

The fact that EBV-positive AIDS lymphomas have either IM-like or BL-like pattern indicates that there may be two different groups of EBV lymphomas in AIDS. It would be of interest to compare the clinical outcome of the two lymphoma groups with diverging EBV patterns.

REFERENCES

1. Purtilo, D. T., Okano, M., and Grierson, H. L. Immune deficiency as a risk factor in Epstein-Barr virus-induced malignant diseases. Environ. Health Perspect. 88: 225–230 (1990).
2. Ziegler, J. L., Magrath, I. T., Gerber, P., and Levine, P. H. Epstein-Barr virus and human malignancy. Ann. Intern. Med. 86: 323–336 (1977).
3. Weiss, L. M., Strickler, J. G., Warnke, R. A., Purtilo, D. T., and Sklar, J. Epstein-Barr viral DNA in tissues of Hodgkin's disease. Am. J. Pathol. 129: 86–91 (1987).
4. Jones, J. F., Shurin, S., Abramowsky, C., Tubbs, R. R., Sciotto, C. G., Wahl, R., Sands, J., Gottman, D., Katz, B. Z., and Sklar, J. T-cell lymphomas containing Epstein-Barr viral DNA in patients with chronic Epstein-Barr virus infections. N. Engl. J. Med. 318: 733–741 (1988).
5. Fox, R. I., Pearson, G., and Vaughan, J. H. Detection of Epstein-Barr virus-associated antigens and DNA in salivary gland biopsies from patients with Sjogren's syndrome. J. Immunol. 137: 3162–3168 (1986).
6. Maniatis, T., Fritsch, E. F., Sambrook, J. Molecular Cloning. A Laboratory Manual. Cold Spring Harbor Laboratory, Cold Spring Harbor, NY, 1982.
7. Goelz, S. E., Hamilton, S. R., and Vogelstein, B. Purification of DNA from formaldehyde fixed and paraffin embedded human tissue. Biochem. Biophys. Res. Commun. 130: 118–126 (1985).
8. Frizzera, G., Hanto, D. W., Gajl-Peczalska, K. J., Rosai, J., McKenna, R. W., Sibley, R. K., Holahan, K. P., and Lindquist, L. L. Polymorphic diffuse B-cell hyperplasia and lymphomas in renal transplant recipients. Cancer. Res. 41: 4262–4279 (1981).
9. Isaacson, P., and Wright, D. H. Malignant lymphoma of mucosa-associated lymphoid tissue. Cancer 52: 1410–1416 (1983).
10. Stevenson, M., Volsky, B., Hedenskog, M., and Volsky, D. J. Immortalisation of human T-lymphocytes after transfection of Epstein-Barr virus DNA. Science 233: 980–984 (1986).
11. Fingeroth, J. D., Weis, J. J., Tedder, T. F., Strominger, J. L., Biro, P. A., and Fearon, D. T. Epstein-Barr virus receptor of human B lymphocytes is the C3d receptor CR2. Proc. Natl. Acad. Sci. USA 81: 4510–4514 (1984).
12. Saito, I., Servenius, B., Compton, T., and Fox, R. I. Detection of Epstein-Barr virus DNA by polymerase chain reaction in blood and tissue biopsies from patients with Sjögren's syndrome. J. Exp. Med. 169: 2191–2198 (1989).
13. Klein, G., Svedmyr, E., Jondal, M., and Persson, P. O. EBV-determined nuclear antigen (EBNA)-positive cells in the peripheral blood of infectious mononucleosis patients. Int. J. Cancer 17: 21–26 (1976).
14. Klein, G. Viral latency and transformation: the strategy of Epstein-Barr virus. Cell 58: 5–8 (1989).
15. Kornstein, M. J., Weber, J., Luck, J. B., Massey, G. V., Strom, S., and McWilliams, N. Epstein-Barr virus-associated lymphoproliferative disorder. Applications of immunoperoxidase and molecular biologic techniques. Arch. Pathol. Lab. Med. 113: 481–484 (1989).
16. Virelizier, J. L., Lenoir, G., and Griscelli, C. Persistent Epstein-Barr virus infection in a child with hypergammaglobulinemia and immunoblastic proliferation associated with a selective defect in immune interferon secretion. Lancet ii: 231–234 (1978).