Environmental Health Perspectives
Vol. 89, pp. 27-33, 1990

Toxic Effects of Lead on Neuronal Development and Function

by Robert Freedman,* Lars Olson,† and Barry J. Hoffer‡

The effects of lead on the development of the nervous system are of immediate concern to human health. While it is clear that lead can affect neuronal development at levels of exposure within the range found in the environment, the particular mechanism of the disruption is not readily ascertained. Lack of knowledge of the mechanism of lead-induced damage hampers its treatment and prevention. The goal of our research is to develop a model system in which the effects of lead on central nervous system development can be demonstrated. The complexity of the brain hampers such investigations because often it is not clear if apparent toxic effects represent changes secondary to somatic changes, such as endocrine or hematological defects, that could alter brain development, or even transneuronal effects caused by toxicity at a distal site that deprives a brain area of a synaptic input needed for its proper development. A related problem is the redundancy of compensatory systems in the brain. Such systems may disguise the severity of the initial toxic insult and themselves can cause functional disturbances.

To study neuronal development in a system that minimizes such difficulties, we have grafted discrete brain regions derived from rat fetuses into the anterior chamber of the eye of adult hosts. The brain pieces continue organotypic development in the eye, but are isolated from possible secondary changes due to alterations in the development of the endocrine and other somatic systems because the adult host has these systems already fully developed. Similarly, effects mediated by connecting brain areas are minimized since the transplant is isolated in the anterior chamber of the eye. Using this system, we have discovered that lead induces a hypernoradrenergic innervation of central nervous system tissue. The increased innervation is observed not only structurally, but also functionally. Since norepinephrine is an inhibitory neurotransmitter, this ingrowth may explain the profound slowing of discharge of cerebellar neurons recorded in grafts of lead-treated animals. Studies in other tissues suggest that increased axonal ingrowth may be a general problem of lead intoxication that encompasses many brain areas, as well as peripheral sympathetic systems. Syndromes such as hyperactivity might be the behavioral consequence of these alterations in neuronal development.

Introduction

Recent studies combining the techniques of neuropsychology, inorganic analytic chemistry, and epidemiology have provided important new insights into adverse effects of low-level lead exposure on the developing central nervous system. Perinatal exposure yielding blood levels of 300 to 600 μg/L, documented by measurements in body fluids or tissue, has been shown to result in clearcut behavioral, neuropsychological, and electroencephalographic abnormalities (*1–7*). While the mechanisms of these lead-induced changes are unclear and may be influenced by many other factors, such as nutrition (*8*) and the particular test paradigms used (*9*), the widespread environmental burden of this heavy metal provides a strong impetus for further experimentation.

Homologous transplantation of fetal rat brain tissue to the anterior chamber of the eye is a useful method for studying potentially deleterious effects of heavy metals on defined areas of the developing central nervous system. One specific advantage of the grafting technique is that graft and host brain will share the same circulation and therefore be exposed to similar blood concentrations of lead for identical time periods. It thus becomes possible to compare effects of lead on any given transplanted area of the brain that has been exposed to lead during development with the corresponding area of the host brain, exposed to the same lead levels, but only in the adult state. A second advantage of the graft is its relative isolation. Thus, lead-induced deficits cannot be compensated by alterations in afferent input or reorganizations involving other brain areas. An additional advantage of the graft is its small size. Most grafts are 3 to 15 mm^3 in volume. This facilitates an extensive histological and physiological analysis of a definite brain region, a task difficult to achieve *in situ*.

In following sections, we will present specific examples of how lead exposure causes an increased adrenergic fiber outgrowth in the anterior chamber of the eye; how this may result in altered physiology of developing cerebellar grafts *in oculo*; and how similar, albeit more modest, changes can be observed *in situ* after lead administration.

*Departments of Psychiatry and Pharmacology, Denver Veterans Administration Medical Center, Denver, CO 80262.
†University of Colorado Health Sciences Center, Denver, CO 80262.
‡Department of Histology, Karolinska Institute, Stockholm, Sweden.
Address reprint requests to R. Freedman, Departments of Psychiatry and Pharmacology, Denver Veterans Administration Medical Center, Denver, CO 80262.

Results

Actions of Lead on the Adrenergic Ground Plexus of the Iris

Injections of 5 μL of a 1.4 mM solution of lead acetate (PbAc) into the anterior chamber of the eye caused a significant adrenergic hyperinnervation of the irides as compared to sodium acetate (NaAc)-treated control irides. Increasing the dose of lead by giving 7 or 42 mM PbAc solutions did not significantly increase the extent of the hyperinnervation. Even at these high concentrations, lead caused minimal morphological changes of the individual fibers in the sympathetic ground plexus. The fluorescence intensity of the nerve fibers was normal or slightly below normal. It is important to note that injection of sodium acetate into the eye chamber caused a mild hyperinnervation of the iris (Fig. 1*a*), but lead acetate caused an even larger degree of hyperinnervation. The time course shown in Figure 1 indicates that the lead-induced hyperinnervation is completed in 3 days and remains stable for at least 2 weeks. When data from the last three time points are combined, the effect of 1.4 mM PbAc is significant at the $p < 0.001$ level, as is the effect of 42 mM PbAc (Fig. 1*a*). In the lead-treated irides, irregular bundles of fluorescent sympathetic axons not normally seen were also present. It was also obvious that the higher lead concentrations caused a slight inflammatory reaction in the irides as they were sometimes swollen and contained macrophages.

In sharp contrast to lead, mercury caused marked degeneration of adrenergic nerves (Fig. 1*b*). The time course of this change was followed using 3.5 mM mercury chloride solutions (Fig. 1*c*). Nerves began to degenerate and disappear within 24 hr after injection. At this time point, most nerves had disappeared in some irides, leaving only the preterminal axon bundles that reach the dilator plate through the choroid membrane and ciliary body. Such axon bundles contained axons with terminal swellings and increased beading. Other irides showed only patches of degenerated plexus while the rest of the sympathetic nerves were thinner, smoother, and had a lower fluorescence intensity than normal. At 3 days, mercury-treated irides had only 35% of the nerve fibers normally found (Fig. 1*c*). In some irides, however, signs of recovery were apparent at this time point. In such cases, nerve terminals were varicose and thus had a more normal morphology than at day 1. There were also signs of regenerative sprouting from the cut axon bundles. After 2 weeks postinjection, the mean nerve density had recovered to almost 80%, showing a significant regenerative sprouting from the remaining nerve plexus. The reconstituted adrenergic ground plexus had a clearly abnormal organization, however, characterized by more axon bundles and straighter running intersecting terminals.

The changes of adrenergic nerve density caused by 1.4 mM lead were confirmed by an independent technique in one experiment wherein irides were incubated in labeled noradrenaline before fluorescence microscopy (Fig. 2). Transmitter uptake into lead-treated irides was 133 ± 7% (n = 9) and in NaAc-injected irides was 115 ± 5% (n = 9) as compared to noninjected controls (100 ± 6%; n = 6).

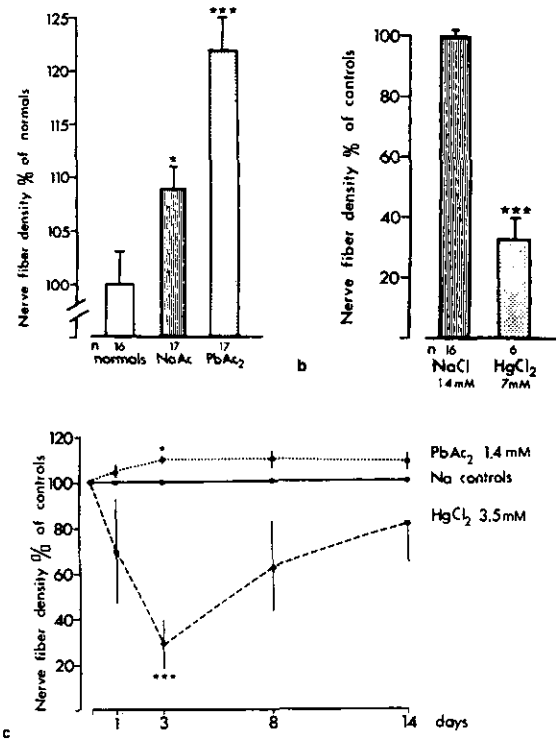

FIGURE 1. Semiquantitative estimations of changes in adrenergic nerve density in irides following intraocular lead or mercury injections, *(a)* The effects, on an extended scale, of 1.6 mg/mL of NaAc (middle bar) or PbAc (right bar) 5 days after treatment. Values are given as mean ± SEM as percent of normal. PbAc is highly significantly ($p < 0.001$) different from both NaAc and normal. NaAc is significantly ($p < 0.05$) higher than normal. *(b)* Degenerative effects of a high dose of mercury chloride (right bar) as compared to sodium chloride (left bar) 7 days after treatment. The difference is highly significant ($p < 0.001$). It is probable that some regeneration of adrenergic nerve terminals has already occurred (see Fig. 1*c*). *(c)* Time course of changes in density of adrenergic nerves following intraocular lead or mercury injections as compared to corresponding controls. A low dose of lead causes a moderate hyperinnervation reaching significance 3 days after treatment. When the values from 3 to 14 days are combined, the lead-induced hyperinnervation is highly significant ($p < 0.001$). Conversely, a moderate dose of mercury causes extensive degeneration of adrenergic nerves, reaching a maximum around day 3 ($p < 0.001$). At day 14, substantial regeneration of nerve terminals has occurred, making this value significantly larger than the day 3 value ($p < 0.05$). Mean ± SEM of 5 observations (Pb and Hg) or 10 observations (5 NaCl + 5 NaAc controls).

The difference between noninjected controls and lead-treated animals is clearly significant; the difference between lead and NaAc animals is of borderline significance. The sodium acetate group did not significantly differ from the noninjected controls.

Effects of Chronic Lead on Intraocular Transplants

One percent lead acetate in the drinking water was tolerated well by the recipient rats. Blood levels of 450 to 500 mg/L were elicited by this dose. There were no gross

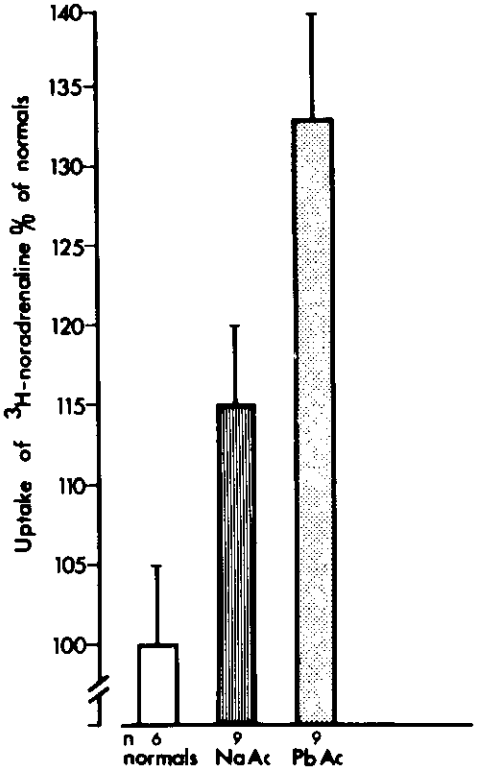

FIGURE 2. Effect of lead on uptake of [^{3}H]-noradrenaline in rat iris following intraocular injection of 1.4 mM PbAc (right bar) or 2.8 mM NaAc (middle bar). Animals were sacrificed 3 days after treatment. The lead-treated group is significantly different from normals ($p < 0.01$); the difference between the lead and sodium group is borderline significant. The difference between the NaAc-treated and normal is nonsignificant.

neurological disturbances. In a few experiments, 2% PbAc was used. This lead concentration in the drinking water reduced the weight gain of recipient animals considerably. In general, lead treatment of the host had no adverse effects on the process of endothelial budding and vascularization of the transplants from the host iris. There were no petechial hemorrhages or delays of vascularization.

The cerebellar anlage was chosen for our initial grafting experiments because the cerebellum has been reported to be especially sensitive to lead intoxication. It is in the cerebellum of developing animals that one first finds hemorrhages after very high-level intoxication (*10*). The cerebellar bud was grafted from two prenatal stages of development: 14 days of gestation, at which stage control grafts will show vigorous growth *in oculo*, and 16 days of gestation, when grafts will reach a final size *in oculo* that does not exceed the size when grafted. As can be seen from Figure 3, there are no effects of 1% lead on cerebellar transplant growth at either of the two stages. Moreover, as noted above, there were no petechiae or other disturbances of the vasculature of the developing cerebellar grafts. Preliminary studies indicate that the typical trilaminar histological organization of the cerebellar cortex seen in control grafts (*11*) is intact in lead-treated grafts, taken at either prenatal stage.

Cerebellar grafts in NaAc-treated rats showed Purkinje cell spontaneous activity indistinguishable from that seen in normal animals. A total of 30 neurons were recorded from four grafts, all with urethane (1.0–1.25 g/kg) anesthesia. The cells in all four grafts had a sustained spontaneous discharge with an average rate of 25.8 ± 2.4 Hz. Action potential tracings, interspike interval histograms, and rate meter records for three typical cells from three different grafts are shown in Figures 4 and 5. The regularity of the discharge pattern is indicated by the prominent model peak in the histogram. The distribution of firing rates for these animals is indicated in Figure 6.

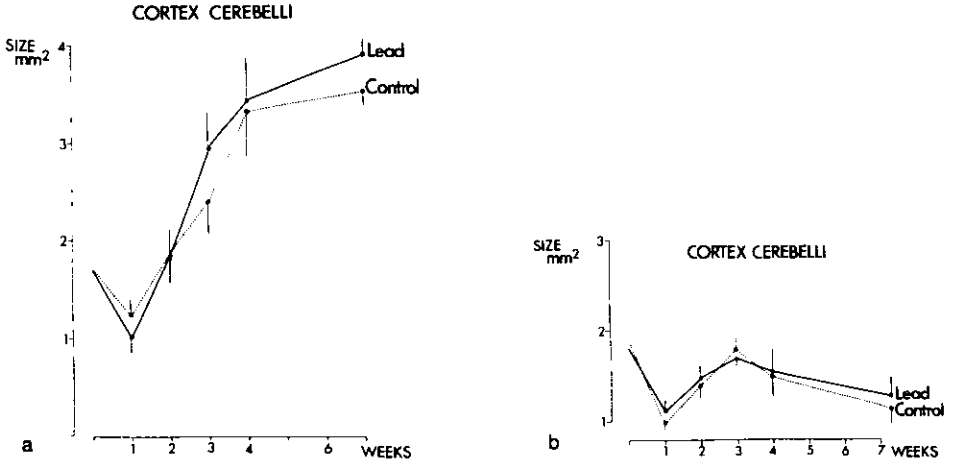

FIGURE 3. Effects of chronic 1% PbAc on growth of the cerebellar anlage *in oculo*. Cerebellar grafts were taken from fetuses with a crown rump length of 11 to 12 mm corresponding to gestational days 14 (*a*), and 15 to 17 mm, gestational days 16 to 17 (*b*). Grafts from more immature donors grew to larger final sizes. There were no significant effects of lead on growth in either of the two groups. (*a*) n = 19 to 24; and (*b*) 21 to 28.

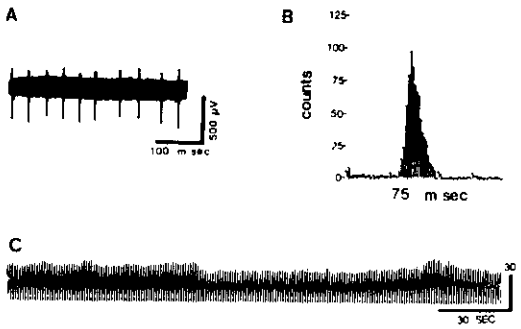

FIGURE 4. Spontaneous discharge from a single Purkinje cell in a NaAc-treated animal. (*A*) Action potential record photographed from the oscilloscope. (*B*) Interspike interval histogram with prominent model peak indicating regularity of discharge. Abscissa calibration is for full scale. (*C*) Rate meter record again showing sustained regular discharge.

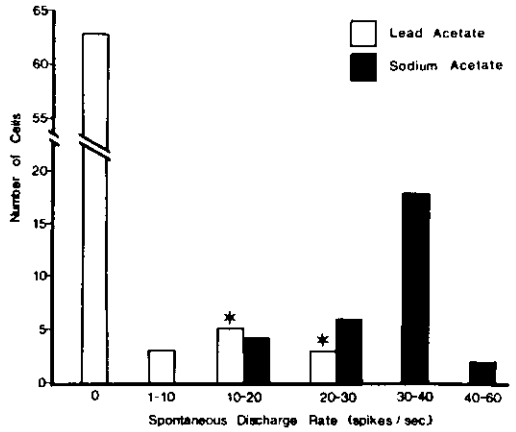

FIGURE 6. Histogram of spontaneous discharge rates in Purkinje neurons from PbAc-treated (open bars) and NaAc-treated (filled bars) cerebellar grafts. Differences in the two groups are significant, with $p < 0.001$. Asterisk (*) indicates data from cells from the only lead-treated graft containing spontaneously active Purkinje neurons.

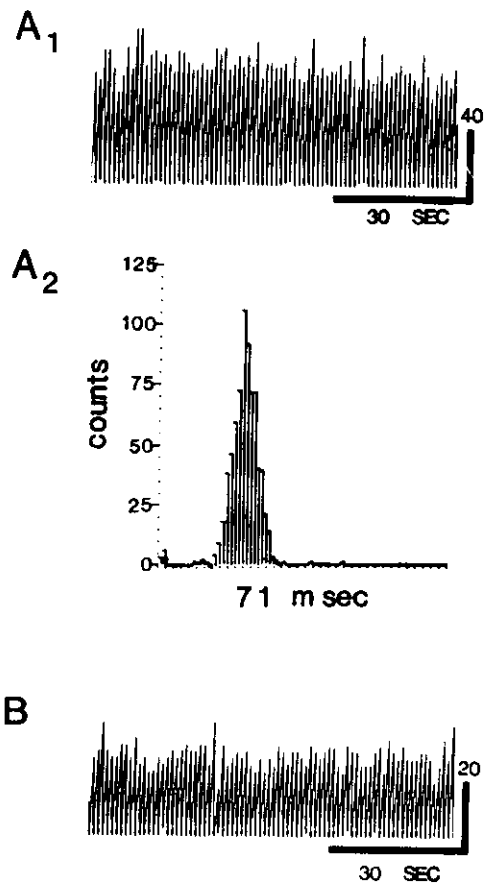

FIGURE 5. Spontaneous discharge of Purkinje cells from cerebellar grafts in two NaAc-treated rats. (A_1) Rate meter and (A_2) interspike interval histogram from a cell showing a sustained rapid discharge rate. (*B*) Rate meter showing a slower but still regular discharge rate in the second Purkinje neuron.

In sharp contrast, Purkinje cells in grafts from PbAc-treated animals showed almost no spontaneous activity (Fig. 6). A total of 20 grafts in 13 animals were studied. Urethane (0.4–0.7 g/kg) was used for 18 grafts, and halothane (0.5%) was employed for 2 grafts. These lower doses of anesthetic were necessitated by the greater sensitivity of the PbAc-treated rats to anesthetic-induced respiratory depression, which we observed in our initial experiments. A total of 63 Purkinje neurons in 18 of the grafts (16 with urethane and 2 with halothane) were totally silent except when mechanically stimulated by the electrode tip or when excited by perfusion of penicillin (Fig. 7). In one graft, three cells were found which discharged initially but became silent after 3 to 4 min. Only in one graft were Purkinje neurons recorded with a discharge pattern which resembled that seen normally (Fig. 6). A total of eight cells were found in this transplant with an average discharge rate of 21.1 ± 3.1 Hz. The distribution of discharge rates for the lead-treated rats is shown in Figure 6.

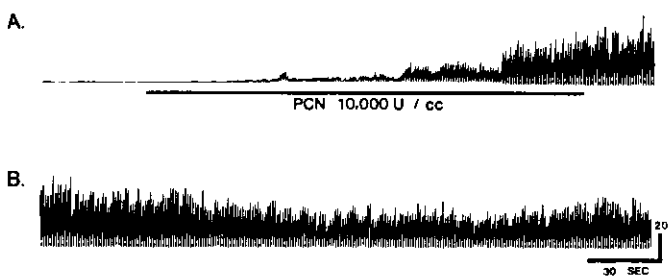

FIGURE 7. Rate meter records of Purkinje neuron discharge from a single cell in a lead-treated animal. Note the absence of spontaneous discharge (*A*). After superfusion of 10,000 units/cc penicillin (PCN), a regular discharge is induced that persists after penicillin superfusion is discontinued (*B*). Records (*A*) and (*B*) are contiguous in time. Similar responses to PCN were seen in neurons in two other lead-treated grafts.

To control for any systemic depressant effects in the lead-treated animals, the host animals' cerebellum was studied in the 12 animals bearing the 18 "silent" grafts. In all cases, vigorous, sustained Purkinje cell spontaneous discharge was seen, similar to our previous studies (*12*). The discharge rate for 72 host Purkinje cells (at least 5 per animal) was 34.1 ± 2.7 Hz. Again, the interspike interval histograms manifested regular, normally appearing discharge patterns.

Effects of Postnatal Lead Exposure on Cerebellar Purkinje Neurons and Adrenergic Innervation *in Situ*

In view of the striking hypoactivity of cerebellar Purkinje neuron discharge seen in the intraocular cerebellar grafts that matured in host animals receiving lead in their drinking water, experiments were designed to see if these results could be generalized to the developing brain in an intact organism. The mean spontaneous firing rate of cerebellar Purkinje neurons was found to be significantly lower in adult animals that received 8 mg PbAc/kg body weight during their first 20 days of life than in animals that received either 1 mg PbAc or 8 mg NaAc/kg body weight (Fig. 8). Moreover, the distribution of the firing rates of the Purkinje cells differed; there was a preferential loss of faster firing cells in the 8 mg PbAc/kg body weight group. This hypoactivity was not due to reduced weight gain since animals malnourished via increased litter size manifested normal electrical activity of Purkinje cells.

In an effort to establish whether lead-induced adrenergic hyperinnervation could also be seen *in situ*, rat pups were exposed to PbAc or NaAc postnatally for 20 days. Cortical smears were subsequently taken from animals after maturation, and the density of noradrenergic terminals was compared in the two groups by fluorescence histochemical measurements. As shown in Figure 9, all three cortical regions sampled showed increased norepinephrine varicosities in the lead-treated animals. In a parallel fashion, levels of norepinephrine in cortex, as measured by HPLC, are also modestly elevated after perinatal lead exposure.

Discussion

The data in this communication demonstrate that chronic lead treatment produces profound changes in cerebellar transplant electrophysiology. These are seen in the absence of any alterations in cerebellar graft morphology or gross histological organization. In addition, the brain of the adult host animal does not develop lead-induced electrophysiological abnormalities. Previous animal investigations also have suggested that the developing brain is selectively sensitive to blood and tissue lead levels that are similar to those obtained in the present investigation. For example, exposure of the neonate to low-level lead results in marked changes in central nervous system responsiveness to visual stimulation (*3*), alterations in seizure responses (*13*), delayed maturation (*14*), and behavioral abnormalities (*2,7,15*); adult animals in these studies showed no changes after chronic low-level lead treatment.

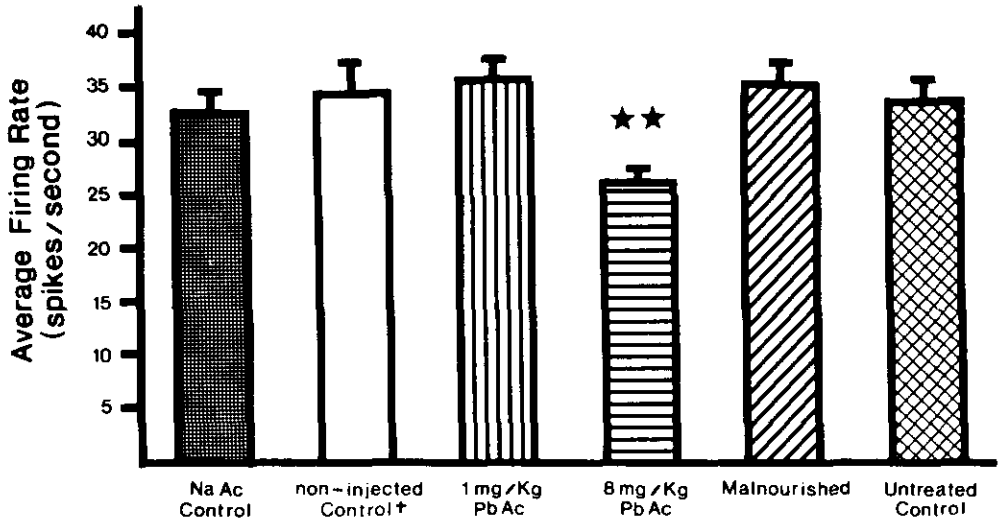

FIGURE 8. Bar graph showing mean discharge rate ± SEM of cerebellar Purkinje neurons from animals injected postnatally with NaAc, 1 mg PbAc/Kg, 8 mg PbAc/Kg, and noninjected controls. In addition, the mean firing rates of Purkinje neurons from malnourished animals and from animals concomitantly raised in normal-sized litters are illustrated. The rates in 8 mg PbAc/kg animals are significantly different from those of NaAc animals ($p < 0.01$).

Routine histological examination of cerebellar grafts, using a variety of parameters, indicated no obvious differences in lead-treated versus NaAc-treated grafts. Similarly, we have observed no differences in growth, determined by serial measurements of surface area of cerebellar grafts *in oculo* as a function of this type of lead exposure (*16*). Indeed, the literature on lead exposure in this dose range has shown little evidence of induced histological abnormalities, either in man or in animal models (*17*). It must be cautioned, however, that no cytochemical studies to localize transmitter-specific cells or fibers were carried out in these previous studies. It has been previously demonstrated that adrenergic and cholinergic fibers from the autonomic ground plexus of the iris provide a functional input to cerebellar grafts (*18*). The density of adrenergic afferent input is, in fact, altered by chronic lead treatment.

The most striking finding from our study is the absence of spontaneous activity in transplanted Purkinje cells from lead-treated animals. NaAc-treated grafts, in contrast, showed a spontaneous Purkinje cell discharge indistinguishable from that found normally. Several considerations argue against this effect of lead as secondary to some nonspecific local or systemic toxicity. First, as noted above, there were no routine histological abnormalities in the lead-treated transplants, either in terms of cell numbers, cell appearance, or laminar organization. Second, even though there was little spontaneous discharge of the Purkinje cells, sustained regular firing could be elicited in several instances by transient application of an excitatory agent, such as penicillin. Finally, Purkinje cell activity was normal in the host cerebellum of all lead-treated animals. A previous study has demonstrated that 9- to 90-day-old rat pups with neonatal blood lead levels of 500 to 750 μg/L did not generate normal electrophysiological responses in occipital cortex to visual stimuli (*3*). Evoked field potentials in these animals were either lacking or of longer latency and altered waveform as compared to nonlead-treated neonate controls or to adult lead-treated animals. Thus, the absence of activity in lead-treated grafts probably represents a specific and long-lasting interaction of this metal with the neuronal circuitry within the developing graft.

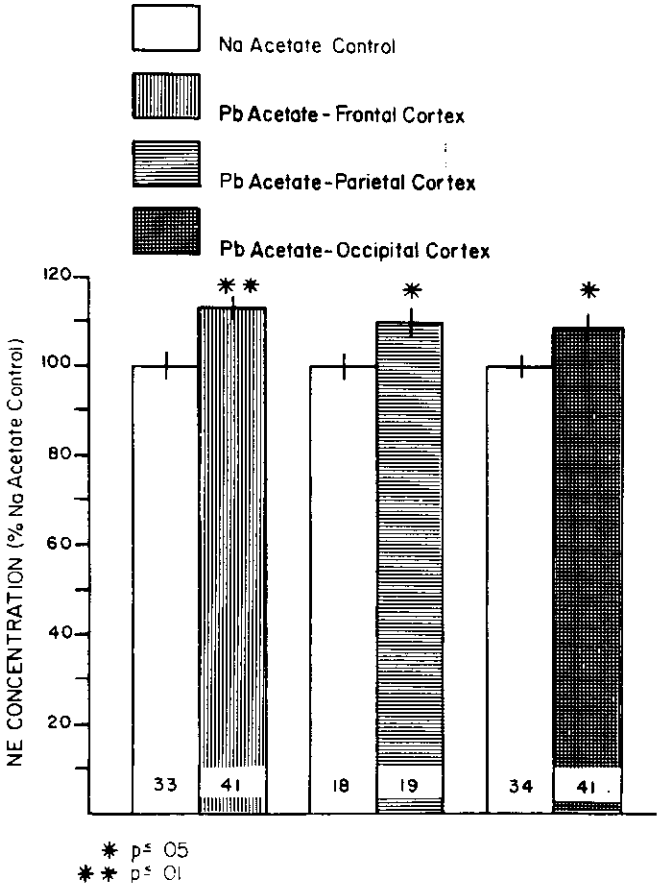

FIGURE 9. Cortical noradrenergic varicosities in animals treated neonatally with PbAc or NaAc. Estimates were made by blind observers using Falck-Hillarp fluorescence histochemical techniques. Note elevation in lead-treated animals in all three cortical regions.

Interestingly, although lead-induced changes in motricity have been reported in both animal models (*19–22*) and in man (*5,6,23,24*) after perinatal exposures yielding blood levels of 400 to 600 μg/L, these changes have involved the general level of motor activity rather than specific cerebellar functional deficits. It is possible that, in the intact animal, direct effects of lead on cerebellar activity are compensated by changes in afferent input from other brain areas. Such "plastic" changes have been demonstrated after lesions in many brain regions, using both anatomical and physiological parameters (*25,26*). Of course, such compensatory mechanisms would not be operative in the graft. It is not clear, then, whether the electrophysiological differences reported here between graft and host Purkinje cells are due to lead exposure in the developing versus mature brain, or due to lead exposure in a brain graft versus brain *in situ* with consequently different lead levels (*27*).

The present study reveals that lead causes an increased adrenergic nerve fiber density. Lead has previously been found to increase noradrenaline levels in the central nervous system of immature animals (*28*). Whether this increase is due to a change in the biochemistry of the noradrenergic neurons or an augmentation of growth is unclear. Our present findings show that lead can stimulate growth of mature peripheral sympathetic nerves. If lead does promote significant growth of central noradrenergic nerves in a similar fashion, this might be one of the factors behind the suggested lead-induced hyperactivity in children (*29*).

REFERENCES

1. Burchfiel, J., Duffy, F., Bartels, P. H., and Needleman, H. L. Combined discriminating power of quantitative electroencephalography and neuropsychologic measures in evaluating CNS effects of lead at low levels. In: Low Level Lead Exposure: The Clinical Implications of Current Research (H. L. Needleman, Ed.), Raven Press, New York, 1980, pp. 75–89.
2. Bushnell, P. J., and Bowman, R. E. Reversal learning deficits in young monkeys exposed to lead. Pharmacol. Biochem. Behav. 10: 733–742 (1979).
3. Fox, D. A., Lewkowski, J. P., and Cooper, G. P. Acute and chronic effects of neonatal lead exposure on development of the visual evoked

response in rats. Toxicol. Appl. Pharmacol. 40: 449–461 (1979).
4. Landrigan, P. J., Balser, E., Whitworth, R., and Feldman, G. Neuroepidemiologic evaluation of children with chronic increased lead absorption. In: Low Level Lead Exposure: The Clinical Implications of Current Research (H. L. Needleman, Ed.), Raven Press, New York, 1980, pp. 17–33.
5. Needleman, H. L. Lead and neuropsychological deficit: finding a threshold. In: Low Level Lead Exposure: The Clinical Implications of Current Research (H. L. Needleman, Ed.), Raven Press, New York, 1980, pp. 43–51.
6. Needleman, H. L., Gunnoe, C., Leviton, A., Leed, R., Peresie, H., Maher, C., and Barrett, P. Deficits in psychologic and classroom performance of children with elevated dentine lead levels. N. Engl. J. Med. 300: 689–695 (1979).
7. Sobotka, T. J., Brodie, R. E., and Cook, M. P. Psychophysiologic effects of early lead exposure. Toxicology 5: 175–191 (1975).
8. Mahaffey, K., and Michaelson, I. A. Interaction between lead and nutrition. In: Low Level Lead Exposure: The Clinical Implications of Current Research (H. L. Needleman, Ed.), Raven Press, New York, 1980, pp. 159–200.
9. Mullenix, P. Effect of lead on spontaneous rodent behavior. In: Low Level Lead Exposure: The Clinical Implications of Current Research (H. L. Needleman, Ed.), Raven Press, New York, 1980, pp. 211–220.
10. Press, M. F. Lead encephalopathy in neonatal Long-Evans rats: morphologic studies. J. Neuropathol. 36: 169–195 (1977).
11. Hoffer, B., Seiger, Å., Ljungberg, T., and Olson, L. Electrophysiologi- and cytological studies of brain homografts in the anterior chamber of the eye: maturation of cerebellar cortex in oculo. Brain Res. 79: 165–184 (1974).
12. Woodward, D. J., Hoffer, B. J., and Lapham, L. W. Postnatal development of electrical and enzyme histochemical activity in Purkinje cells. Exp. Neurol. 23: 120–139 (1969).
13. Fox, D. A., Overmann, S. R., and Wooley, D. E. Neurobehavioral ontogeny of neonatally lead exposed rats. 2. Maximal electroshock seizures in developing and adult rats. Neurotoxicology 1: 149–170 (1979).
14. Overmann, S. R., Fox, D. A., and Woolley, D. E. Neurobehavioral ontogeny of neonatally lead exposed rats. 1. Reflex development and somatic indices. Neurotoxicology 1: 125–148 (1979).
15. Hastings, L., Cooper, G. P., Bornschein, R. L., and Michaelson, I. A. Behavioral effects of low level neonatal lead exposure. Pharmacol. Biochem. Behav. 7: 37–42 (1977).
16. Björklund, H., Olson, L., Seiger, Å., and Hoffer, B. J. Chronic lead and brain development. Intraocular brain grafts as a method to reveal regional and temporal effects in the central nervous system. Environ. Res. 22: 224–236 (1980).
17. Needleman, H. L., Ed. Low Level Lead Exposure: The Clinical Implications of Current Research. Raven Press, New York, 1980.
18. Taylor, D. A., Seiger, Å., Freedman, R., Olson, L., and Hoffer, B. J. Functional reinnervation of transplants in the anterior chamber of the eye by the autonomic ground plexus of the iris. Proc. Nat. Acad. Sci. USA 75: 1009–1012 (1978).
19. Sauerhoff, E. K., and Michaelson, I. A. Hyperactivity and brain catecholamines in lead exposed developing rats. Science 182: 1022–1024 (1973).
20. Silbergeld, E. K., and Goldberg, A. M. A lead-induced behavior disorder. Life Sci. 13: 1275–1283 (1973).
21. Silbergeld, E. K., and Goldberg, A. M. Lead-induced behavioral dysfunction: an animal model of hyperactivity. Exp. Neurol. 42: 146–157 (1974).
22. Silbergeld, E. K., and Goldberg, A. M. Pharmacological and neurochemical investigations of lead-induced hyperactivity. Neuropharmacology 14: 431–444 (1975).
23. David, O. J. Association between lower level lead concentrations and hyperactivity in children. Environ. Health Perspect. 7: 17–25 (1974).
24. David, O., Clark, J., and Voeller, K. Lead and hyperactivity. Lancet ii: 900–903 (1972).
25. Cotman, C. W. Neuronal Plasticity. Raven Press, New York, 1978.
26. Finger, S. Recovery from Brain Damage. Plenum Press, New York, 1978.
27. Björklund, H., Hoffer, B. J., Olson, L., and Seiger, Å. Differential morphological changes in sympathetic nerve fibers elicited by lead, cadmium, and mercury. Environ. Res. 26: 69–80 (1981).
28. Shih, T. M., and Hanin, I. Chronic lead exposure in immature animals: neurochemical correlates, a minireview. Life Sci. 23: 877–888 (1978).
29. Silbergeld, E. K., and Goldberg, A. M. Pharmacologic and neurochemical investigations of lead induced hyperactivity. Neuropharmacology 14: 431–444 (1975).