Environmental Health Perspectives
Vol 90, pp. 17-26, 1991

Neoplasms and Nonneoplastic Liver Lesions in Winter Flounder, *Pseudopleuronectes americanus*, from Boston Harbor, Massachusetts

by Robert A. Murchelano* and Richard E. Wolke†

A variety of neoplasms and nonneoplastic hepatic lesions have been noted in winter flounder, *Pseudopleuronectes americanus*, from Boston Harbor, Massachusetts. Inflammatory lesions include cholangiitis, pericholangiitis, pericholangial fibrosis, hepatitis, and pancreatitis. Necrotic lesions consist essentially of focal coagulative necrosis and a distinctive vacuolated cell lesion of the hepatic parenchyma. The most conspicuous and numerous proliferative lesion is macrophage aggregate hyperplasia and hypertrophy. Preneoplastic lesions include principally basophilic foci of cellular alteration and hepatocellular adenoma. Carcinomas consist of several morphologic varieties: hepatocarcinoma, cholangiocarcinoma, and anaplastic adenocarcinoma. The pathogenesis of the lesions observed is discussed with respect to anthropogenically introduced chemical contaminants and the resistant hepatocyte model of hepatocarcinogenesis. This study, and others of bottom-living food fish with enzootic neoplastic disease, warrants further evaluation, particularly with respect to possible bioaccumulation of chemical contaminants in edible tissues.

Introduction

Boston Harbor is located on the Massachusetts coast between Cape Ann and Cape Cod. The harbor is an indentation of Massachusetts Bay, and its outer limit is defined by a line from Winthrop in the northeast to Hull to the southwest. The harbor has a mean depth of less than 3 m and a surface area of approximately 114 km^2 (*1*). Salinity varies seasonally and is lowest in spring and highest in winter. Two deep shipping channels, President Roads and Nantucket Roads, enter the harbor from Massachusetts Bay. President Roads is in the northern part of the harbor, and Nantucket Roads is in the southern part. There are several other shipping channels, but none approximating the depths of the two primary channels.

Fresh water inputs to the harbor are numerous and include, from north to south, the Mystic, Charles, Neponset, Weymouth Fore, Weymouth Back, and Hingham Rivers. Freshwater introductions are largest during the spring and relatively minimal during other times of the year. Bottom sediments in the harbor vary depending on specific location and consist primarily of sand and mud. Relatively few areas of the harbor have a coarse, gravel bottom.

As is true of harbors adjacent to most large cities, Boston Harbor receives a variety of anthropogenic contaminants. Point sources for these materials include, in order of decreasing importance, sewage treatment plant discharges, combined sewer outfalls, and introductions of organic and inorganic chemical contaminants from innumerable industries bordering the harbor. Other sources of pollutants include land runoff (nonpoint source), introductions from shipping activities, and atmospheric fallout.

Specific determinations of the volumes of introduced material are difficult to obtain; however, inputs from the two sewage treatment plants at Deer Island (north) and Nut Island (south) have been calculated (*2*). The Deer Island plant processes domestic and industrial wastes of communities to the north of Boston, and the Nut Island plant processes waste of communities to the south of the city. The combined inflows of these two plants approximate 500 million gallons per day (mgd). The Deer Island plant accounts for 343 mgd and the Nut Island plant 112 mgd. Together the inflow of these two plants exceeds that of all other rivers entering the harbor excepting the Mystic and Charles Rivers. Both treatment plants discharge predominantly primary-treated sewage into the adjacent deep shipping channels during ebbing tides.

The harbor contains a variety of marine fish and shellfish resources. The most commercially important species include softshell clams, *Mya arenaria*; lobsters, *Homarus americanus*; and flatfish, *Pseudopleuronectes americanus* (*3*). Direct marketing of softshell clams is resticted to clams obtained from specific uncontaminated areas. In some areas of the harbor, clamming is restricted to master fishermen, and clams must be

*National Marine Fisheries Service, Northeast Fisheries Center, Woods Hole Laboratory, Woods Hole, MA 02543.
†Comparative Aquatic Pathology Laboratory, East Farm, University of Rhode Island, Kingston, RI 02881.
Address reprint requests to R. A. Murchelano, National Marine Fisheries Service, Northeast Fisheries Center, Woods Hole Laboratory, Woods Hole, MA 02543.

depurated before marketing. Depuration involves holding clams in ultraviolet light-treated seawater to lower numbers of coliform bacteria to meet public health standards. Lobsters are trapped throughout the harbor and are marketed directly. There is no legal commercial fishing for winter flounder in the harbor; however, there is a substantial recreational fishery for the species.

Shellfish species with diseases believed to be associated with pollution include both softshell clam and lobster. A hemoproliferative disease (sarcoma) has been noted in the softshell clam (*4*), and exoskeletal erosion (ulceration) and gill fouling (accompanied by melanization) has been noted in the lobster (*5*). Although pollution is presumed to play a role in their development, experimental studies have not substantiated cause-and-effect relationships between pollution and either disease.

Fin erosion was the initial disease noted in winter flounder from Boston Harbor (*6*). The disease is known to be present in winter flounder from polluted environments and provides a marker that may signify the presence of other diseases. This prompted us to examine hepatic tissues from this species to determine whether other lesions also were present.

Materials and Methods

All winter flounder were sampled with a small otter trawl. Collections were made in April, June, and November 1984 and March 1985 from Deer Island Flats, an area in the northern part of the harbor adjacent to Winthrop. In the field, fish were first examined for the presence of gross external lesions and anatomic anomalies and then examined internally for gross lesions. The peritoneal cavity was exposed following a single incision just anterior to the genital pore continuing to just posterior of the pectoral girdle. The liver was examined for lesions and sampled for histopathological examination by excising a section of the lesion or a 6 to 8 mm thick medial slice. The excised tissue was fixed in 10% neutral buffered formalin.

Fixed tissues were routinely processed, embedded in paraffin, and sectioned at 6 μm. Sections were stained with Mayer's hematoxylin and eosin and, when necessary, with a variety of histochemical procedures including periodic acid-Schiff (PAS), oil red O, and Alcian blue.

For electron microscopy, liver tissues were minced with a razor blade to 1 mm^3 (or smaller) and immediately transferred to 2% cold glutaraldehyde buffered with 0.1 M phosphate to pH 7.4. The tissues were kept cold during transit to the laboratory. Tissues were rinsed in the prefixative and then postfixed in 1.0% osmium with 0.1 M phosphate buffer for 1 hr at room temperature. After fixation, tissues were routinely dehydrated in ethanols and propylene oxide, infiltrated, and embedded in Epon-araldite. Thick sections (1.0–2.0 μm) were prepared using glass knives, and thin sections were prepared using diamond knives and a Sorvall MT2 ultramicrotome. Thick sections were stained with toluidine blue and examined by light microscopy; thin sections were stained with uranyl acetate and lead citrate and examined with a Zeiss EM 9S2 electron microscope.

Results

Normal Histology

The histomorphology of normal winter flounder liver (Fig. 1) resembles that of other teleosts and is tubulosinusoidal (*7*). Tubule muralia are composed of 2- to 3-cell thick rows of principally cuboidal hepatocytes with their basal aspects on the sinusoidal side. Bile channels are on the opposite side of the muralia. Sinusoids are lined with squamous endothelial cells and occasional Kupffer cells. Since the teleost liver is not lobular, regularly occurring triads consisting of hepatic artery, portal vein, and bile ductules are not visible. The latter are dispersed throughout the parenchyma in a random fashion. Pancreatic exocrine and endocrine tissue can be found around large hepatic veins, especially in the anterior portion of the organ. Occasional macrophage aggregates are present in older animals.

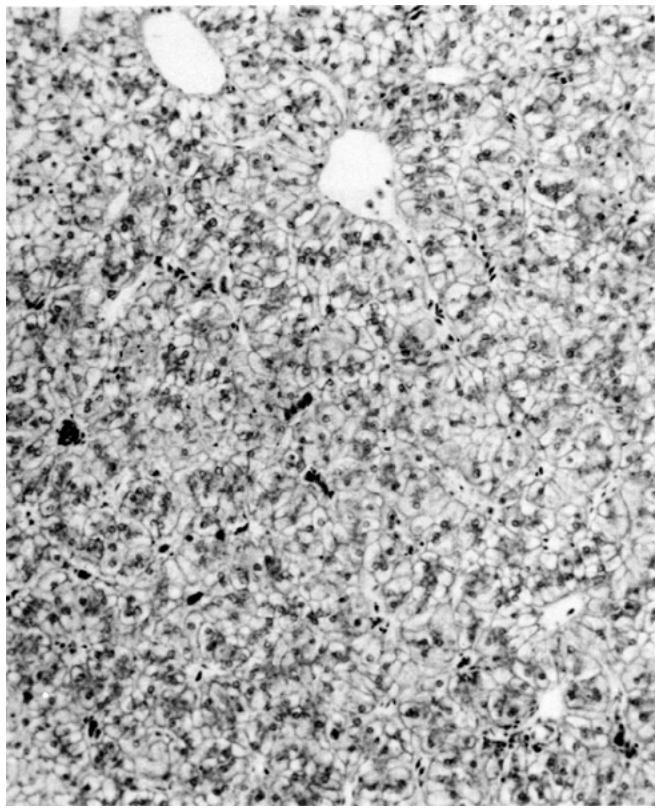

FIGURE 1. Normal liver. Note orderly tubulosinusoidal arrangement of hepatocytes. H & E. ×250.

Nonneoplastic Lesions

A variety of nonneoplastic hepatic lesions was noted in the 325 winter flounder examined. Cholangiitis, pericholangiitis (Fig. 2), and associated pericholangial fibrosis (Fig. 3) were common and varied in severity from mild to extensive. Hepatitis and pancreatitis, characterized by mononuclear infiltrations, were also commonly present.

Necrotic lesions of the hepatic cells were occasionally evident as areas of focal, coagulative necrosis. Most necrotic lesions, however, involved uniquely vacuolated hepatocytes (J. Bodammer, personal communication). These cells were present in 74% of the livers examined. Electron microscopic examination of

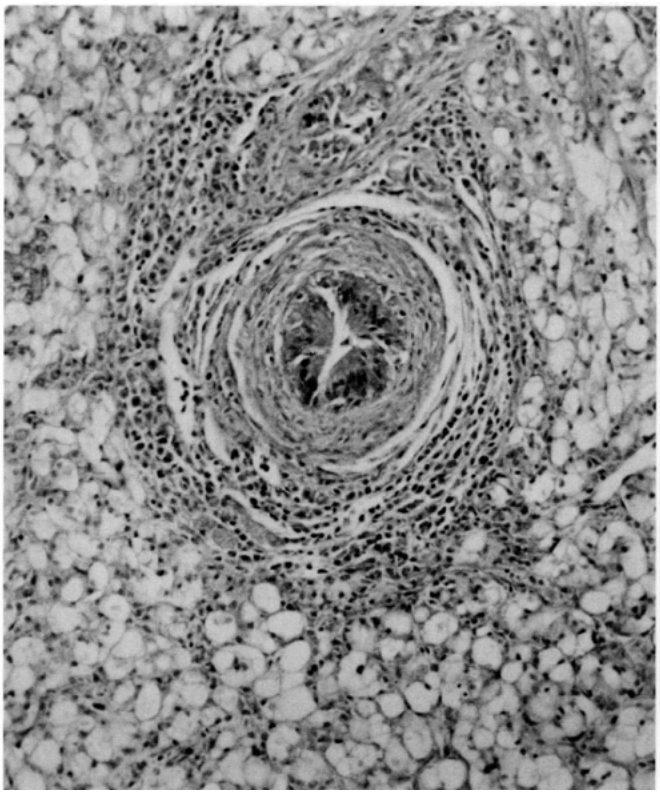

FIGURE 2. Cholangiitis and pericholangiitis characterized by a mononuclear cell infiltration. Lesion surrounded by vacuolated cells. H & E. ×400.

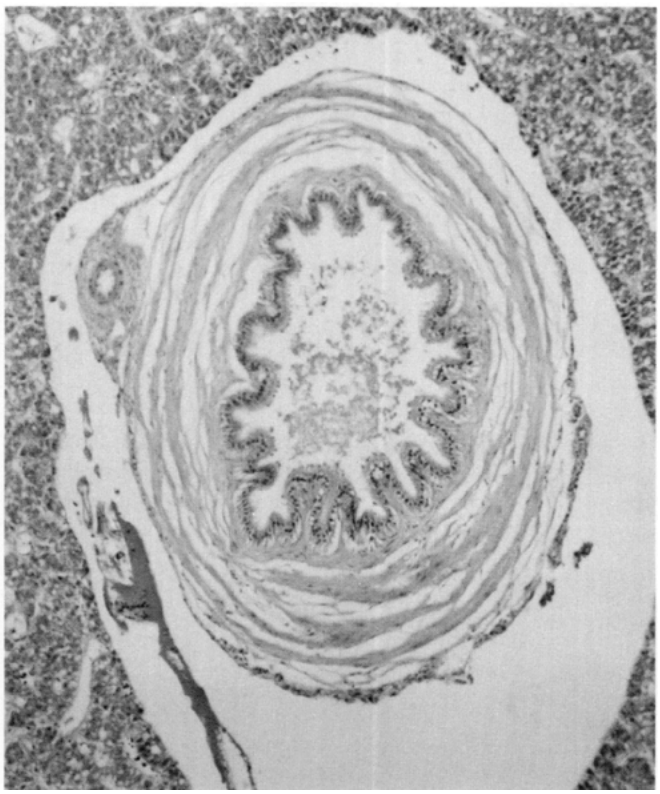

FIGURE 3. Pericholangial fibrosis lacking an inflammatory response. H & E. ×400.

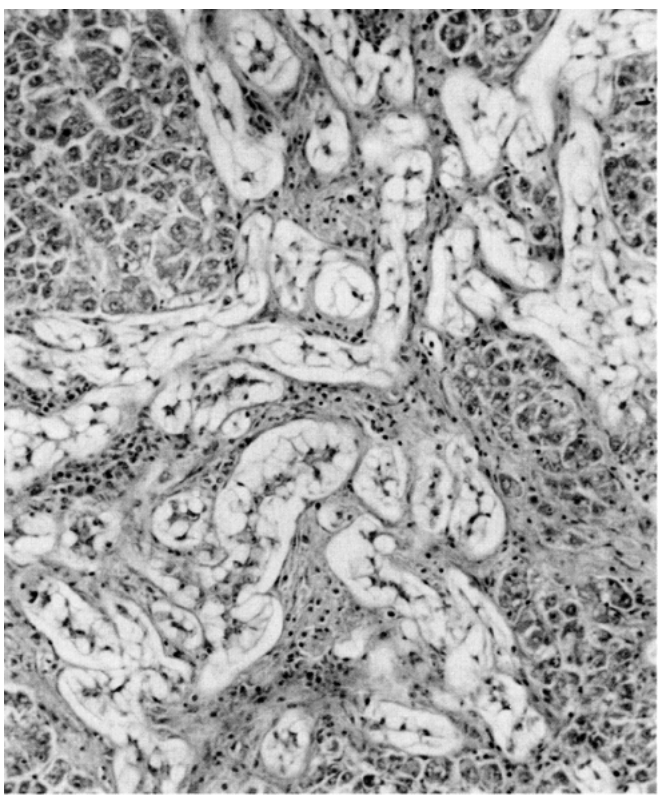

FIGURE 4. Vacuolated cells in acinar and ductular configurations. Note apical nuclei in cells enclosing a central lumen (arrow). H & E. ×400.

these cells revealed that the vacuole is formed from severely dilated endoplasmic reticulum (J. Bodammer, personal communication). Since the fish liver consists of hepatocytes in a tubulosinusoidal arrangement, cross-sections of the tubules produced vacuolated cell foci that were distinctly acinar in appearance and consisted of radially configured vacuolated cells with apical nuclei enclosing a central lumen (Fig. 4). Frequently the acini were ensheathed by fibrous tissue. Despite the presence of the large numbers of effete hepatocytes in some foci, leukocyte infiltrates were rarely seen. Other vacuolated cell foci contained areas of chromatically and morphologically different cells, which resembled those present in incipient carcinoma. Foci in which dissolution of constituent cells was pronounced formed parenchymal cavitations (Fig. 5) containing amorphous proteinaceous material, leukocytes, and short, wavy eosinophilic bands of collagen (Fig. 6).

The most conspicuous and numerous proliferative lesion was macrophage aggregate (MA-MMC [melano macrophage center]) hyperplasia and hypertrophy (Fig. 7). This condition, noted in 73% of the livers examined, was always present in livers with neoplasia. Macrophage cytoplasm was typically PAS-positive. In livers without neoplasia, MA could be found throughout the tissues but were typically located adjacent to bile ducts or vacuolated hepatocytes; in neoplastic livers MA almost always could be found around the perimeter of the neoplasm or in its interior if the latter was necrotic.

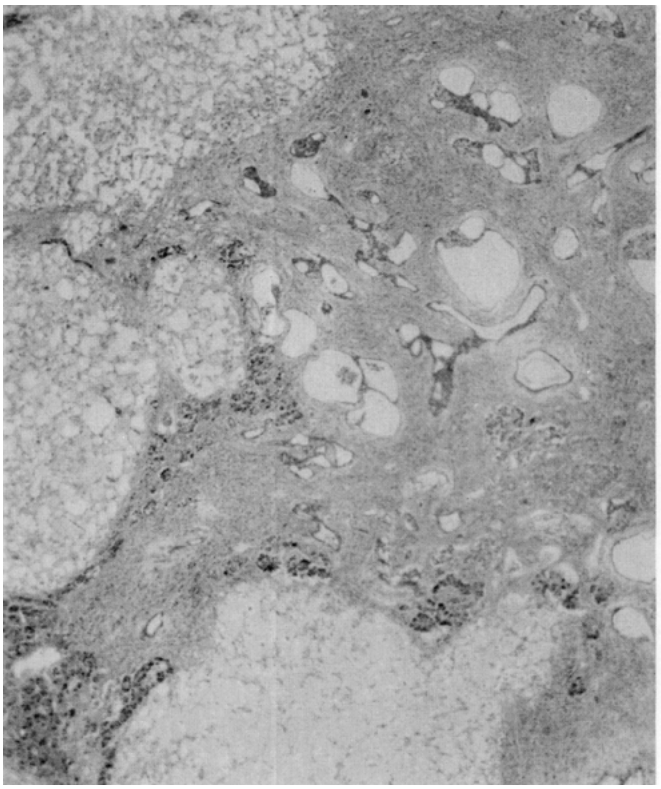

FIGURE 5. Parenchymal cavitations occupying large areas of the liver and containing an eosinophilic, proteinaceous material. H & E. ×100.

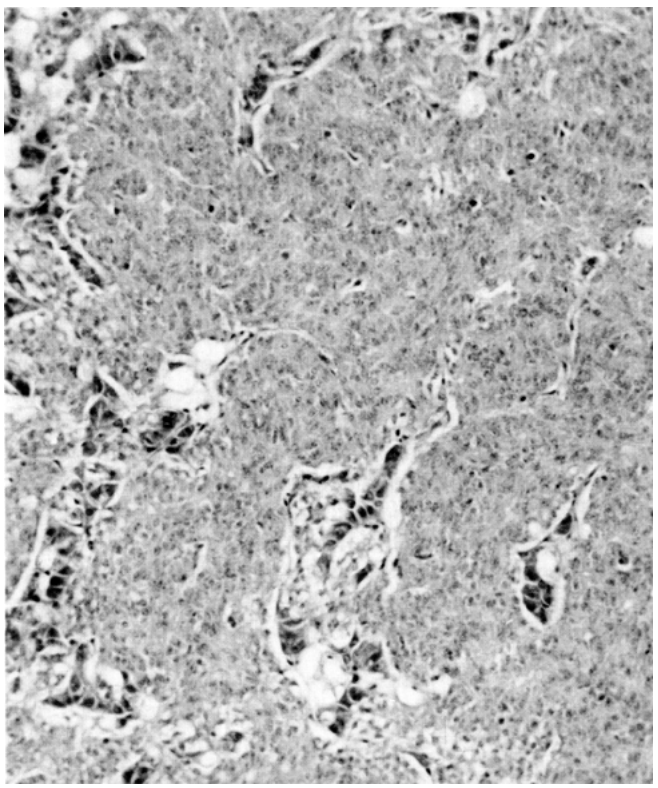

FIGURE 6. Parenchymal cavitation, higher power. Note leukocytes and short wavy bands of collagen. H & E. ×100.

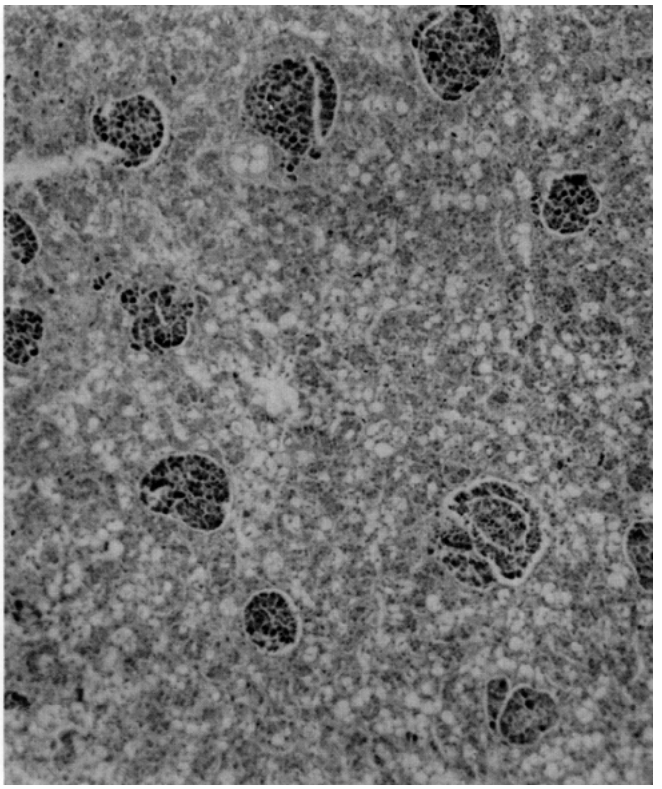

FIGURE 7. Increased number of macrophage aggregates (melano-macrophage centers) in a liver with a few randomly distributed vacuolated cells. H & E. ×100

Preneoplastic and Neoplastic Lesions

Basophilic Foci. Basophilic foci (foci of cellular alteration) were present in several of the sections examined (Fig. 8). These small (less than 1 mm), discrete areas consisted of excessively basophilic hepatocytes that otherwise appeared normal. The edge of the lesion usually was irregular and did not compress cells in the adjacent parenchyma; mitoses were not present. Some hepatocytes had enlarged nuclei with prominent, large nucleoli. Basophilic foci were seen in liver tissues with and without hepatic neoplasms.

Hepatocellular Adenoma. Hepatocellular adenomas (Fig. 9) were also present in the sections examined. These neoplasms consisted of nearly normal-appearing hepatocytes with more than the usual number of mitoses, particularly at the lesion's periphery. Hepatocytes within hepatic tubules of adenomas were crowded, and sinusoids frequently were dilated. The tumor consisted only of hepatocytes with no biliary, pancreatic, or prominent vascular components. Hepatocytes in the tumor tended to be oriented perpendicularly to those outside it and compressed the outside hepatocytes, forming a laminar layer of hepatocytes around the neoplasm. The edge of the lesion was distinctive because of the presence of compressed hepatocytes and numerous macrophage aggregates.

Carcinoma. The most numerous and prominent liver neoplasms were carcinomas, as judged by usual morphologic criteria. Their morphology varied considerably, and it was difficult to make clear distinctions between cholangiocellular and hepatocellular carcinomas. Some were completely undifferentiated and were classified simply as anaplastic carcinomas.

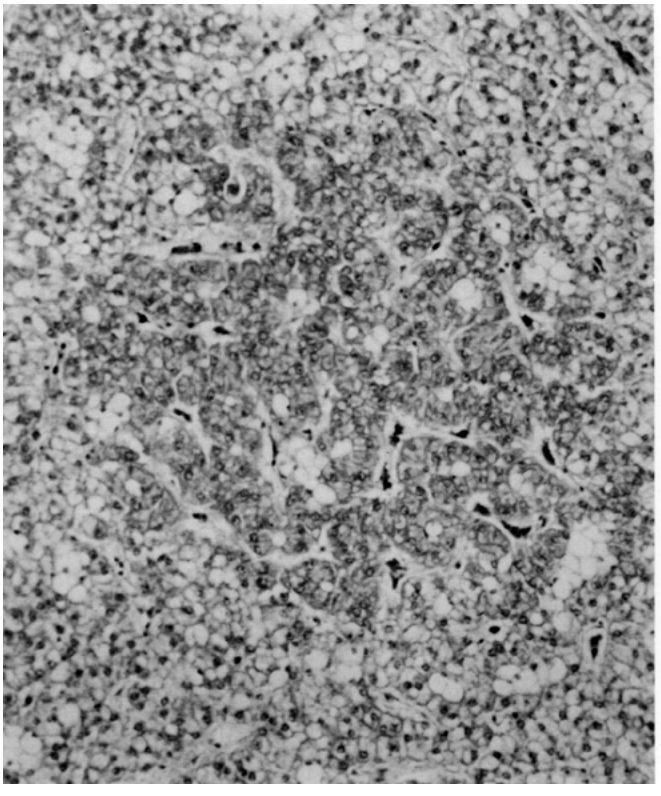

FIGURE 8. Basophilic focus. Note central areas of apparently normal but excessively basophilic hepatocytes. H & E. ×250.

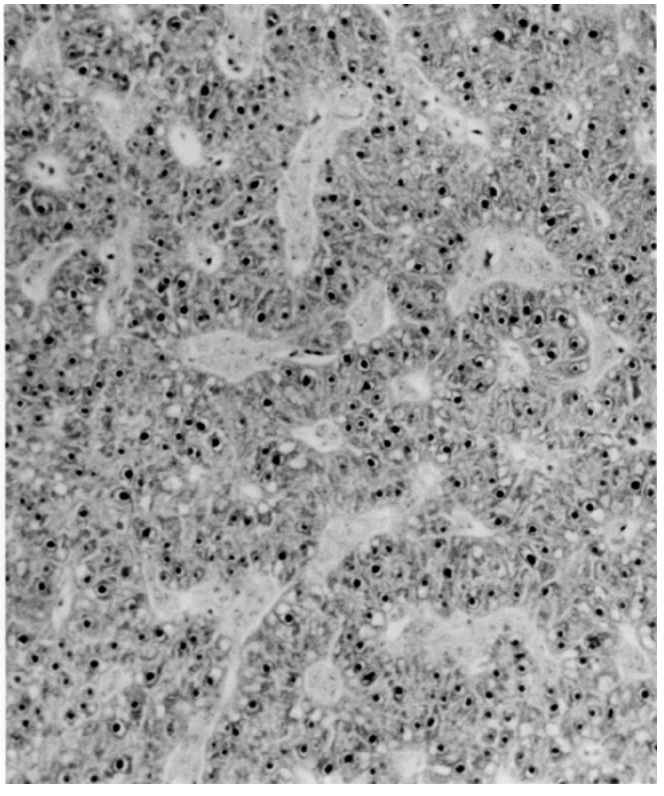

FIGURE 9. Hepatocellular adenoma. Note hyperchromatic enlarged nucleioli, hepatocyte hyperplasia thickening hepatic cords, and dilated sinusoids. H & E. ×250.

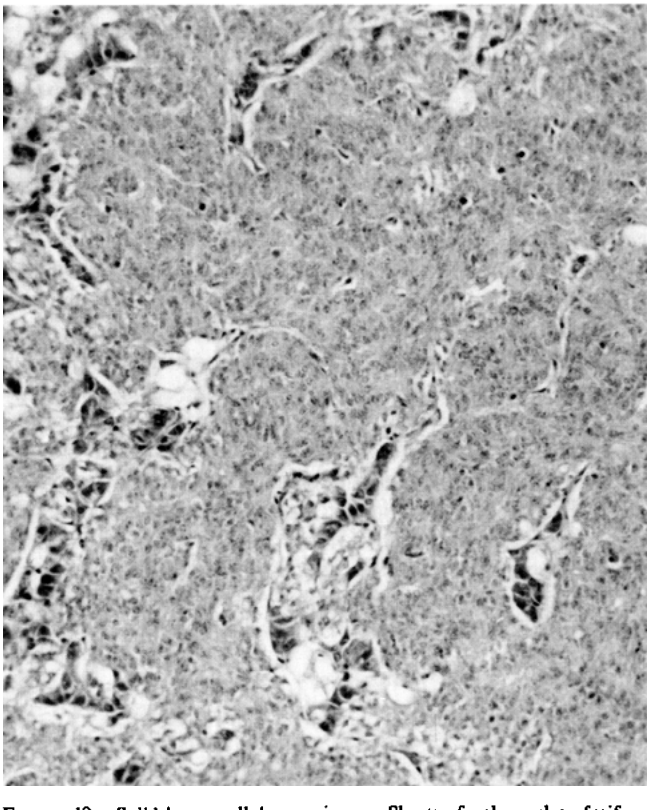

FIGURE 10. Solid hepatocellular carcinoma. Sheets of polygonal or fusiform hepatocytes with apparent loss of normal sinusoidal architecture. H & E. ×250.

The more solid-appearing tumors were designated as hepatocellular carcinomas (Fig. 10). These neoplasms consisted of atypical hepatocytes, either polygonal or fusiform in shape, supported by a thin fibrous stroma. Bile ducts, MA, and pancreatic tissue were not present. In apparently incipient stages of hepatocellular carcinoma development, foci of dysplastic and anaplastic cells were often present within masses of vacuolated hepatocytes (Fig. 11). The tumor cells entrapped small, irregularly shaped islands of compressed fibrous tissue and hepatocytes. In some instances, the edge of the tumor was circumscribed, whereas in others it was difficult to determine the junction between the tumor cells and the adjacent parenchyma. When the tumor cells were fusiform, the neoplasm resembled fibrosarcoma, but connective tissue stains were invariably negative. Tumors with polygonal hepatocytes were more basophilic. In some instances the hepatocytes contained spherical, hyaline, eosinophilic intracytoplasmic inclusions. An absence of hepatocyte polarity coincided with the presence of abnormal tubular architecture. Many of the larger tumors had parenchymal cavitations caused by extensive necrosis.

Tumors designated as cholangiocellular carcinoma had ductal configurations (Fig. 12). Epithelial cells with vesicular nuclei formed tubules that varied considerably in size and shape. In many tubules the epithelial cells had eosinophilic blebs at the luminal borders and intraluminal exfoliated epithelial cells. In most of the cholangiocellular carcinomas, the smaller tubules were at the perimeter of the lesion and the larger, more dilated

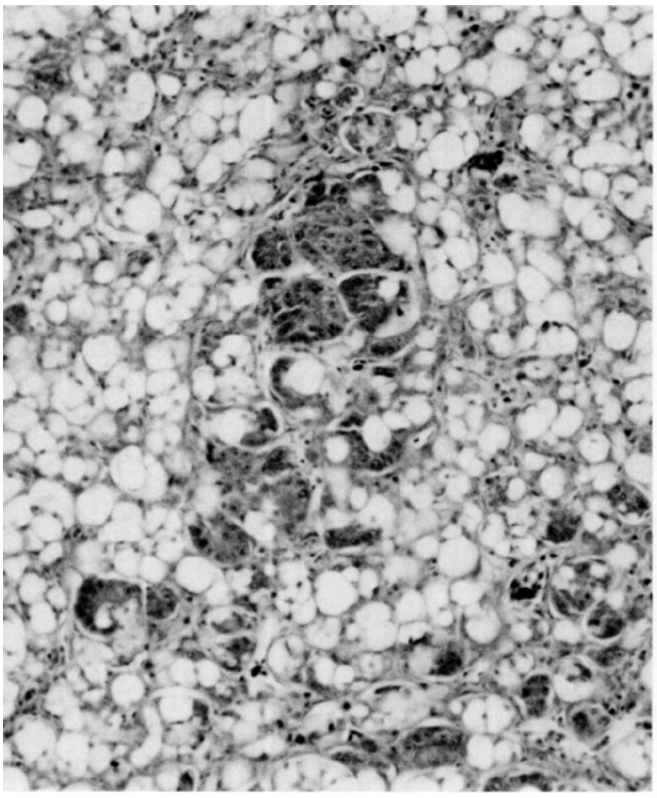

FIGURE 11. Incipient neoplasm composed of dysplastic and anaplastic hepatocytes arising within a mass of vacuolated cells. H & E. ×400.

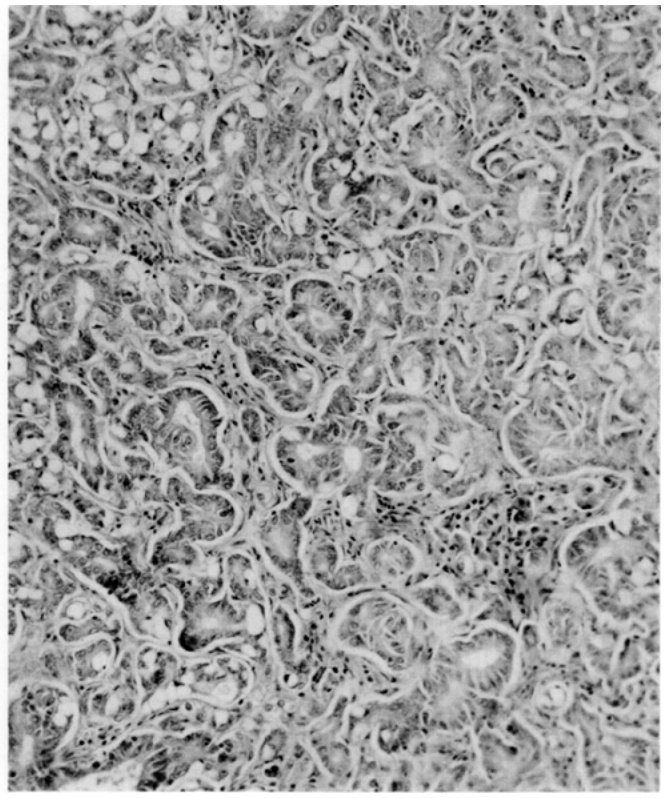

FIGURE 12. Cholangiocellular carcinoma composed largely of ductlike structures. H & E. ×250.

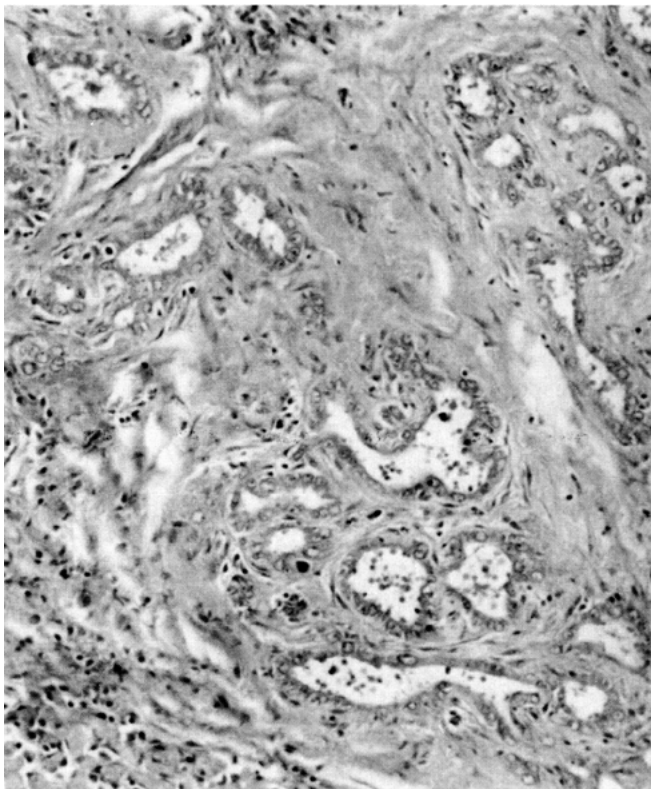

FIGURE 13. Scirrhus cholangiocellular carcinoma. Note broad bands of fibrous tissue surrounding islands of ductlike structures. H & E. ×250.

ones in its interior. The amount of fibrous tissue ensheathing the tubules varied considerably. In some tumors there was minimal connective tissue, and the lesion consisted predominantly of tubules; in others there was substantial connective tissue, and it was the predominant component (Fig. 13). Possibly scirrhus variants developed as a result of the postnecrotic changes in neoplasms that originally had been predominantly tubular. In some tumors, abundant loose connective tissue ensheathed tubules composed of squamoid neoplastic epithelium. Intraluminal epithelial papillae were present in some tubules.

Tumors designated as anaplastic carcinoma were poorly differentiated (Fig. 14) and did not have a uniform morphology. The size and shape of their constituent cells varied considerably. These tumors consisted of randomly organized, sometimes swirling cells that were highly pleomorphic. Many cells contained large vacuoles resembling those seen in nonneoplastic parenchymal hepatocytes, although no tumors were examined by electron microscopy. Nuclei varied in size, shape, and degree of hyperchromatism. Some cells had large basophilic nuclei with prominent nucleoli, others had smaller vesicular nuclei with indistinct nucleoli. Mitoses were common, and some were evidently polyploid.

Discussion

Liver neoplasia, often at prevalences of epizootic proportions, has been reported in at least 15 species of feral and hatchery-reared fish in North America, Japan, and Europe. The literature has been reviewed as it relates to environmental and experimental

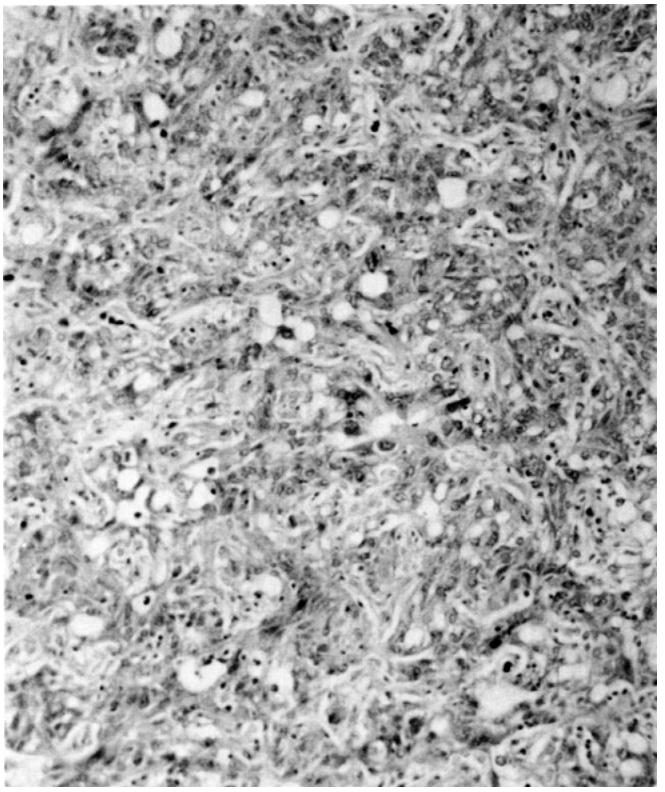

FIGURE 14. Highly anaplastic hepatic carcinoma with increased mitotic activity. H & E. ×250.

carcinogenic agents by Couch and Harshbarger (*8*) and Mix (*9*). Nomenclature and morphologic criteria for the preneoplastic and neoplastic lesions herein presented follow those of Firth and Ward (*10*) in mice and Squire and Levitt (*11*) in rats.

Nonneoplastic and neoplastic hepatic lesions in Boston Harbor winter flounder were similar grossly and microscopically to those reported in *Parophrys vetulus* and *Genyonemus lineatus* from the west coast of North America, but with certain significant differences (*12–14*). Nonneoplastic lesions in the livers of winter flounder with hepatic neoplasia include pericholangiitis, pericholangial fibrosis, cholangiofibrosis (adenofibrosis), nonspecific coagulation necrosis, hepatocyte vacuolation (possibly modified apoptosis), parenchymal cavitations, postnecrotic fibrosis, and macrophage aggregate hyperplasia and hypertrophy. The type, prevalence, and relationship of these conditions to neoplastic lesions suggests a developmental sequence.

Bile duct epithelial vacuolation and degeneration, pericholangiitis, and pericholangial fibrosis are early, ubiquitous changes that are persistent and increase in severity with the appearance of other liver lesions. Bile ducts in livers with incipient neoplasia and few areas of vacuolated hepatocytes have mild mononuclear cell infiltrations and fibrosis. These lesions progress, however, and in livers with fulminating neoplasia and extensive parenchymal cell vacuolation, the periductal fibrosis is marked. In homeotherms, pericholangiitis and biliary fibrosis is related to, among other injurious factors, cholestasis and toxins transported within the biliary system (*15–19*). Cholestasis, in turn, has often been related to the ingestion of various toxic substances (*20*).

Nonspecific coagulation necrosis was rare, but hepatocyte vacuolation was present in all neoplastic livers. This lesion, frequently surrounded by fibrous tissue and characterized by acinuslike arrangement of vacuolated cells with apical nuclei, appears unique to winter flounder. The lesion has not been described in the liver of any other fish species nor have we seen these cells in the livers of other bottom-dwelling fish from Boston Harbor. Electron microscopic examination of these cells reveals an extensively dilated endoplasmic reticulum (J. Bodammer, unpublished observation). Apoptosis is characterized by a dilated ER and is a form of cell death often elicited by exposure to toxic substances (*21*). It has been noted in gill lamellae of rainbow trout exposed to acutely lethal aqueous concentrations of inorganic mercury (0.35 ppm) and copper (0.135 ppm) (*22*). Apoptosis in higher vertebrates most often affects individual cells, is accompanied by intra- and intercellular eosinophilic inclusions, and fails to elicit an inflammatory response. The vacuolated hepatocytes observed in winter flounder may represent a form of modified apoptosis. Although no inflammatory response was apparent and inclusions were present, multiple foci or sheets of hepatocytes rather than individual cells were commonly vacuolated. Within these areas neoplastic cells frequently were present.

In some instances, the massive cell death lead to parenchymal cavitations. These cavitations were similar to the cystic parenchymal degenerations reported in the livers of feral English sole and the spongiotic edema (spongiosis hepatis) produced experimentally in medaka after long-term B-hexachlorocyclohexane exposure (*13,23*). Proliferating fibroblasts were present in the cavitations. Postnecrotic fibrosis was a later development in response to the extensive necrosis. Nodular regeneration of new hepatic epithelium rarely was observed.

Proliferation of macrophage aggregates (MA) was extensive in all neoplastic livers. MA hyperplasia has been reported in English sole with hepatocellular carcinoma and in fish inhabiting degraded environments (*13,24–29*). Since the proliferation of these aggregates is related to tissue destruction, which in turn may be a result of exposure to toxic substances, their increase in neoplastic winter flounder livers is not surprising (*30*).

A sequence of events that begins with the simultaneous appearance of hepatocyte vacuolation (modified apoptosis), vacuolation and degeneration of bile duct epithelium and pericholangiitis, and is followed by an increase in the severity of these lesions and pericholangial fibrosis, and which concludes with the appearance among the vacuolated cells of dysplastic, atypical cells characteristic of incipient neoplasia suggests the effects of a toxic substance or substances. These substances enter the liver and either directly or after metabolic transformation cause hepatocyte death. Within the biliary system they cause necrosis, inflammation, fibosis, and eventual transformation of hepatocytes or bile duct cells to invasive neoplasms. This concept of a progression of events concurs with the resistant hepatocyte model of hepatocarcinogenesis (*31,32*). This model, supported by extensive experimental evidence, suggests that initiating levels of carcinogens induce hepatocytes that are resistant to toxic effects and that these initiated, resistant hepatocytes are easily stimulated to proliferate synchronously

when exposed to noninitiating, low levels of some carcinogens. This results in the growth of persistent nodules among other uninitiated, nonresistant cells that undergo necrosis, or fail to grow, and do not proliferate. The presence in winter flounder livers of neoplastic cells among sheets of degenerating and necrotic hepatocytes suggests that the neoplastic cells are resistant hepatocytes proliferating in an area of sensitive or nonresistant hepatocytes. The prevalence of hepatocellular carcinoma in flounder from areas heavily contaminated by toxic and potentially carcinogenic pollutants further supports this model of carcinogenesis.

Recently, the wide range of hepatic preneoplastic and neoplastic lesions in feral English sole exposed to environmental hepatocarcinogens has been compared to the progression of experimentally inducible neoplasms in rodents and salmonids. In some salmonid fishes, investigators reported significant patterns of lesion co-occurrence similar to those present in the development of the experimentally induced neoplasms in rodents. Degenerative-necrotic lesions, hepatic megalocytosis, regenerative foci, and foci of cellular alteration all co-occurred with neoplasms (*13*).

A variety of preneoplastic and neoplastic lesions not present in the Boston Harbor winter flounder have been found in the English sole. However, some developmental stage lesions were present that were similar to those in the English sole and in the livers bearing induced neoplasms in rodents and salmonids, thus suggesting a similar progression. Degeneration and cell death were observed in all winter flounder livers with tumors. While megalocytosis and clear and eosinophilic cell foci were absent, basophilic cell foci were present. The absence of certain lesions in the Boston Harbor winter flounder livers does not, however, preclude an eventual progression from environmental carcinogen-initiated hepatocytes to carcinoma. Rather, it may indicate expected differences in tumor pathogenesis in different genera of fish. Boston Harbor flounder, like Puget Sound sole, are a natural population exposed to carcinogenic pollutants. Although not identical in all its aspects, the progression of winter flounder hepatic lesions from necrosis to eventual neoplasia largely concurs with the progression observed by Myers et al. (*13*) in feral English sole and by others in rodent and salmonid developing experimentally induced tumors.

Adenomas, hepatocellular carcinomas, and cholangiocellular carcinomas were similar morphologically to those described in other fish and in the rodent. While many of the tumors classified as carcinomas were highly anaplastic and locally invasive, no evidence of metastasis was observed.

In this study, 325 fish (109 males, 212 females, 4 unidentified) were examined ranging in length from 22 to 48 cm (mean length 36.5 cm, SD 3.5 cm). Tumor prevalence by fish length is presented in Figure 15. No tumors were found in flounder smaller than 32 cm (n = 24) in length. This relationship between prevalence of neoplasms and length of the host, and ostensibly between prevalence and age, has been noted in other studies (*13,33,34*). Overall, tumors were present in 49, or 15%, of the Boston Harbor flounder examined. Twelve tumor-bearing fish were males (11.0%), 36 were females (16.9%), and 1 was a fish of unidentifiable sex. Seven neoplasms were classified as hepatocellular carcinoma (14.2%) and 42 (85.7%) as cholangiocellular carcinomas. Prevalence of tumors was similar

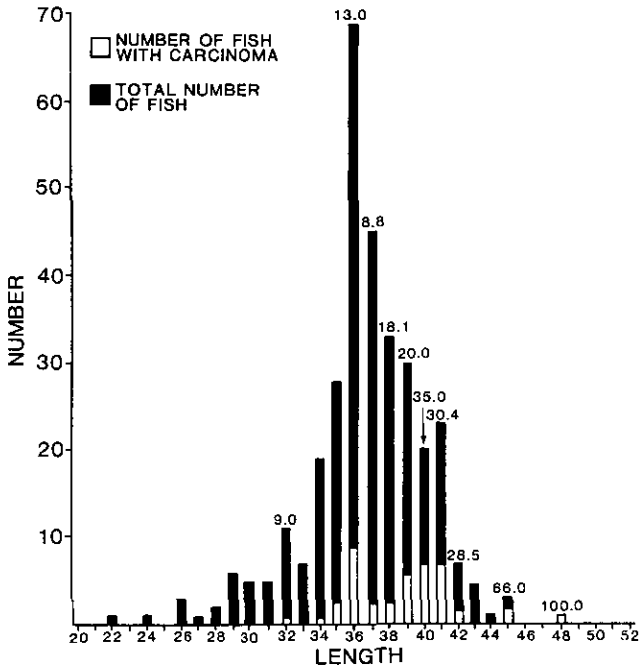

FIGURE 15. Histogram of tumor prevalence by fish length. Higher prevalence is found in larger fish.

to that reported in Pacific coast English sole (*35*) and in Michigan Stizostedion species with hepatic neoplasia (*36*).

The high prevalence of hepatic neoplasia in Boston Harbor winter flounder suggests a relationship to anthropogenic pollution. Winter flounder from Georges Bank, including fish over 40 cm in length, did not have liver tumors (C. Dawe, unpublished observation). Fish from unpolluted estuaries in the Northeast also did not have neoplastic lesions, while those from moderately polluted sites such as Narragansett Bay did, but not at such high prevalences as in Boston Harbor (*37,38*). This study and that of Myers et al. (*13*) reveal similar pathogenetic patterns: a progression from toxic necrotic lesions to neoplasia, further evidence that pollutants are likely the inducers of the lesions. Additional histopathological field surveys and laboratory investigations are warranted.

The only other numerically significant hepatic neoplasm of a marine fish in the northeastern United States is hepatocarcinoma of the Atlantic tomcod, *Microgadus tomcod*, from the Hudson River, New York (*39,40*). The first report of this lesion (*41*) disclosed that 25% of 264 fish had neoplastic nodules and/or hepatocellular carcinoma (gross examination). Tumor cells typically were poorly differentiated, hypertrophic, pleomorphic, and more basophilic than normal. Some tumors had cystic cavities containing necrotic hepatocytes and an eosinphilic fluid. Electron microscopic examination of hepatocytes from Hudson River tomcod revealed increased and distended (swollen) rough endoplasmic reticulum (RER), absence of smooth endoplasmic reticulum (SER), heavy lipid deposition, and ceroid plaques, lesions suggestive of exposure to toxic compounds. Hepatocellular carcinoma cells were larger with a conspicuous nucleolus and had similarly distended RER but contained less lipid (*42*).

Although the specific cause of the tomcod hepatocarcinomas is not known, the Hudson River contains elevated PCB levels in

sediments. Smith et al. (*41*) reported tumorous tomcod livers ($n = 9$) that contained PCB levels ranging from 10.9 to 98.2 ppm (mean 39.0 ppm), while livers from tomcod without tumors contained PCB concentrations ranging from 20.3 to 49.2 ppm (mean 33.0 ppm). Klauda (*43*), examining the same (presumably) population, reported levels of Aroclors 1016 and 1254 varying from 0.01 to 0.67 ppm. Tomcod are not an important food fish and do not sustain large commercial or recreational fisheries.

Evidence of hepatocellular carcinoma in a food fish of major commercial and recreational importance, coupled with its occurrence in areas suffering from chemical contamination, raises questions of public health significance. Studies should be conducted investigating the chemicals and potential human carcinogens present in the edible portions of tumorous and nontumorous food fish, and risk assessments should be performed. These studies will require a concerted effort by chemists, fishery scientists, and pathologists.

REFERENCES

1. Boehm, P. D., Steinhaver, W., and Brown, J. Organic Pollutant Biogeochemistry Studies in the Northeast U.S. Marine Environment. Battelle New England Marine Research Laboratory Final Report. contract No. NA-83-FA-C-00022 to NOAA National Marine Fisheries Service, Highlands, NJ, 1984.
2. Commonwealth of Massachusetts Metropolitan District Commission. Application to the U.S. Environmental Protection Agency for Modification of Secondary Treatment Requirements for Discharges into Marine Waters of Boston Harbor and Massachusetts Bay for Its Deer Island and Nut Island Wastewater Treatment Plants. Boston, MA, 1979.
3. Bridges, W. L. Fisheries: past, present and future. In: Boston Harbor and Massachusetts Bay: Issues, Resources, Status and Management (B. Brown, Ed.), NOAA Estuary-of-the-Month, Seminar Series No. 4., 1987, pp. 31–36.
4. Reinisch, C. L., Yanong, R. P. E., and Craig, A. C. Prevalence of neoplasia in hemolymph and vital organs of soft-shell clams, *Mya arenaria*, in Boston Harbor. Final Report of Department of Comparative Medicine, Tufts University School of Veterinary Medicine to Commonwealth of Massachusetts, Executive Office of Environmental Affairs, Department of Environmental Quality Engineering, Boston, MA, 1988.
5. Estrella, B. T. Gill and shell pathology in Massachusetts coastal lobster (*Homarus americanus*) as indicators of degraded marine environments in Massachusetts Bay and Buzzards Bay. Massachusetts Division of Marine Fisheries, Sandwich, MA, 1984, unpublished manuscript.
6. Williams, J. The occurence of fin erosion in winter flounder, *Pseudopleuronectes americanus*, from the vicinity of Boston Harbor Massachusetts. In-House Report, Battelle New England Research Laboratory, Duxbury, MA, 1981.
7. Hampton, J. A., McCuskey, P. A., McCuskey, R. S., and Hinton, D. E. Functional units in Rainbow trout (*Salmo gairdneri*) liver: I. Arrangement and histochemical properties of hepatocytes. Anat. Rec. 213: 166–175 (1985).
8. Couch, J. A., and Harshbarger, J. C. Effects of carcinogenic agents on aquatic animals: an environmental and experimental overview. Environ. Carcinog. Rev. 3: 63–105 (1985).
9. Mix, M. C. Cancerous diseases in aquatic animals and their association with environmental pollutants: a critical literature review. Mar. Environ. Res. 20: 1–141 (1986).
10. Firth, V. H., and Ward, J. M. A morphological classification of proliferative and neoplastic hepatic lesions in mice. J. Environ. Pathol. Toxicol. 3: 329–351 (1980).
11. Squire, R. A., and Levitt, M. H. Report on a workshop on classification of specific hepatocellular lesions in rats. Cancer Res. 35: 3214–3223 (1975).
12. Malins, D. C., McCain, B. B., Brown, D. W., Chan, S. -L., Myers, M. S., Landahl, J. T., Prohaska, P. G., Friedman, A. J., Rhodes, L. D., Burrows, D. G., Gronlund, W. D., and Hodgins, H. D. Chemical pollutants in sediments and diseases of bottom dwelling fish in Puget Sound, Washington. Environ. Sci. Technol. 18: 705–713 (1984).
13. Myers, M. S., Rhodes, L. D., and McCain, B. B. Pathological anatomy and patterns of occurrence of hepatic neoplasms, putative preneoplastic lesions and other idiopathic hepatic conditions in English sole (*Parophrys vetulus*) from Puget Sound, Washington. JNCI 78: 333–336 (1987).
14. Malins, D. C., McCain, B. B., Brown, D. W., Myers, M. S., Krahn, M. M., and Chan, S. -L. Toxic chemicals, including aromatic and chlorinated hydrocarbons and their derivatives, and liver lesions in white croaker (*Genyonemus lineatus*) form the vicinity of Los Angeles. Environ. Sci. Technol. 21(8): 765–770 (1987).
15. Mortimer, P. H. The experimental intoxication of sheep with sporodesmin, a metabolic product of *Pithomyces chartarum*. IV. Histological and histochemical examinations of orally-dosed sheep. Res. Vet. Sci. 4: 166–185 (1963).
16. Mortimer, P. H., Taylor, A., and Shorland, F. B. Early hepatic dysfunction preceding biliary obstruction in sheep intoxicated with sporodesmin. Nature 194: 550–551 (1962).
17. Lee, R. F., Sauerheber, R., and Dobbs, G. H. Uptake, metabolism and discharge of polycylic aromatic hydrocarbons by marine fish. Mar. Bio. 17: 201–208 (1972).
18. Fisher, M. Biochemical basis for toxic liver injury: lithocholate hepatotoxicity. In: Toxic Injury of the Liver, Part A (E. Farber and M. M. Fisher, Eds.), Marcel Deckker, Inc., New York, 1979, pp. 155–192.
19. Phillips, M. J., Oda, M. and Funatsu, K. Reactions of the liver to injury: cholestasis, ultrastructural aspects. In: Toxic Injury of the Liver, Part A (E. Farber and M. M. Fisher, Eds.), Marcel Dekker, Inc., New York, 1979, pp. 155–192.
20. Zimmerman, H. Drug induced chronic liver disease. In: Toxic Injury of the Liver, Part B (E. Farber and M. M. Fisher, Eds.), Marcel Dekker, Inc., New York, 1979, pp. 687–737.
21. Wyllie, A. H. Commentary: what is apoptosis? Histopathology 10: 995–998 (1986).
22. Daoust, P. -Y., Wobser, G., and Newstead, J. D. Acute pathological effects of inorganic mercury and copper in the gills of rainbow trout. Vet. Pathol. 21: 93–100 (1984).
23. Wester, P. W., and Canton, J. H. Histopathological study of *Oryzias latipes* (Medaka) after long-term exposure to B-hexachlorocyclohexane exposure. Aquat. Toxicol. 9: 21–45 (1986).
24. Haensly, W. E., Neff, J. M., Sharp, J. R., Morris, A. C., Bedgood, M. F., and Boehm, P. D. Histopathology of *Pleuronectes platessa* L. from Aber Wrac'h and Aber Benoit, Brittany France: long-term effects of the Amoco Cadiz crude oil spill. J. Fish Dis. 5: 365–391 (1982).
25. Perkins, E. M., Brown, D. A., and Jenkins, K. D. Contaminants in white croakers *Genyonemus lineatus* (Ayres, 1855) from the southern California bight: III. Histopathology. In: Physiological Mechanisms of Marine Pollutant Toxicity (W. B. Vernberg, A. Calabrese, F. P. Thurberg, and F. J. Vernberg, Eds.), Academic Press, New York, 1982, pp. 215–231.
26. Bucke, D., Watermann, B., and Feist, S. Histological variations of hepatosplenic organs from the North Sea dab, *Limanda limanda* (L.) J. Fish Dis. 7: 255–268 (1984).
27. Wolke, R. E., Murchelano, R. A., Dickstein, C. D., and George, C. J. Preliminary evaluation of the use of macrophage aggregates (MA) as fish health monitors. Bull. Environ. Contam. Toxicol. 35: 222–227 (1985).
28. Zdanowicz, V. S., Gadbois, D. F., and Newman, M. W. Levels of organic and inorganic contaminants in sediments and fish tissues and prevalences of pathological disorders in winter flounder from estuaries of the northeast United States, 1984. Institute of Electrical and Electronic Engineers Oceans '86 Conference Proceedings, Washington, DC, September 23–25, 1986, pp. 578–585.
29. Blazer, V. S., Wolke, R. E., Brown, J., and Powell, C. A. Piscine macrophage aggregate parameters as health monitors: effect of age, sex, relative weight, season and site quality in largemouth bass (*Micropterus salmoides*). Aquat. Toxicol. 10: 199–215 (1987).
30. Herraez, M. P., and Zapata, A. Structure and function of the melanomacrophage centres of the goldfish *Carrasius auratus*. Vet. Immun. Immunopath. 12: 117–126 (1986).
31. Ying, T. S., Sarma, D. S. R., and Farber, E. Role of acute hepatic necrosis in the induction of early steps in liver carcinogenesis by diethylnitrosamine. Cancer Res. 41: 2096–2102 (1981).
32. Farber, E., and Sarma, D. S. R. Hepatocarcinogenesis: a dynamic cellular perspective. Lab. Invest. 56: 4–22 (1987).
33. Falkmer, S., Emdin, S. D., Ostberg, Y., Mattisson, A., Johansson, M. -L., and Fange, R. Tumor pathology of the hagfish, *Myxine glutinosa*, and the river lamprey, *Lamptera fluviatilis*. Prog. Exp. Tumor Res. 20: 217–250 (1976).
34. Dawe, C. J., Sonstegard, R., Stanton, M. F., Woronecki, D. E., and Reppert, R. T. Intrahepatic biliary duct neoplasm in *Catostomus commersoni*. Prog. Exp. Tumor Res. 20: 195–204 (1976).

35. McCain, B. B., Pierce, K. V., Wellings, S. R., and Miller, B. S. Hepatomas in marine fish from an urban estuary. Bull. Environ. Contam. Toxicol. 18: 1-2 (1977).
36. Black, J. J., Evans, E. D., Harshbarger, J. C., and Zeigel, R. F. Epizootic neoplasms in fishes from a lake polluted by copper mining wastes. JNCI 69: 915–926 (1982).
37. Murchelano, R. A., and Wolke, R. E. Epizootic carcinoma in winter flounder, *Pseudopleuronectes americanus*. Science 228: 587–589 (1985).
38. Lee, T. C., Saila, S. B., and Wolke, R. E. Winter Flounder Contaminant and Pathological Survey — Narragansett Bay and Vicinity. Report to the Narragansett Bay Project, Providence, RI, 1988.
39. Dey, W., Peck, T., Smith, C., Cormier, S., and Kreamer, G. A study of the occurrence of liver cancer in Atlantic tomcod (*Microgadus tomcod*) from the Hudson River estuary. Final Report No. HRF41A prepared for the Hudson River Foundation by E.A. Science and Technology, Middletown, NY, 1986.
40. Cormier, S., and Kreamer, G. A Study of the Occurrence of Liver Cancer in Atlantic Tomcod (*Microgadus tomcod*) from the Hudson River Estuary. Appendix A of Final Report No. HRF41A prepared for the Hudson River Foundation by E.A. Science and Technology, Middletown, NY, 1986.
41. Smith, C. E., Peck, T. H., Klauda, R. J., and McLaren, J. B. Hepatomas in Atlantic tomcod *Microgadus tomcod* collected in the Hudson River estuary in New York. J. J. Fish Dis. 2: 313–319 (1979).
42. Cormier, S. Fine structure of hepatocytes and hepatocellular carcinoma of the Atlantic tomcod, *Microgadus tomcod*. J. Fish Dis. 9: 179–194 (1986).
43. Klauda, R. J., Peck, T. H., and Rice, G. K. Accumulation of polychlorinated biphenyls in Atlantic tomcod (*Microgadus tomcod*) collected from the Hudson River estuary, New York. Bull. Environ. Contam. Toxicol. 27: 829–835 (1981).