Environmental Health Perspectives
Vol 90, pp. 43–51, 1991

Germinomas and Teratoid Siphon Anomalies in Softshell Clams, *Mya arenaria*, Environmentally Exposed to Herbicides

by George R. Gardner,* Paul P. Yevich,* John Hurst,† Peter Thayer,† Sandra Benyi,* John C. Harshbarger,‡ and Richard J. Pruell*

Seminomas and dysgerminomas are epizootic in softshell clams, *Mya arenaria*, from three Maine estuaries contaminated with herbicides. The first epizootic was discovered in 22% of clams collected as Searsport near Long Cove Brook and three culverts that conveyed heating oil and jet fuel spilled from a tank farm in 1971. Data from subsequent epizootiological studies and a series of long-term experimental exposures of softshell clams to no. 2 fuel oil, JP-4, and JP-5 jet fuel at the U.S. EPA, Environmental Research Laboratory in Narragansett, Rhode Island, and in the field did not support an etiology by these petroleum products. In the two recent epizootics reported here, the germinomas have been observed in 3% of the softshell clams collected from Roque Bluffs near Machiasport and from 35% of softshell clams collected from Dennysville. Mya collected at Dennysville had pericardial mesotheliomas and teratoid siphon anomalies in addition to gonadal neoplasms. Estuaries at Dennysville had been contaminated by herbicides in a 1979 accidental spray overdrift during aerial application of Tordon 101 to adjacent forests. Further investigation determined widespread use of the herbicides Tordon 101, 2,4-D, 2,4,5-T, and other agrochemicals in an extensive forestry and blueberry industry in both the Roque Bluffs and the Dennysville areas. Herbicide applications at Searsport were confirmed for railroad property bordering Long Cove estuary and for Long Cove Brook adjacent to the estuary where a highway department reportedly cleans its spray equipment. Herbicide contamination is the only common denominator identified at all three sites where Mya have been found with gonadal neoplasms. The suggested association of herbicides with gonadal neoplasms in clams is strengthened by the increased incidence of seminomas observed in military working dogs exposed to defoliating herbicides in Vietnam between 1967 and 1972.

Introduction

Germinomas were discovered and described in softshell clams (*Mya arenaria*) collected in Long Cove near Searsport, Maine, in 1975 (*1*), and the findings were corroborated in 1977 (*2*). Since Long Cove had been recently heavily contaminated by an oil spill (no. 2 fuel oil and JP-4 jet fuel), studies were begun at the U.S. EPA Environmental Research Laboratory in Narragansett, Rhode Island (ERL/N), to determine whether there was a relationship between oil exposure and tumorigenesis in the softshell clams. Histopathology was observed in reproductive organs of clams exposed to no. 2 fuel oil, but the disorders were not neoplastic. Therefore, we concluded that petroleum was unrelated to the development of germinomas in softshell clams.

*U.S. Environmental Protection Agency, Environmental Research Laboratory/Narragansett, 27 Tarzwell Drive, Narragansett, RI 02882.

†Maine Department of Marine Resources, Fisheries Research Laboratory, West Boothbay Harbor, ME 04575.

‡Registry of Tumors in Lower Animals, National Museum of Natural History, Smithsonian Institution, Washington, DC 20560.

Address reprint requests to G. R. Gardner, U.S. EPA, ERL/N, 27 Tarzwell Drive, Narragansett, RI 02882.

Coincidentally, on two occasions, Maine softshell clams obtained from a shellfish supplier for laboratory tests were found to have germinomas. Since the shellfish industry in Maine is regulated, we were able to locate the site in eastern coastal Maine where those Mya were collected by commercial shellfishermen. An epidemiological survey of Mya was conducted in the eastern coastal region to identify the site and make historical and physical comparisons to Searsport. We found three geographically distinct populations of Mya with germinomas. Agrochemicals (2,4-D, 2,4,5-T, and Tordon 101) used in blueberry agriculture and forestry represent the dominant chemical influence at those locations. Our report summarizes ERL/N laboratory studies and field surveys since the 1971 oil spill at Searsport and presumptive evidence that links the occurrences of germinomas with the use of herbicides.

Materials and Methods

The original germinomas were found in clams collected by the Maine Department of Marine Resources at the Searsport oil spill

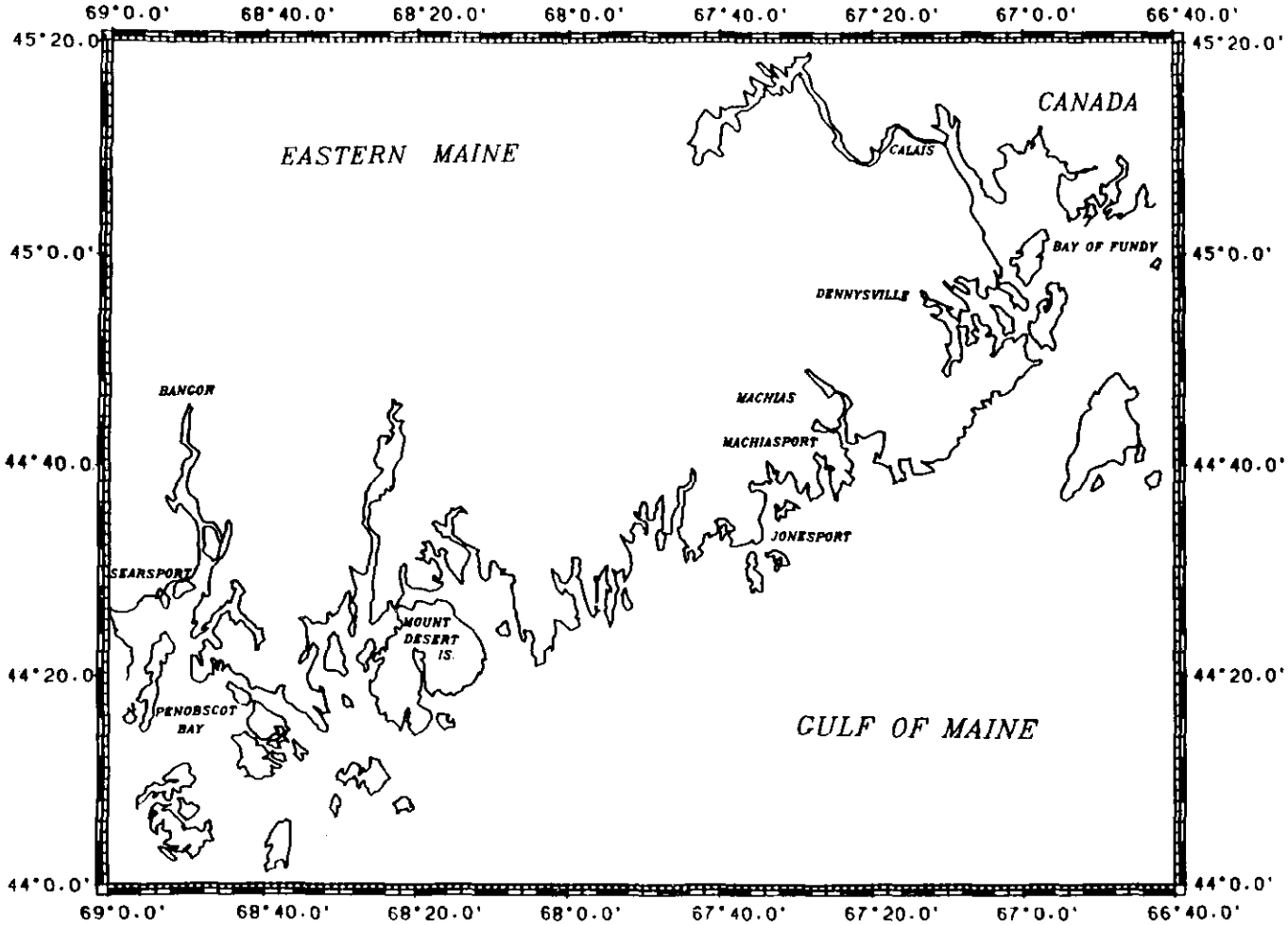

FIGURE 1. Eastern coastal region of Maine.

site. The *Mya arenaria* that were subsequently obtained for oil exposure studies in the EPA laboratory and found to have germinomas were purchased from Maine through a Rhode Island shellfish retailer. We were aware that the origin of those animals was in the state's eastern coastal region (Fig. 1), and shellfish registration required of commercial shellfish suppliers by the State of Maine allowed us to trace the tumorous Mya to the general area of Machiasport. A field investigation determined the origin of those Mya by surveying clam flats in the coastal region extending from Jonesport to Machiasport, Maine. Surveys of clam flats conducted by Maine Department of Marine Resources (DMR) field biologists considered potential point and/or nonpoint sources of chemical contamination within major commercial shellfishing areas.

The most significant source of potential chemical contamination of the near coastal clamming areas identified by DMR biologists was the application of herbicides in blueberry agriculture. Estuarine field sites (clamming areas) in our survey were selected on the basis of their proximity to sites where leaching and/or chemical runoff onto intertidal clam flats was greatest. Using those criteria as a guide, DMR biologists gathered site information and selected four shellfish beds in the coastal region that extends east from Jonesport to Machiasport (Fig. 2). Mya were collected in the Indian River and Snare Creek, at three sites in Masons Bay, and at Woodruff Cove. Field collections were made at Roque Bluffs in Great Cove, near Machiasport, after more relevant site information became available to DMR biologists during the course of field studies (Fig. 3).

While we were conducting surveys of clam flats in the near coastal region in 1979, Tordon 101 (Picloram and 2,4-dichlorophenoxyacetic acid as the triisopropanolamine salts), an herbicide also known as agent white, was accidentally sprayed on the community of Dennysville, Maine. The immediate area around Dennysville is drained by the Hardscrabble River, Dennys River, and Hobart Stream, which flow eastward into Dennys, Whiting, and Cobscook Bays. Four hundred twenty-five Mya were collected for histology from five sampling stations at Dennysville (i.e., Hobart Stream, Duck Harbor, Bellier Cove, Wilson/Hardscrabble, and Hallowell Island). Mya collected from nearby Hallowell Island in Dennys Bay served as a reference for pathological evaluations (Fig. 4). Hereafter, Hobart Stream, Duck Harbor, and Bellier Cove are considered one location, Hobart Stream. More than 100 adult Mya were sampled from four previously identified locations in eastern

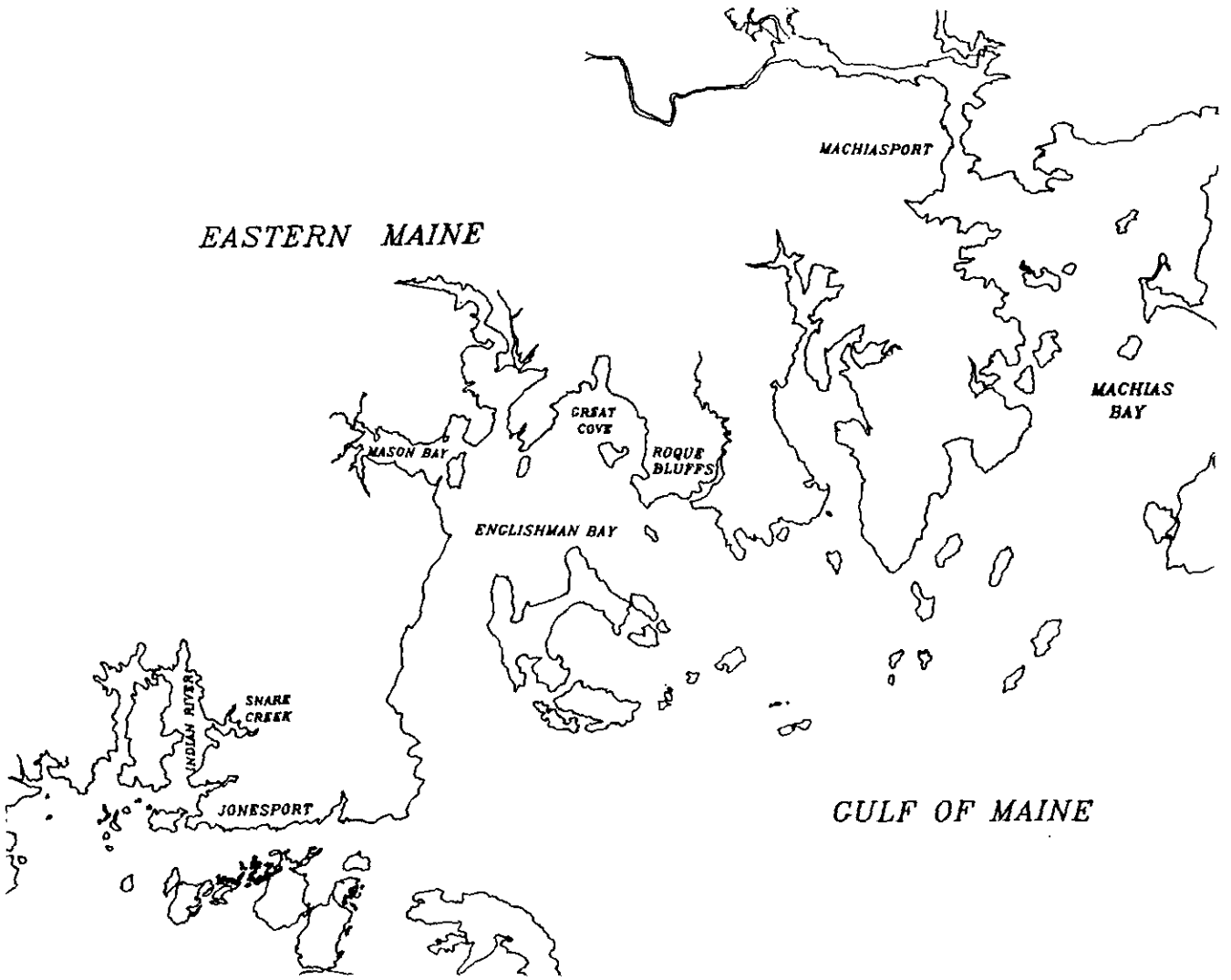

FIGURE 2. Coastal region from Jonesport to Maichiasport, Maine.

coastal Maine (i.e., Indian River, Snare Creek, Masons Bay, and Woodruff Cove). All Mya specimens were collected by DMR/Maine biologists with the exception of Hardscrabble River where both DMR and EPA personnel collaborated during March of 1980. Clams were returned to the DMR Boothbay Marine Research Laboratory where they were held in flowing seawater at ambient salinity and temperature for 48 hr. Animals were then packaged for live shipment to ERL/N for histological processing and evaluation. Animals collected at Hardscrabble River were taken directly to ERL/N.

Histopathological Protocol

Softshell clams were opened between the mantle and valve with a shellfish knife. Whole animals were placed in Helly's fixative for 15 to 30 min, sectioned on a sagittal plane along 95% of the midline, and reimmersed in fixative overnight. During final trimming, the midline cuts were finalized and the animals transectioned. Tissue quadrants were trimmed to 2 to 3 mm in thickness, washed overnight, embedded in paraffin, cut at 6 μm, and stained with Harris hematoxylin and eosin. Microslides were histopathologically evaluated, and assorted cases were deposited in the Registry of Tumors in Lower Animals (RTLA# 1275-1374, 1448-1461, 1501-1515, 1694-1703, 4046).

Chemical Analyses

Trace organic analyses were conducted on pooled clam samples from Hardscrabble River, Hobart Stream, and a reference site. The samples were extracted with acetonitrile using a Polytron homogenizer (Brinkman Co., Westbury, NY) and then back-extracted into pentane. The pentane extracts were fractionated using silica chromatography with two fractions being collected. The first fraction was analyzed for polychlorinated biphenyls (PCBs), hexachlorobenzene, and *p,p'*-DDE. Hexachlorocyclohexanes, chlordanes, *p,p'*-DDD, *p,p'*-DDT, and polycyclic aromatic hydrocarbons (PAHs) were measured in the second fraction.

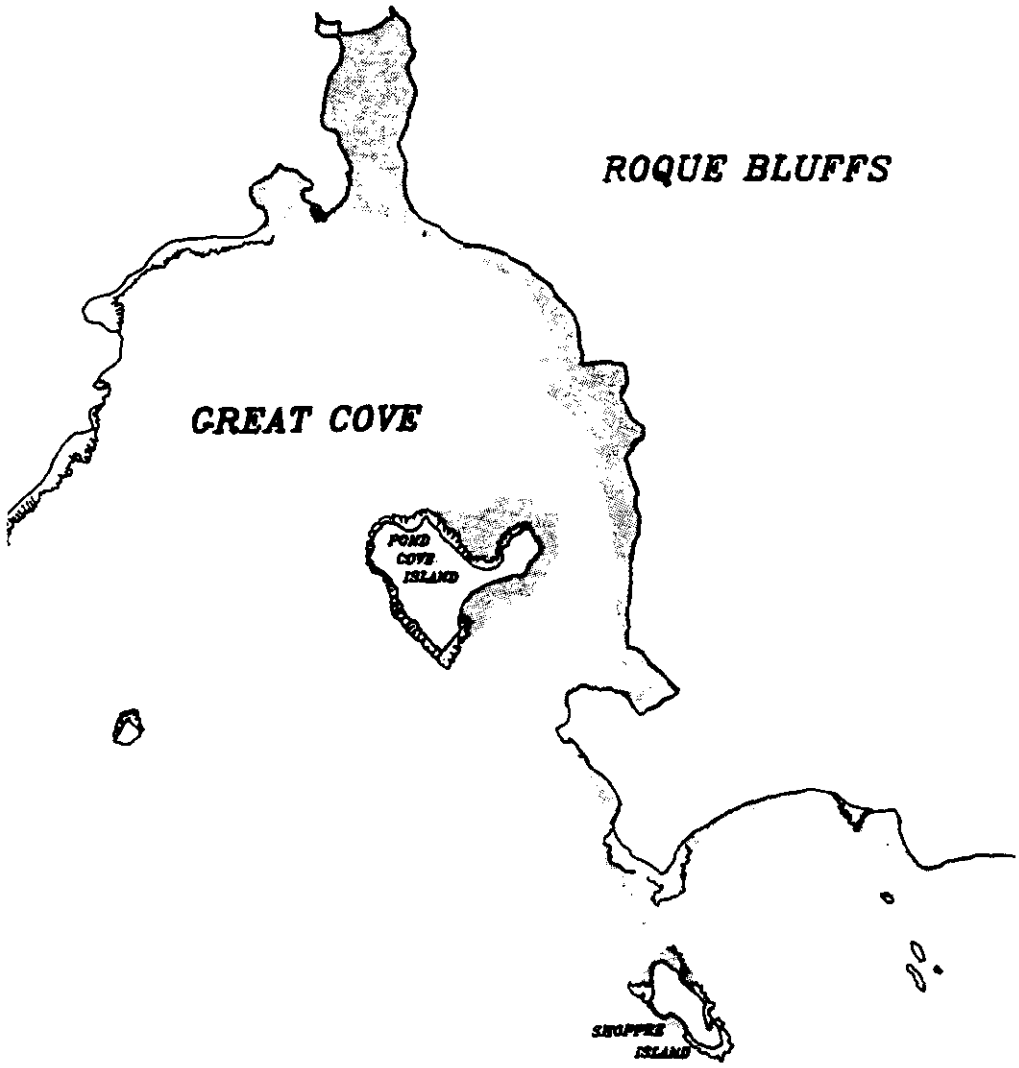

FIGURE 3. Roque Bluffs, Maine.

All of the chlorinated compounds were quantified using a Hewlett Packard 5890 gas chromatograph equipped with a 30-m DB-5 fused silica capillary column (J&W Scientific, Folsom, CA) and an electron capture detector. PAHs were quantified using a Finnigan 4531 quadrapole gas chromatograph-mass spectrometer equipped with a 30-m DB-5 column.

Results

Roque Bluffs

Two (3%) of 58 Mya collected from Great Cove at Roque Bluffs in October 1981 were observed to have gonadal tumors. We believe that commercial shellfishing beds in Great Cove at Roque Bluffs were the origin of tumorous Mya used in our ERL/N oil exposure studies. That conclusion was based on discussions with commercial suppliers, clam diggers, DMR field biologists, land owners and, of course, our histopathological evaluations. Roque Bluffs' area slopes more steeply to the water than other selected sites. Further, active blueberry agriculture was evident on those slopes near the seashore. In contrast, blueberry farming was more removed from the seashore in clamming areas where germinomas were not observed at Indian River, Snare Creek, Masons Bay, and Woodruff Cove.

Dennysville

Gonadal tumors were found in Mya collected from Hardscrabble River and Hobart Stream in our preliminary investigations of the Dennysville area sprayed with Tordon 101. This included four Mya collected from Hardscrabble River by a Dennysville

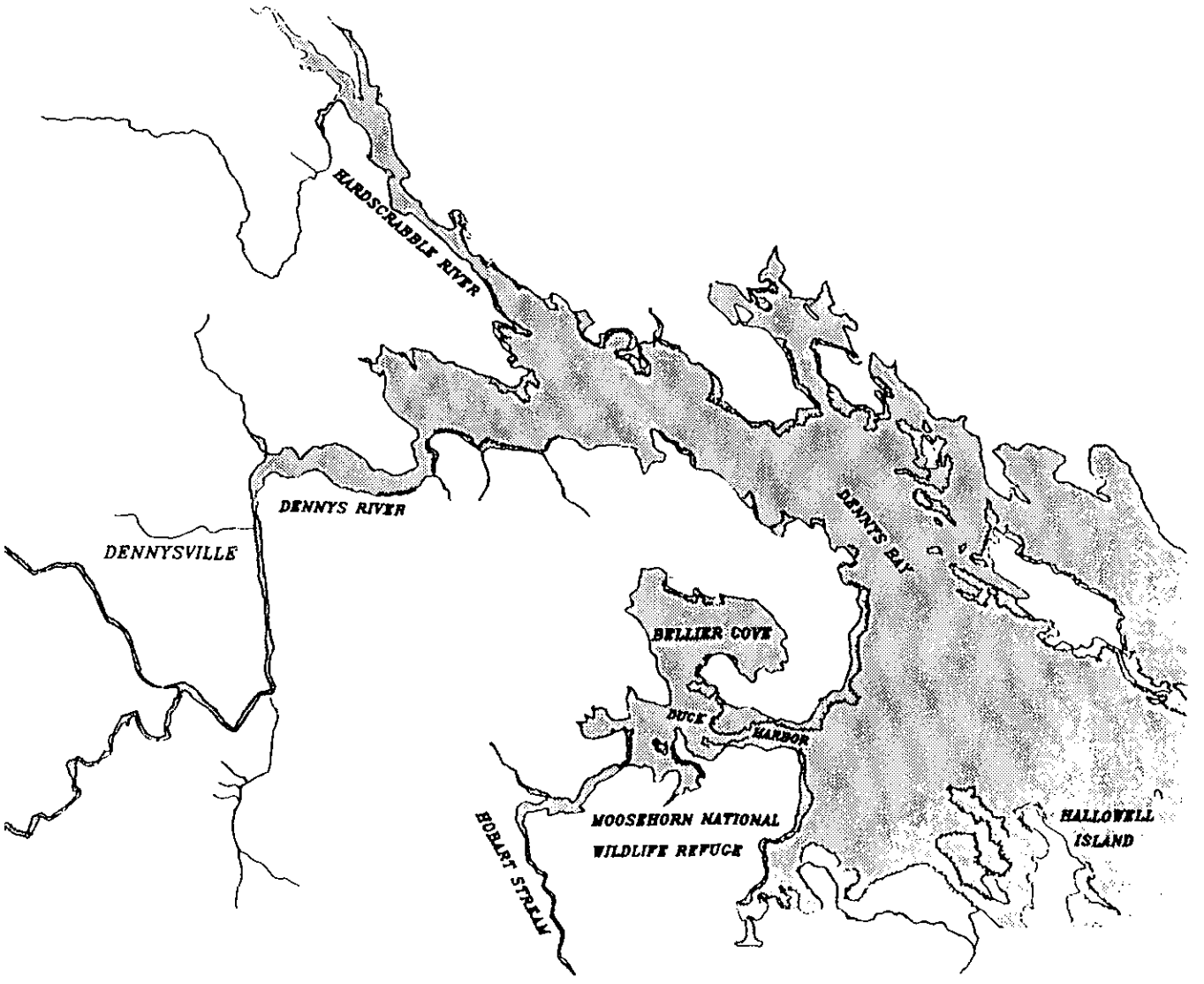

FIGURE 4. Dennys Bay and Hallowell Island, Maine.

resident and a 34% prevalence of germinomas in Mya collected from Hobart Stream. In follow-up studies, tumor prevalence was 28 and 36% in Mya collected from two sites in Hobart Stream located 100 m apart. Prevalence of germinomas in Mya collected from three locations in Hardscrabble River was 32, 32, and 40%. Germinomas were not observed in Mya collected from the Hallowell Island reference station.

Gonadal tumors observed in Mya from Hobart Stream and Hardscrabble River were histologically similar to the germinomas in Mya collected from Searsport (*1*). Both testicular and ovarian neoplasms were characterized by gonadal follicles filled with monomorphic, basophilic, undifferentiated germ cells, dissemination of these neoplastic cells into the reproductive ductal system and metastases of single cells and small cell clusters to other organs.

Supernumerary Siphons

Three of four Mya collected from the Hardscrabble River by a Dennysville resident had supernumerary siphons. Dysmorphic siphons were visible following removal of the melanized epidermal layer covering the primary siphon. Lateral development (i.e., perpendicular to axis of the incurrent and excurrent siphon) was then discernable as a fleshy nodule 1 to 2 mm in diameter that ranged from 1 to 4 mm in length. Grossly visible growths were histologically typical of normal siphons, except for incomplete morphological and functional development.

Supernumerary siphons were observed in 7% of the Mya collected from Hardscrabble River; none were observed in Mya collected from Hobart Stream. Siphon alterations ranged in size from 1 × 1 mm nodules to complete morphological and functional supernumerary siphon development (Fig. 5). Generally, the smaller, less-developed growths were located in the proximal section of the primary siphon, while intermediate, or more fully developed anomalies were distally located. Fully developed ancillary siphons most commonly occurred as bifurcations oriented laterally from 0 to 90° in relation to the primary

FIGURE 5. Supernumerary siphons on softshell clams collected from the Hardscrabble River near Dennysville, Maine.

siphon opening. The bifurcation generally occurred within the apical 10 mm of the normal primary siphon when it was fully extended. Ancillary siphon stalks ranged from 3 to 10 mm in length with primary siphon protracted, however they were inconspicuous when retracted. Observed anomalies were positioned on either of the primary chambers (i.e., branchial incurrent/cloacal excurrent) of a siphon. In either case, the ciliary type and associated pigmentation corresponded to the primary chamber of the individual supernumerary siphons. All specimens having the siphon disorder also had gonadal tumors.

Of the specimens examined for supernumerary siphons, one was found to have two incurrent and two excurrent chamber openings symmetrically positioned in the normal apical location. Paired chamber openings representative of primary incurrent and excurrent siphons were morphologically identical. As these paired openings were both symmetrical and morphologically alike, no distinction could be made between primary and secondary siphon development.

Mesotheliomas

Multiple mesotheliomas were observed in heart auricular and ventricular epicardium in two of four Mya collected from Hardscrabble River by the Dennysville resident. The lesions were typically encapsulated, pedunculate masses projecting outward into the pericardial cavity. The tumor presented both solid and glandular patterns. Hemispherical neoplasms in the auricle were solid masses, composed of uniformly chromatic, rounded cells with infrequent mitosis (Fig. 6). The tumor had a delicate, somewhat wispy stroma. The highly cellular tumor was supported on a wide base. At the point of origin, slight or shallow penetrating pegs of elastic fiber penetrated the tumor. Supporting pegs of the neoplasm were greatly expanded, folded elastic bands derived from and contiguous with normal histomorphological elements of the auricle wall. Bridging of the neoplasm,

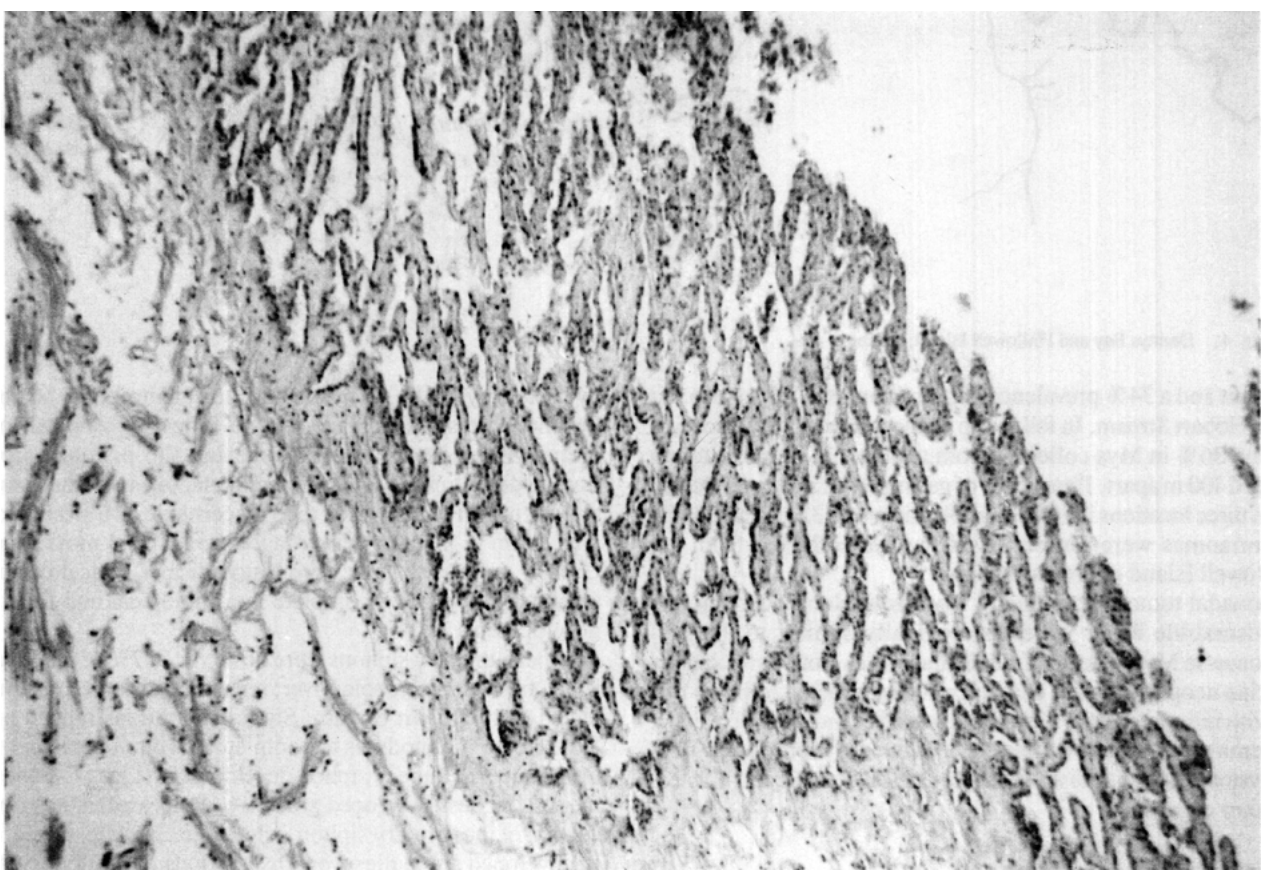

FIGURE 6. Light micrograph of a mesothelioma in the heart of a softshell clam collected from the Hardscrabble River. Spaces lined by active epicardium contain formed elements of the hemolymph.

projecting from the auricle to pericardial wall, was apparent in one case.

Advanced mesotheliomas with a glandular pattern were observed projecting from the ventricle. Uniformly narrow bands of tissue integrated in an alternating fashion with elongate or ovoid spaces produced the glandular pattern. Histologically, the stroma was composed of cardiac muscle marginated with the active layer of cells. The mesothelial cells formed a simple squamous to cuboidal lining on all exposed surfaces. The intervening ovoid spaces were vascular in nature, containing formed elements of the hemolymph. Mitosis was infrequent. Mesothelial cells appeared layered on the ventricular surface in emerging areas of the lesion.

Chemistry

The levels of chemical contaminants in the clam samples from all three locations were very low. Only trace levels of PCBs were detected in the Hardscrabble River and Hobart Stream clams. A higher PCB concentration (120 ng/g dry weight) was found in the sample collected from the reference site. All other chlorinated compounds that were quantified were found in concentrations less than 5 ng/g.

Low levels of PAHs could be measured in the clams from all three of the sites. Similar distributions of PAH compounds were found in samples from each of the locations. Fluoranthene and pyrene were the compounds found in the highest levels (12.8–38.7 ng/g). Clams from the Hardscrabble River contained concentrations of fluoranthene and pyrene near the lower end of the range and those from the other two locations had levels of these compounds nearer to the higher end of the range. The concentration of the carcinogenic PAH, benz(*a*)pyrene, ranged from 3.06 to 4.29 ng/g between stations. The PAH distribution was dominated by parent compounds with much lower levels of the alkyl homologs and indicates that combustion processes were probably the sources of those compounds.

Discussion

Germinomas were observed in Mya collected at Great Cove in the Roque Bluffs area near Machiasport and in Mya collected at Hobart Stream and Hardscrabble River near Dennysville. The gonadal neoplasms observed in Mya from Roque Bluffs and Dennysville were histologically similar to those originally described in Mya from Searsport (*1,3*). Prevalence of germinomas was highest in Mya from Hardscrabble River (mean,35%) when compared to the other locations, including Searsport (22%). In consideration of Mya's historical record at Searsport (*1,3,4*), we believe these epidemiological studies were meaningful from at least two standpoints: First, in contrast to the petroleum hydrocarbon contamination associated with the Searsport Long Cove environment, none of the currently reported sites (i.e., Hobart Stream, Hardscrabble River and Great Cove at Roque Bluffs) have a known history of oil contamination (chemical analyses have not been performed on sediment from all three sites to determine the PAH concentrations, however). Laboratory studies prompted by the 1971 Searsport oil spill were based on presumptive evidence that no. 2 fuel oil and JP-4 jet fuel acted as carcinogens or otherwise influenced tumor development. Histopathological evaluations were performed on Mya exposed to no. 2 fuel oil, JP-4, and JP-5 jet fuels in long-term tests (45–360 days) in the laboratory both singly and as mixtures. Water accommodated and sediment fractions with nominal concentrations ranging from 10 ppb to 10 ppm and 1 ppm to 1000 ppm, respectively, were tested in a system featuring tidal cycling. Tidal fluctuations were included because of their influence on reproductive behavior in the softshell clam. A histopathological relationship between gonadal tumors in Mya and petroleum hydrocarbons was not evident in Mya exposed in these and other laboratory and field studies at ERL/N. Concurrent with ERL/N laboratory and field research efforts, Brown and his colleagues (*4*) investigated other shellfish beds in New England. Collectively, Brown's field investigations spanned the Atlantic range of the species from Chesapeake Bay to Nova Scotia and included known oil-impacted sites. Brown did not detect other occurrences of gonadal tumors in Mya (*4*). Thus, histopathological evidence obtained by other researchers also suggests that petroleum hydrocarbons did not cause the observed neoplasia.

Secondly, our results demonstrated a 35% mean prevalence of tumors in animals collected near Dennysville, which provides an opportunity to research mechanisms of gonadal neoplasia. Historically, tumors in bivalves are considered to be relatively common in comparison to other molluscan classes. Reports of spontaneous tumors in bivalves mostly represent isolated cases of grossly visible neoplasms such as mantle papillomas and internal neoplasms, mostly represented by disseminated sarcoma of probable hemic origin. Investigations have demonstrated that internal neoplasms of other than hemic origin in invertebrates from any one species, or in a defined population, remain a rare occurrence (*5–15*).

Beyond the 1971 oil spill, we have attempted to determine what environmental factors were common to all three sites. Searsport Long Cove may still be chronically influenced by point and nonpoint sources of pollution emanating from light industrial activities, but similar activities were not identified in the estuarine environments surveyed near Dennysville and Machias. The only other major source of chemical pollution identified by our investigations in the area of study was widespread use of agrochemicals in blueberry agriculture and silviculture.

Our investigations revealed that herbicides were applied at all three locations (Searsport, Dennysville, Roque Bluffs) where Mya had gonadal neoplasia. A variety of herbicides continue to be used in local blueberry agriculture (USDA, personal communication). Significant quantities of herbicides (i.e., Tordon 101, 2,4-D, 2,4,5-T) were once used at Roque Bluffs based on conversations with local landowners active in blueberry farming. The Searsport and Dennysville sites, in comparison, did not have blueberry agriculture that could have influenced tumor development in the Mya indigenous to our areas of study. However, we confirmed that herbicides were applied near Searsport and Dennysville. Herbicides commonly used for weed control on rail road rights-of-way were applied to a railroad that borders the perimeter of Long Cove estuary. Gonadal tumor prevalence in Mya was also elevated where Long Cove Brook empties into Long Cove and in clam flats along the northeast and northwest shores of the estuary. A potentially significant source of herbicides in Long Cove Brook is a highway department practice of cleaning spray equipment.

In Dennysville, the Dennys and Hardscrabble Rivers and Hobart Stream represent the major drainage conduits to the sea from the watershed area where Tordon 101 was sprayed on forested land in 1979 and where significant quantities of 2,4,5-T have been applied in the past. Evidence of herbicide usage in the Dennysville area was observed soon after the Tordon 101 accident. Chemical analyses for 2,4-D were positive in water from Duck Cove (trace amounts in Hobart Stream) and on vegetation from Moosehorn Wildlife Refuge (57 ppm), clear-cut sections of forest (54–66 ppm), and in hay (1 ppm) from a farm located near Hobart Stream where clams with germinomas were collected (*16,17*). In Washington County, an estimated 8 to 10,000 acres of forested land were sprayed with 2,4,5-T from about 1963 until 1978 when 2,4,5-T was banned. Precise information could not be obtained about volumes of herbicides sprayed prior to 1979 because records were not required. Thus, Mya located in the Dennys River system at the fresh and salt water interface have likely been exposed to herbicides for many years.

We have not quantified herbicide bioaccumulation in clams collected from the Dennysville area. Analyses of clams collected from Hardscrabble River and Hobart Stream provided no herbicide exposure information. In laboratory experiments at the EPA Pesticides Monitoring Laboratory at Bay St. Louis, Missouri, Tordon 101 was undetected in crayfish exposed to that compound. Data obtained from crayfish exposures suggests positive detection of parent compounds and/or metabolites would also be unlikely in clams (R. Maxie, personal communication). Herbicides 2,4-D, 2,4,5-T or Tordon 101 behave as polar compounds that can be easily metabolized and therefore may not persist at detectable levels in aquatic organisms such as crayfish and clams. Dioxin (2,3,7,8-tetrachlorodibenzo-*p*-dioxin), a contaminant of 2,4,5-T, behaves as a nonpolar, stable compound that may be a better indicator of exposure.

After identifying herbicides as the common denominator to all three locations where Mya had the gonadal disorder, we learned from Howard Hayes, a veterinary epidemiologist with the National Cancer Institute, that a parallel exists between occurrence of a comparable neoplasm (seminoma) in military working dogs. A significant excess (1.7-fold increase) of seminomas exists in military working dogs that served and died in Vietnam between January 1967 and December 1972 in comparison to those that served and died in the contiguous United States. For certain, one major difference in the military working dogs in Vietnam and the United States was the greater opportunity for exposure to defoliating herbicides in Vietnam. Since the seminomas and dysgerminomas observed in softshell clams collected at Searsport, Roque Bluffs, and Dennysville compare histologically with the same disorder in mammals (*1,4*), we believe the neoplastic condition in Mya to be homologous with seminomas in military working dogs. On the basis of our combined observations, we conclude that laboratory studies and a closer examination of herbicide usage near marine or estuarine shellfish resources are warranted.

Pericardial tumors in the oyster and bivalves, first described by Ryder (*18*) in 1887, have been reported several times since (*19–22*). Spontaneous tumors in the heart and pericardial cavity of the oyster reported to date were of mesenchymal origin (*15*). Experimentally induced myxomas in the heart of oysters and of mussels exposed in the laboratory to contaminated sediment from Black Rock Harbor, Connecticut, demonstrated the carcinogenic potential of contaminated sediment (*23,24*). The contaminated sediment from Black Rock Harbor contains known genotoxic carcinogens, co-carcinogens, and tumor promoters (*25*). Thus, a number of spontaneous and experimental pericardial and heart tumors have been reported for bivalves, but mesotheliomas of the heart and pericardial cavity are conspicuously absent from recent reviews and unreported at the Registry of Tumors in Lower Animals. At present, etiology of the softshell clam mesothelioma is not readily apparent.

The 1925 descriptions of supernumerary siphons in one specimen of Mya by Sigilas (*26*) and in two animals by Tubiash et al. (*27*) were similar to the morphological and histological characteristics of those observed in Mya collected from Hardscrabble River. Those authors reported the siphon disorder in Mya to be an infrequent finding. In comparison, our observation of 7% prevalence in animals collected from Hardscrabble River is unusually high. A corollary expression of the atypical characteristic was reported in siphons of a tunicate population located near Dennysville in the Bay of Fundy. Supernumerary siphons observed in urochordates (*Halocynthia pyriformis*) collected from Lord's Cove, Deer Island, New Brunswick, Canada (RTLA# 1018-1020) were described as 5-mm diameter lesions that protruded several millimeters from the tunic surface (*33*). Deer Island is located within 10 statute miles of Dennysville, Maine. Occurrence of similar siphon disorders in two different invertebrate species inhabiting the same ecosystem fuels speculations for a common etiological source. Etiology of both tunicate and softshell clam supernumerary siphons remains uncertain. Although we cannot demonstrate a relationship between herbicides and the teratoid siphons, there is abundant evidence to suggest that these Mya were potentially exposed to the known teratogens 2,4-D and 2,4,5-T (*29,30*). It is also possible the siphon anomalies represent an inherited expression unrelated to herbicides as they were not in use in 1925.

Proliferative diseases in aquatic organisms serve to remind us that toxic substances in surface waters and sediments may represent a significant problem (*25,31–33*). Despite gains in water quality made by implementation of the 1972 Clean Water Act, more emphasis must be placed on nonpoint sources such as agriculture, silviculture, urban runoff, and leachate from landfills. Our evidence suggests that a chemical or biological etiology unrelated to point source pollution will ultimately be associated with gonadal neoplasia in molluscs.

The germinomas in clams from Dennysville (Washington County, Maine) coincided with increased human mortality from testicular and ovarian cancer in the same county between 1970 and 1979 (*34*). Temporal data showed an increase in cancers of the ovary in white females and of the testis in white males between 1950 and 1979. The research and epidemiological evidence cited here suggest a relationship between presence of tumors in selected organisms of marine ecosystems and tumors within the human population. The possibility that phenoxy herbicides cause these tumors should be studied directly because Washington County forests have been treated extensively since the 1960s with herbicides to control broadleaf plants. In fact, Hayes (*35*) linked these herbicides to testicular cancer in dogs exposed in Vietnam and suggested a human health risk for testicular cancer in Vietnam veterans similarly exposed.

We thank biologists Hal Winters, Stuart Sherburne, Gareth Coffin, and Mac Richards at the Maine Department of Marine Resources, Fishery Research Laboratory, West Boothbay, Maine, and Tom LeFoley for their assistance with field collections in eastern coastal Maine. We thank Han Tai and Robert Maxie (U.S. EPA, Pesticides Monitoring Laboratory, Bay St. Louis, Missouri) for performing chemical analyses on sediments from clamming areas near Dennysville. We especially thank Robert H. MacAllister, Dennysville, Maine, for providing softshell clams collected from Hardscrabble River following the accidental spraying of Tordon 101 and for his general assistance in our field studies. Special thanks are extended to Leroy Folmar for his scientific, technical, and editorial contributions to the manuscript. This work was supported in part by NIH contract NO1-CP-61063 to the Smithsonian Institution.

REFERENCES

1. Barry, M., and Yevich, P. P. The ecological, chemical and histopathological evaluation of an oil spill site. III. Histopathological studies. Mar. Pollut. Bull. 6(11): 164–173 (1975).
2. Gilfillan, E. S., Hanson, S. A., Page, D. S., Mayo, D., Cooley, J., Chelfant, J., Archambeault, T., West, A., and Harshbarger, J. C. Final Report to the Department of Environmental Protection. August 1977, Augusta, ME.
3. Yevich, P. P., and Barszcz, C. A. Neoplasia in soft-shell clams (*Mya arenaria*) collected from oil-impacted sites. Ann. N.Y. Acad. Sci. 298: 409–426 (1977).
4. Brown, R. S., Wolke, R. E., Saila, S. B., and Brown, C. W. Prevalence of neoplasia in 10 New England populations of the soft-shell clam (*Mya arenaria*). Ann. N.Y. Acad. Sci. 298: 522–534 (1977).
5. Couch, J. A., and Harshbarger, J. C. Effects of carcinogenic agents on aquatic animals: an environmental and experimental overview. Environ. Carcinog. Rev. 3(1): 63–105 (1985).
6. Dawe, C. J. Comparative neoplasia. In: Cancer Medicine (J. F. Holland and E. Frei III, Eds.), Lea and Febiger, Philadelphia, PA, 1982, pp. 209–256.
7. Farley, C. A. Proliferative disorders in bivalve mollusks. Mar. Fish. Rev. 38(10): 30–33 (1975).
8. Kraybill, H. F., Dawe, C. J., Harshbarger, J. C., and Tardiff, R. G., Eds. Proceedings of Conference on Aquatic Pollutants and Biological Effects with Emphasis on Neoplasia. Ann. N.Y. Acad. Sci. 298: 1–604 (1977).
9. Mix, M. C. Cancerous diseases in aquatic animals and their association with environmental pollutants: a critical literature review. Mar. Environ. Res. 20: 1–141 (1986).
10. Mix, M. C. Shellfish diseases in relation to toxic chemicals. Aquat. Toxicol. 11: 29–42 (1988).
11. Pauley, G. B. A critical review of neoplasia and tumor-like lesions on mollusks. In: Neoplasia and Related Disorders in Invertebrates and Lower Vertebrate Animals. Natl. Cancer Inst. Monogr. 31: 509–539 (1969).
12. Pauley, G. B., and Sayce, C. S. An internal fibrous tumor in a Pacific oyster, *Crassostrea gigas*. J. Invert. Pathol. 1–8 (1968).
13. Pauley, G. B., Sparks, A. K., and Sayce, C. S. An unusual internal growth associated with multiple watery cysts in a Pacific oyster (*Crassostrea gigas*). J. Invert. Pathol. 11: 398–405 (1968).
14. Sparks, A. K. Invertebrate Pathology, Noncommunicable Diseases. Academic Press, Inc., New York, 1972.
15. Sparks, A. K. Synopsis of Invertebrate Pathology. Elsevier Science, New York, 1985.
16. Richardson, E. M. Report of Pesticide Residue Analysis. Memorandum to D. Mairs, Pesticide Control Board, State of Maine, July 20, 1979, Augusta, ME.
17. Adams, W. S. Memorandum to J. Hurst, Department of Marine Resources, Maine. December 4, 1979, West Boothbay Harbor, ME.
18. Ryder, J. A. On a tumor in the oyster. Proc. Acad. Nat. Sci. Phila. 39: 25–27 (1887).
19. Dinamani, P., and Wolf, P. H. Multiple tumors in the pericardial cavity of an Australian rock oyster, *Crassostrea commercialis* (Iredale and Roughley). Int. J. Cancer. 11: 293–299 (1973).
20. Smith, G. M. A mesenchymal tumor in an oyster (*Ostrea virginica*) Am. J. Cancer. 22: 838–841 (1934).
21. Sparks, A. K., Pauley, G. B., Bates, R. R., and Sayce, C. S. A mesenchymal tumor in a Pacific oyster, *Crassostrea gigas* (Thurnberg). J. Insect Pathol. 6: 453–456 (1964).
22. Mix, M. Multilobed polypoid neoplasm of pericardial mesothelium associated with a marked proliferation of connective tissue differentiating into heart muscle. RTLA #1168, *Ostrea lurida* (1975).
23. Gardner, G. R., and Yevich, P. P. Comparative histopathological effects of chemically contaminated sediment on marine organisms. Mar. Environ. Res. 24: 311–316 (1988).
24. Gardner, G. R., Yevich, P. P., and Harshbarger, J. C. Cancer in American oysters (*Crassostrea virginica*) and winter flounder (*Pseudopleuronectes americanus*) exposed experimentally to contaminated sediments (abstract). In: Conference Handbook of the Proceedings of the American Fisheries Society International Fish Health Conference, Vancouver, B.C., Canada, July 19–21, 1988.
25. Gardner, G. R., Yevich, P. P., Malcolm, A. R., Rogerson, P. F., Mills, L. J., Senecal, A. G., Lee, T. C., Harshbarger, J. C., and Cameron, T. P. Tumor development in American oysters and winter flounder exposed to a contaminated marine sediment under laboratory and field conditions. Aquat. Toxicol. 11: 403–404 (1988).
26. Sigilas, R. Sur un cas de bifucation du siphon chez "Mya arenaria." Proces-Verbaux, Soc. Linn. Bordeaux 78: 55 (1926).
27. Tubiash, H. S., Shuster, C. N., Jr., and Couch, J. A. Anomalous siphons in two species of bivalve mollusks. Nautilus 81: 120–125 (1968).
28. Anderson, R. S., Jordan, L. A., and Harshbarger, J. C. Tunic abnormalities of a urochordate *Halocynthia pyriformis*. J. Invert. Pathol. 30: 160–168 (1977).
29. Courtney, K. D., Gaylor, D. W., Hogan, M. D., Falk, H. L., Bates, R. R., and Mitchell, I. A. Teratogenic evaluation of pesticides: a large-scale screening study. Teratology 3: 199 (1970).
30. Schildkraut, J. J., Winokur, A. W., and Applegate, C. W. Teratogenic evaluation of 2,4,5-T. Science 168: 864–868 (1970).
31. Gardner, G. R., Yevich, P. P., Malcolm, A. R., Pruell, R. J., Rogerson, P., Lee, T. C., Senecal, A., Heltshe, J., and Mills, L. J. Carcinogenic Effects of Black Rock Harbor Sediment on American Oysters and Winter Flounder. Report to National Cancer Institute. U.S. EPA, Narragansett, RI, 1987.
32. Harshbarger, J. C., and Clark, J. B. Enzootiology of neoplasms in North American bony fishes. Sci. Total Environ. 94: 1–32 (1990).
33. Malins, D. C., McCain, B. B., Brown, D. W., Sparks, A. K., Hodgins, H. O., and Chan, S. -L. Chemical Contaminants and Abnormalities in Fish and Invertebrates from Puget Sound. NOAA Technical Memorandum OMPA-19, National Oceanic and Atmospheric Administration, 1982.
34. Riggan, W. B., Creason, J. P., Nelson, W. C., Manton, K. G., Woodbury, M. A., Stallard, E., Pellom, A. C., and Beaubier, J. U.S. Cancer Mortality Rates and Trends, 1950–1979. Vol. IV: Maps. EPA/600/1-83/015e, U.S. EPA, Health Effects Research Laboratory, Research Triangle Park, NC, 1987.
35. Hayes, H. M., Tarone, R. E., Casey, H. W., and Huxsoll, D. L. Excess of seminomas observed in Vietnam Service U.S. military working dogs. J. Natl. Cancer Inst. 82(12): 1042–1046 (1990).