Environmental Health Perspectives
Vol. 93, 181–189, 1991

Biochemical Markers Associated with the Stages of Promotion and Progression during Hepatocarcinogenesis in the Rat

by H. C. Pitot,* Y. Dragan,* L. Sargent,* and Y.-H. Xu*

Specific biochemical changes occurring during hepatocarcinogenesis have been sought by many investigators. The development of multistage models for hepatocarcinogenesis in the rodent has renewed interest in such marker alterations in preneoplastic as well as neoplastic hepatocytes. Preneoplastic altered hepatic foci (AHF) exhibit specific histomorphologic changes as viewed with tinctorial stains and show a variety of biochemical changes as evidenced by enzyme and immunohistochemistry and by other histochemical markers. During the reversible stage of promotion when AHF are scored by multiple markers, the distribution of markers within these lesions differs with the use of different promoting agents. One interpretation of this finding is that each promoting agent stimulates the replication of a set of initiated cells exhibiting the phenotypic characteristics of a specific programmed phenotype. The same markers score AHF during the stage of progression, but many AHF in this stage are phenotypically heterogeneous, exhibiting in tissue sections a "focus-in-focus" pattern of marker alteration. These latter changes can be correlated with the appearance of karyotypic alterations in preneoplastic hepatocytes. On the other hand, it has been difficult to demonstrate the activation, either mutational or transcriptional, of proto-oncogenes until this stage of progression in rat hepatocarcinogenesis. Thus, a study of biochemical and molecular markers during the stages of hepatocarcinogenesis may lead to a better understanding of potential mechanisms involved in the development of neoplasia through the stages of initiation, promotion, and progression.

Introduction

The multistage nature of neoplastic development has now been demonstrated during carcinogenesis in numerous organs in the mammal (*1*) as well as in cell culture (*2*). While a variety of "intermediate" lesions have been described in the development of various neoplasms in both animals and humans (*3*), one of the best studied and most easily quantitated experimental multistage models is seen in rat hepatocarcinogenesis (*4*).

Prominent among early investigations of experimental carcinogenesis of the liver were those of Farber (*5*), Goldfarb and Zak (*6*), and Gössner and Friedrich-Freksa (*7*). In the former two laboratories (*5,6*), the importance of lesions known as "regenerating nodules" in the pathogenesis of hepatocellular carcinoma was proposed. The latter investigators (*7*), on the other hand, described focal cellular alterations in hepatocytes characterized by a deficiency in the histochemical staining of the enzyme glucose-6-phosphatase. These investigators, particularly in a later study (*8*), suggested that these focal lesions or "islands" played a role in the development of carcinoma or in some instances were themselves the direct precursors of malignant hepatic lesions. Similar focal lesions identified by hematoxylin and eosin (H & E) stains were later described in both rats (*9*) and mice (*10*), although in the latter instance there was no distinction between benign neoplasia, preneoplasia, and hyperplasia.

After these earlier studies, other histologic and histochemical characteristics of such islands, or altered hepatic foci (AHF) as referred to in this text, were described. Hori (*11*) and later Kitagawa (*12*) described several histochemical alterations in focal lesions in livers of rats administered 3′-methyl-4-dimethylaminobenzene (3′-MDAB) or 2-acetylaminofluorene (AAF), respectively, in the diet. Later, Bannasch and his associates (*13,14*) described the accumulation or glycogen or "glycogenosis" in focal lesions of livers of rats administered several hepatocarcinogens, including thioacetamide and nitrosomorpholine. Prominent among these earlier studies were developments resulting from the observation by Fiala et al. (*15*) of an increased expression of the enzyme γ-glutamyl transpeptidase in both mouse and rat hepatomas. Subsequently, Kalengayi et al. (*16*) demonstrated the presence of γ-glutamyl transpeptidase (GGT) activity in focal lesions of the livers of rats administered aflatoxin B_1, and other studies (*17–19*) confirmed such investigations in both early and late

*McArdle Laboratory for Cancer Research, The Medical School, University of Wisconsin, Madison, WI 53706.
Address reprint requests to H. C. Pitot, McArdle Laboratory for Cancer Research, The Medical School, University of Wisconsin, Madison, WI 53706.

lesions of hepatocarcinogenesis in the rat. More recently, Satoh et al. (*20,21*) demonstrated that the placental form of glutathione *S*-transferase (PGST) is an exceptionally efficient immunohistochemical marker for AHF in rat hepatocarcinogenesis. To date, numerous morphologic and molecular markers for AHF have been described (*22*).

Morphologic and Molecular Markers of Altered Hepatic Foci

Several histologic and histochemical characteristics of AHF were described more than two decades ago (see above), but in the last 15 years numerous investigations have markedly expanded these parameters. The reader is referred to several reviews for a more extensive discussion of this subject (*23–25*).

Morphologic Markers

The morphology of AHF has been studied extensively with the light microscope and standard histologic stains. One of the first attempts at standardization of the nomenclature of such lesions with morphologic characteristics was reported in a 1975 workshop (*26*), when the terms "foci of cellular alteration" and "neoplastic nodules" were used to denote lesions here designated as AHF and as hepatocellular hyperplasia or hepatocellular adenoma in other publications (*27*). A later panel developed a technicolor monograph of the morphology of such lesions (*28*), and a workshop held in Japan in 1985 (*29*) also designated the nomenclature of these lesions in a similar manner.

The detailed histomorphology of AHF has been studied extensively by Bannasch and his co-workers (*14,30*). Their classification of AHF, which extends that of earlier proposals (*26,29*), is descriptive and includes clear-cell, acidophilic-cell, intermediate-cell, tigroid-cell, basophilic-cell, and mixed-cell AHF (*30*). Although most of these lesions were induced by carcinogenic nitrosamines, several studies have also investigated the morphology of spontaneous, or background, AHF. Ward (*31*) found AHF in livers of 2-year-old Fischer 344 rats used as untreated controls in carcinogen bioassays. The morphology of these lesions was quite similar to those of earlier reports. Recently, Harada et al. (*32*) have undertaken a careful quantitative evaluation of such spontaneous AHF in the same strain of animals. In their quantitative investigations they demonstrated that most of these AHF were of the basophilic and clear-cell variety, the former predominantly in females and the latter predominantly as spontaneous lesions in males. In a related study (*33*), these investigators demonstrated that the morphologic characteristics of chemically induced AHF were significantly different from those seen in spontaneous AHF.

Biochemical (Molecular) Markers of Altered Hepatic Foci

The morphologic variations of AHF and their cellular populations (see above) are relatively limited compared with the wide variety of expression of various genes in cells of AHF as monitored by enzyme-, immunohistochemistry, and other histochemical markers. A recent review (*22*) has listed many of these markers and is reproduced in Table 1.

When multiple markers are used to investigate populations of AHF within a single liver, in a number of model systems an extreme degree of molecular (phenotypic) heterogeneity of AHF is evident (*34–36*). On the other hand, there is some, but not absolute, consistency with respect to specific phenotypic markers such as those involved in xenobiotic metabolism, in which a number of cytochrome P-450 isozymes and related phase I enzymes are decreased within AHF and in which phase II enzymes of xenobiotic metabolism such as PGST are increased (*37,38*). Exceptions to this generalization exist (*38*). One of the more ubiquitous markers that has been described recently is a decrease in the expression of the gene for the gap junction protein, connexin 32 (*39*). Heterogeneity has also been noted when a number of monoclonal antibodies to hepatic antigens are used as markers (*40*).

Stages in Hepatocarcinogenesis

The molecular markers noted in Table 1 have been used to study the natural history of hepatocarcinogenesis and especially the characteristics of altered hepatic foci. Numerous models of hepatocarcinogenesis, both multistage and otherwise, have been developed (*41*). In all such models it has been possible to demonstrate distinctive steps or stages, not all of which have necessarily been comparable from model to model. Most such models agree that the stage of initiation results in the irreversible alteration of individual hepatocytes, which then, by clonal proliferation, give rise to AHF, some of the latter developing into hepatocellular carcinomas, usually after expansion into gross nodules (*42–44*). In virtually all models, however, the initial expansion of initiated cell clones is operationally reversible by withdrawal of the promoting stimulus (*1*). Hendrich et al. (*45*) demonstrated this phenomenon in a quantitative manner and also showed that re-administration of the promoting agent continues the stage of promotion in the same number of initiated clones. The operational reversibility of the stage of tumor promotion and the effect of a variety of environmental factors on this stage including age, nutritional status, hormonal environment, etc., have been demonstrated in a number of multistage carcinogenesis models (*46–48*), as well as in the human (*49*); this argues strongly that the development of the stage of promotion is not directly dependent on the induction of genetic alterations. On the other hand, the chronic administration of promoting agents can lead to the development of neoplasia even in the absence of exogenous initiation (*50,51*). This effect is most likely the result of promotion of endogenously or fortuitously initiated cells within the host liver (*4,52*). It is by such a mechanism that promoting agents are carcinogenic.

Table 1. Histochemical reactions of cells of altered hepatic foci in the rat.[a]

Histochemical reactions	Change
Enzyme histochemistry	
Acid phosphatase	−
Aldehyde dehydrogenase	+
Alkaline phosphatase	±
α-Naphthylbutyrate esterase	−
β-Glucuronidase	−
Canalicular ATPase	+
D-T diaphorase	+
Deoxyribonuclease	−
5′-Nucleotidase	+
γ-Glutamyltranspeptidase	+
Glucose 6-phosphatase	−
Glucose 6-phosphate dehydrogenase	+
Glyceraldehyde-3-phosphate dehydrogenase	+
Nonspecific esterase	+
Phosphorylase	−
Ribonuclease	−
Succinic dehydrogenase	±
UDP-glucuronyltransferase	+
Immunohistochemistry	
α-Fetoprotein	±
Albumin (in analbuminemic rats)	+
Albumin (in normal rats)	−
c-*fos* gene product	−
c-Ha-*ras* gene product	+
Connexin 32 (27-kDa gap junction protein)	−
Cytochrome P450) (methylcholanthrene inducible)	±
Cytochrome P450 (phenobarbital inducible)	±
Epoxide hydrolase (PN antigen)	+
γ-Glutamyltranspeptidase	+
Glucose-6-phosphate dehydrogenase	+
Glutathione *S*-transferase (placental form)	+
Glutathione *S*-transferases (A and B forms)	+
Glutathione *S*-transferases (B and C forms)	+
NADPH cytochrome P450 reductase	±
Plasma membrane antigens	±
Pyruvate kinase (liver form)	+
Serine dehydratase	−
Tryptophan oxygenase	−
Other histochemical markers	
Marker (function)	
Fibronectin	±
Glutathione content	+
Iron deficiency	−
Lipid peroxidation	−
Glycogen accumulation	+
In situ hybridization	
Albumin	−
γ-Glutamyltranspeptidase	+

[a] (+) Increased expression of the marker in a significant number or majority of altered hepatic foci (AHF); (−) decreased expression of the marker compared with expression in non-AHF hepatocytes; (±) slight or variable increased and/or decreased expression of the marker relative to non-AHF hepatocytes. From Pitot (*22*). See Pitot (*22*) for original references of each example given in the table.

The final stage of progression, in which malignant neoplasms, karyotypic abnormalities, and enhanced proto-oncogene expression occur, can obviously be identified in all models of multistage hepatocarcinogenesis. The major problem lies in the distinction or boundary between the stages of promotion and progression (*3*).

Marker Expression during the Stage of Promotion

In order to study in a quantitative manner the distribution of phenotypic markers of AHF when multiple markers are used for analysis, suitable methodologies are necessary. Campbell et al. (*53*) developed such a technique for use with three markers, and recently Xu et al. (*36*) have extended this to four markers and potentially even more. Earlier studies by Peraino et al. (*34*) had demonstrated that, when as many as six markers were used, the phenotypic heterogeneity was such that virtually any of the more than 100 combinations of these markers could be qualitatively identified within one or more AHF. Using the quantitative technology described, Xu et al. (*36*) described the variation in the distribution of four markers in AHF of livers of animals subjected to an initiation-promotion protocol, with diethylnitrosamine (DEN) as initiator and phenobarbital (PB) as promoting agent and with age and sex as variables. The distribution ratio of phenotypes in this experiment, based on the "any" category (*36,53*), may be seen in Figure 1 for both males and females in animals that had been initiated and promoted compared with those that received no initiation with DEN but were given PB to promote endogenous or fortuitous AHF. As can be seen, the distributions are significantly different between those focal lesions initiated with DEN, which includes spontaneous AHF as well, but the latter are considerably fewer in number than the former. Furthermore, the distribution changes with age in both sexes. These quantitative changes argue strongly that tumor promotion, as exemplified by the development of AHF in multistage hepatocarcinogenesis, is quite dependent on the environment as well as on the initiating agent itself, on the assumption that spontaneously initiated cells that developed into AHF resulted from agents other than DEN.

An even more dramatic effect can be seen by altering the promoting agent itself. Promotion with PB or with 2,3,7,8-tetrachlorodibenzo-*p*-dioxin (TCDD) (*54*) results in a phenotypic distribution of AHF which is similar between the two agents. However, when one compares the phenotypic distribution of AHF promoted by phenobarbital with that resulting from promotion by three other structurally unrelated promoting agents, C.I. Solvent Yellow 14, chlorendic acid, and tamoxifen, significantly different phenotypic distributions of AHF are seen (Fig. 2) (*55*). In this series PB promotes AHF, all of which can be scored by PGST and GGT (*36*). Chlorendic acid and C.I. Solvent Yellow 14 promote AHF that are detected primarily by their increased expres-

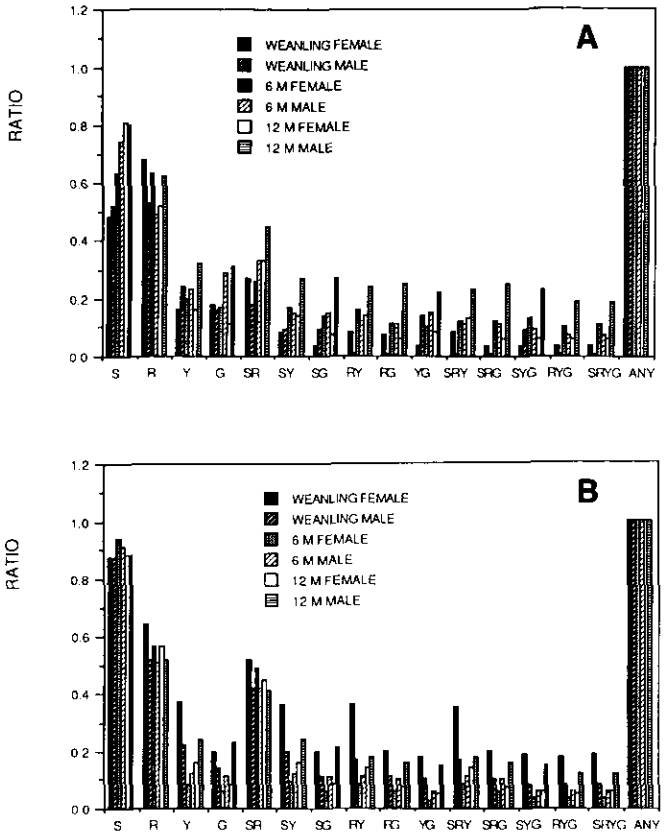

FIGURE 1. Ratios of individual phenotypes of AHF compared with the "any" phenotype in male and female rats as shown after (*A*) promotion with phenobarbital or (*B*) initiation with diethylnitrosamine and promotion with phenobarbital. The marker symbols employed are: S, placental form of glutathione *S*-transferase; R, γ-glutamyl transpeptidase; Y, canalicular ATPase; G, glucose 6-phosphatase; and the combinations as shown. The reader is referred to the original reference for further details (*36*).

sion of PGST. GGT is an inefficient marker of AHF promoted by these agents. This is in contrast to the finding that both PGST and GGT (*56*) are inefficient markers for the class of promoting agents that induce peroxisomes. The fourth promoting agent used in this study, tamoxifen, a synthetic anti-estrogen, demonstrated that glucose 6-phosphatase is the best marker for AHF promoted by this agent.

These distinctive phenotypic distributions of AHF resulting from treatment with different promoting agents may be due to the alteration of expression of specific genes within the AHF by a specific promoter (*57*). This idea has not yet been fully explored, but recent studies by Yeldandi et al. (*58*) suggest that the phenotypic expression induced by promotion with a peroxisome proliferator is not altered by replacement of this promoter with 2-acetylaminofluorene.

Alternatively, a promoting agent may stimulate the proliferation of only the subset of initiated cells that exhibit a specific programmed phenotype. This possibility is supported by the finding of a smaller number of AHF resulting from a given dose of DEN when promoted by agents other than phenobarbital or TCDD (Fig. 2). In addition, the peroxisome proliferators induce a large number of quite small AHF scored by PGST and GGT in addition to large AHF and neoplasms scored by ATPase and G6Pase but not by GGT (*59*). Although these studies suggest that a subset of the initiated cells may be expanded by any single promoting agent, more experimentation is necessary to determine the mechanism of the differential phenotypic distribution resulting from various promoting agents.

Markers during the Stage of Progression

Since it is in the stage of progression that malignant neoplasia develops, specific markers for this stage would, under ideal circumstances, be specific for cancer. As yet, no such marker has been developed under any circumstances or in any system, human or animal. However, certain characteristics of this stage have been tentatively developed in multistage hepatocarcinogenesis.

Since numerous AHF are the first morphologic lesions seen during the process of multistage hepatocarcinogenesis in a number of species, and the number of neoplasms produced by an initiation-promotion protocol is orders of magnitude less than the number of AHF (*36*), one would assume that an intermediate lesion of some sort might be detectable as the immediate precursor of malignancy. The most obvious morphologic lesion ex-

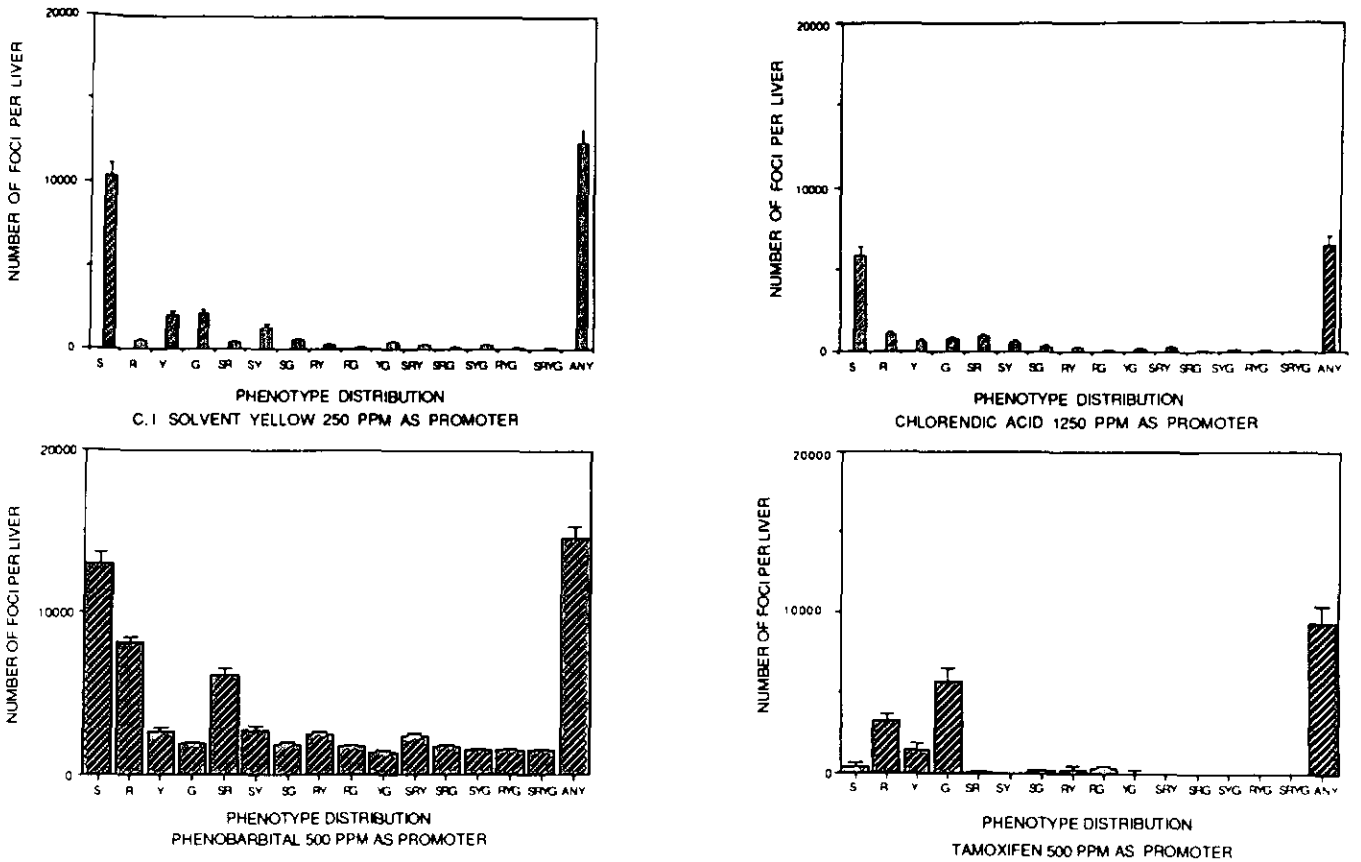

FIGURE 2. Phenotypic distribution of the number of AHF in female rats treated with the various compounds as promoting agents for at least a 6-month period following initiation with diethylnitrosamine. S, placental form of glutathione *S*-transferase; R, γ-glutamyl transpeptidase; Y, canalicular ATPase; G, glucose 6-phosphatase; and the combinations as shown. The reader is referred to the original reference for details (*55*).

hibiting such characteristics is the "carcinoma *in situ*," which occurs in the development of a variety of human and animal organs (*3*).

In multistage hepatocarcinogenesis, the most obvious candidate for such an intermediate lesion is the phenotypically heterogeneous focus termed a "focus-in-focus" (*60*). Such lesions can be induced by the initiation-promotion-initiation (IPI) protocol, as was first demonstrated by Scherer and his colleagues (*61*). Using the techniques of quantitative stereology, we have attempted to extend the earlier results of Scherer and his colleagues through the use of the IPI protocol recently described (*62*). In studies reported earlier (*3*), we were able to show a 2- to 3-fold increase in the numbers of foci-in-foci induced by the IPI protocol compared with control animals that were initiated and then promoted only. However, at best, these studies indicated a qualitative difference, much like studies determining whether one or more malignancies had developed in the experimental animals. Although the quantitative analysis of the total number of AHF could be carried out by the techniques of quantitative stereology (*53*), quantitation of foci-in-foci must be performed in two dimensions, since no technique for the three-dimensional quantitative analysis of such lesions has yet been developed.

As an alternative, it may be possible to determine the number of promotion-independent AHF as a reflection of those AHF entering the stage of progression. Such analyses depend on the reversibility of the stage of promotion in rat hepatocarcinogenesis, as has been established (see above). In this experiment the IPI protocol was employed, but after the second initiation, the promoting agent, PB, was removed from the diet, and the animals were maintained on the diet without any promoting agent. The results of such a study are seen in Table 2.

As can be seen from Table 3, both of the "progressor" agents employed, ethylnitrosourea and hydroxyurea, exhibited a significantly larger number of promotion-independent AHF than did control animals not receiving these compounds. Furthermore, the difference in effectiveness of the two compounds may be reflected in a dramatic difference in the numbers of promotion-independent AHF induced. If one assumes that the control value may reflect those AHF that are still promoted by endogenous factors such as estrogens or diet (*36*), then ethylnitrosourea appears to be almost an order of mag-

Table 2. Percentages of GGT⁺ and GGT⁻ hepatocytes with chromosome damage isolated from rats on initiation-promotion (Peraino) (*34*) and initiation-promotion-initiation (IPI) protocols.[a]

Protocol	Chromatid	Isochromatid	Fragments	Chromosomal rearrangements
Peraino				
GGT⁺	4.0 ± 1.0	0.0	0.0	0.0
GGT⁻	3.0 ± 1.0	0.0	0.0	0.0
IPI				
GGT⁺	28.0 ± 5.0	16.0 ± 6.0	7.0 ± 2.0	17.0 ± 2.0
GGT⁻	21.6 ± 2.0	14.0 ± 2.0	16.0 ± 1.0	10.0 ± 5.0

[a]GGT⁺ and GGT⁻ hepatocytes were isolated from livers of animals on the Peraino and IPI protocols (see text for details), and the chromosome spreads were developed by techniques previously described by Sargent et al. (*68*).

nitude more effective than hydroxyurea as a progressor agent. Preliminary studies also indicate that an increased number of malignant hepatic neoplasms is seen in rats 6 to 10 months after the administration of ethylnitrosourea in this protocol.

Karyotypic Changes As Markers of the Stage of Progression in Rat Hepatocarcinogenesis

The karyology of hepatocytes during the process of carcinogenesis in the rat has been studied a number of times during the past three decades. A relatively early study by Grundman (*63*) demonstrated that nuclei of early basophilic focal lesions contained a diploid amount of DNA. These findings were basically confirmed with a similar technology in at least two more recent publications (*64,65*). Seglen and his co-workers (*66*) demonstrated that both hepatocellular nodules and carcinomas exhibited similar, predominantly diploid nuclei in the cells of these lesions. More recently, with techniques developed in our laboratory (*67*), Sargent et al. (*68*) confirmed the earlier microspectrophotometric analyses demonstrating that GGT⁺ cells isolated from the livers of rats in the stage of promotion are almost entirely diploid in nature, as determined by their karyotype. These studies, confirming earlier investigations by an entirely different method, argue strongly that the initiated cells within the liver are probably diploid as well, although the predominance of hepatocytes in the adult rat are tetraploid or of higher ploidy. If the malignant transformation results from recessive mutations involving tumor-suppressor genes (*69*), then it is understandable that only diploid cells would potentially give rise to malignant neoplasms.

Table 3. The number of altered hepatic foci resulting from the application of an initiation-promotion-initiation (IPI) protocol to adult female rats.[a]

Treatment (IPI)	Number of AHF/liver (4 markers)
DEN/PB/ENU	18,500 ± 1,500
DEN/PB/HU	6,600 ± 700
DEN/PB/-	4,900 ± 250

[a]The IPI protocol and the four markers used in its analysis have been described previously (*36,62*). Diethylnitrosamine (DEN) was administered at a dose of 15 mg/kg to 4-day-old Sprague-Dawley rats. At the time of weaning, female animals were placed on 0.05% phenobarbital (PB) for 4 additional months, at which time a single dose of ethylnitrosourea (ENU) at a dose of 100 mg/kg was administered intraperitoneally 24 hr after a 70% partial hepatectomy. Similarly, hydroxyurea (HU) was given at a dose of 100 mg/kg three times at 10-hr intervals beginning 20 hr after a 70% partial hepatectomy. In the last group only a partial hepatectomy was performed, with no additional initiation.

Sargent also reported that hepatocytes derived from AHF resulting from a protocol showing a high degree of toxicity and carcinoma incidence, the Solt-Farber protocol (*70*), exhibited a high degree of aneuploidy, in contrast to AHF from the livers of rats subjected to a relatively mild, nontoxic protocol described by Peraino et al. (*71*). We have extended these investigations to a comparison of karyotypes of GGT⁺ hepatocytes from rats subjected only to initiation and promotion (*36*) with those from rats on the IPI protocol.

When GGT⁺ hepatocytes are isolated from an IPI protocol and compared with those of the initiation-promotion component (Peraino protocol), the results seen in Table 3 may be obtained. In this case, the distinctive karyotypes seen in the two protocols can be noted. Hepatocytes isolated from livers subjected to the IPI protocol exhibit a large proportion of distinctive abnormalities and aneuploidy, whereas those from the initiation-promotion protocol exhibit essentially none (not different from control values). By a study of these two protocols in which the stage of progression can be delineated, one may investigate any specific karyotypic abnormalities that may be seen to result from administration of the progressor agent. As yet, no specific pattern has been noted as to these karyotypic abnormalities. However, other biological changes are noted in AHF in the stage of progression, some of which will now be considered.

Altered Proto-Oncogene Expression during Multistage Hepatocarcinogenesis

Although the quantitation of foci-in-foci or promoter-independent AHF may give some quantitative indications of the stage of progression, it is still clear that there are much greater numbers of either of these types of lesions than of hepatocellular carcinomas, which appear later. In attempts to delineate possible abnormalities in gene expression that could better predict those AHF which are direct precursors of carcinomas, we

have investigated the expression of several proto-oncogenes during the stages of promotion and progression. In an earlier publication (*72*), an increased expression of c-Ha-*ras* and c-*myc* occurred in some, but not all, hepatocellular carcinomas. However, no increased expression of these proto-oncogenes was noted in cells of AHF during the stage of promotion (*72,73*). In preliminary experiments with immunohistochemical techniques, there was essentially no change in the amount of protein products for these genes, as well as for the c-*raf* proto-oncogene product.

Other workers, however, have demonstrated increased expressions of the c-Ha-*raf* and c-*myc* genes in primary hepatomas induced by the continuous feeding of 3′-methyl-4-dimethylaminobenzene (*74,75*). Similarly, AHF, nodules, and malignancies of the liver resulted from protocols in which a necrogenic dose of initiating agent exhibited increased levels of these two proto-oncogene products (*76,77*), as well as that of the c-*src* proto-oncogene (*78*). We have, therefore, searched for increased expression of these proto-oncogenes early during the stage of progression and have occasionally seen such expression, but as yet we have not been able to devise techniques for its quantitation. It is possible, however, that those rare foci-in-foci in which the secondary focus shows an increased expression of one or more proto-oncogenes may be related to an aneuploid karyotype and the ultimate hepatocellular carcinomas.

Conclusions

Although model biological systems cannot completely replicate all possible variations seen in the varieties of systems studied, as well as in the human, experimental findings in model systems can be used as a basis for studies and points of correlation and explanation of epidemiologic and pathologic observations on human cancer. Multistage hepatocarcinogenesis in the rat offers many advantages in relation to actual or potential quantitation of the stages of initiation, promotion, and progression, as well as identification of carcinogenic agents that act primarily at one or another of these stages rather than all three. Critical in the use of this and other model multistage carcinogenesis systems in solid organs is the ability to quantitate the earliest lesions after initial administration of the carcinogen. Studies of the molecular markers that allow identification and quantification of such lesions are critical to the operational experimentation involved. However, the demonstration of the differential expression of specific genes compared with normal hepatocytes probably effects abnormalities in cellular function that are directly or indirectly related to the mechanisms of the neoplastic transformation. Although no ubiquitous marker has been found that characterizes any of the stages in carcinogenesis, it is now reasonable to argue that the increase or lack of expression of specific genes in transformed cells is directly related to their expression of the malignant phenotype. Since studies thus far have been characterized by an extreme variation in marker expression, it is likely that there are multiple phenotypes and genotypes that can lead to or are characteristic of the malignant cell.

The authors express their appreciation to Mary Jo Markham for expert technical typing and revision of the manuscript, as well as Jane Weeks and Jennifer Potter for outstanding histotechnologic expertise. The editorial review and advice of Ilse Riegel is acknowledged and deeply appreciated. Studies described herein were supported in part by grants from the National Cancer Institute (CA-07175, CA-22484, and CA-45700). Y. Dragan is a postdoctoral trainee in chemical carcinogenesis of the National Cancer Institute (CA-09020).

REFERENCES

1. Pitot, H. C., Beer, D., and Hendrich, S. Multistage carcinogenesis: the phenomenon underlying the theories. In: Theories of Carcinogenesis (O. Iversen, Ed.), Hemisphere Press, Washington, DC, 1988, pp. 159–177.
2. McCormick, J. J., and Maher, V. M. Malignant transformation of mammalian cells in culture, including human cells. Environ. Mol. Mutagen. 14: 105–113 (1989).
3. Pitot, H. C. Characterization of the stage of progression in hepatocarcinogenesis in the rat. In: Boundaries between Promotion and Progression (O. Sudilovsky, L. Liotta, and H. C. Pitot, Eds.), Plenum Press, New York, in press.
4. Pitot, H. C., and Sirica, A. E. The stages of initiation and promotion in hepatocarcinogenesis. Biochim. Biophys. Acta 605: 191–215 (1980).
5. Farber, E. Hyperplastic liver nodules. Methods Cancer Res. 7: 345–375 (1973).
6. Goldfarb, S., and Zak, F. G. Role of injury and hyperplasia in the induction of hepatocellular carcinoma. J. Am. Med. Assoc. 178: 729–731 (1961).
7. Gössner, V. W., and Friedrich-Freksa, H. Histochemische Untersuchungen über die Glucose-6-Phosphatase in der Rattenleber während der Kanzerisierung durch Nitrosamine. Naturforschung 19: 862–864 (1964).
8. Friedrich-Freksa, H., Papadopulu, G., and Gössner, W. Histochemische Untersuchungen der Cancerogenese in der Rattenleber nach zeitlich begrenzter Verabfolgung von Diäthylnitrosamin. Z. Krebsforsch. 72: 240–253 (1969).
9. Reuber, M. D. Development of preneoplastic and neoplastic lesions of the liver in male rats given 0.025 percent *N*-2-fluorenyldiacetamide. J. Natl. Cancer Inst. 34: 697–723 (1965).
10. Walker, A. I. T., Thorpe, E., and Stevenson, D. E. The toxicology of dieldrin (HEOD*). I. Long-term oral toxicity studies in mice. Fd. Cosmet. Toxicol. 11: 415–432 (1972).
11. Hori, S. H. Cytochemical studies on tumor cells. VII. Inductivity of glucose-6-phosphate-dehydrogenase in hepatic cells of rats fed azo dye. Gann 57: 85–93 (1966).
12. Kitagawa, T. Histochemical analysis of hyperplastic lesions and hepatomas of the liver of rats fed 2-fluorenylacetamide. Gann 62: 207–216 (1971).
13. Bannasch, P., Hesse, J., and Angerer, H. Hepatocelluläre Glykogenose und die Genese sogenannter hyperplastischer Knoten in der Thioacetamidvergifteten Rattenleber. Virchows Arch. B 17: 29–50 (1974).
14. Bannasch, P. Die Cytologie der Hepatocarcinogenese. Springer-Verlag, Berlin, 1975.
15. Fiala, S., Fiala, A. E., and Dixon, B. γ-Glutamyl transpeptidase in transplantable, chemically induced rat hepatomas and "spontaneous" mouse hepatomas. J. Natl. Cancer Inst. 48: 1393–1401 (1972).
16. Kalengayi, M. M. R., Ronchi, G., and Desmet, V. J. Histochemistry of gamma-glutamyl transpeptidase in rat liver during aflatoxin B_1 induced carcinogenesis. J. Natl. Cancer Inst. 55: 579–588 (1975).
17. Solt, D., and Farber, E. New principle for the analysis of chemical carcinogenesis. Nature 263: 701–703 (1976).
18. Pitot, H. C., Barsness, L., Goldsworthy, T., and Kitagawa, T. Biochemical characterization of stages of hepatocarcinogenesis

after a single dose of diethylnitrosamine. Nature 271: 456–458 (1978).
19. Pugh, T. D., and Goldfarb, S. Quantitative histochemical and autoradiographic studies of hepatocarcinogenesis in rats fed 2-acetylaminofluorene followed by phenobarbital. Cancer Res. 38: 4450–4457 (1978).
20. Satoh, K., Kitahara, A., Soma, Y., Inaba, Y., Hatayama, I., and Sato, K. Purification, induction, and distribution of placental glutathione transferase: a new marker enzyme for preneoplastic cells in the rat chemical hepatocarcinogenesis. Proc. Natl. Acad. Sci. U.S.A. 82: 3964–3968 (1985).
21. Sato, K., Kitahara, A., Satoh, K., Ishikawa, T., Tatematsu, M., and Ito, N. The placental form of glutathione S-transferase as a new marker protein for preneoplasia in rat chemical hepatocarcinogenesis. Gann 75: 199–202 (1984).
22. Pitot, H. C. Altered hepatic foci: their role in murine hepatocarcinogenesis. Annu. Rev. Pharmacol. Toxicol. 30: 465–500 (1990).
23. Peraino, C., Richards, W. L., and Stevens, F. J. Multistage hepatocarcinogenesis. In: Mechanisms of Tumor Promotion. Tumor Promotion in Internal Organs, Vol. 1 (T. J. Slaga, Ed.), CRC Press, Boca Raton, FL, 1982, pp. 1–53.
24. Pretlow, T. P., Crane, R. W., Goehring, P. L., Lapinsky, A. S., and Pretlow, T. G. II. Examination of enzyme-altered foci with gamma-glutamyl transpeptidase, aldehyde dehydrogenase, glucose-6-phosphate dehydrogenase, and other markers in methacrylate-embedded liver. Lab. Invest. 56: 96–100 (1987).
25. Sirica, A. E., and Pitot, H. C. Phenotypic markers of hepatic "preneoplasia" and neoplasia in the rat. In: Cancer Cell Organelles (E. Reid, E. M. W. Cook, and D. J. Moore, Eds.), Horwood, Chichester, England, 1982, pp. 131–143.
26. Squire, R. A., and Levitt, M. H. Report of a workshop on classification of specific hepatocellular lesions in rats. Cancer Res. 35: 3214–3223 (1975).
27. Maronpot, R. R., Montgomery, C. A., Jr., Boorman, G. A., and McConnell, E. E. National Toxicology Program nomenclature for hepatoproliferative lesions of rats. Toxicol. Pathol. 14: 263–273 (1986).
28. Histologic typing of liver tumors of the rat. J. Natl. Cancer Inst. 64: 179–206 (1980).
29. Hayashi, Y. Histologic typing of liver tumors in rats, mice, and hamsters—a workshop report. Exp. Pathol. 28: 140–141 (1985).
30. Bannasch, P. Preneoplastic lesions as end points in carcinogenicity testing. I. Hepatic preneoplasia. Carcinogenesis 7: 689–695 (1986).
31. Ward, J. M. Morphology of foci of altered hepatocytes and naturally occurring hepatocellular tumors in F344 rats. Virchows Arch. A 390: 339–345 (1981).
32. Harada, T., Maronpot, R. R., Morris, R. W., and Boorman, G. A. Morphological and stereological evaluation of spontaneous foci of cellular alteration in Fischer 344 rat livers. Toxicol. Pathol. 17: 579–593 (1989).
33. Harada, T., Maronpot, R. R., Morris, R. W., and Boorman, G. A. Observations on altered hepatocellular foci in National Toxicology Program two-year carcinogenicity studies in rats. Toxicol. Pathol. 17: 690–708 (1989).
34. Peraino, C., Staffeldt, E. F., Carnes, B. A., Ludeman, V. A., Blomquist, J. A,. and Vesselinovitch, S. D. Characterization of histochemically detectable altered hepatocyte foci and their relationship to hepatic tumorigenesis in rats treated once with diethylnitrosamine or benzo(a)pyrene within one day after birth. Cancer Res. 44: 3340–3347 (1984).
35. Ogawa, K., Solt, D. B., and Farber, E. Phenotypic diversity as an early property of putative preneoplastic hepatocyte populations in liver carcinogenesis. Cancer Res. 40: 725–733 (1980).
36. Xu, Y.-h., Campbell, H. A., Sattler, G. L., Hendrich, S., Maronpot, R., Sato, K., and Pitot, H. C. Quantitative stereological analysis of the effects of age and sex on multistage hepatocarcinogenesis in the rat by use of four cytochemical markers. Cancer Res. 50: 472–479 (1990).
37. Roomi, M. W., Ho, R. K., Sarma, D. S. R., and Farber, E. A common biochemical pattern in preneoplastic hepatocyte nodules generated in four different models in the rat. Cancer Res. 45: 564–571 (1985).
38. Buchmann, A., Kuhlmann, W., Schwarz, M., Kunz, W., Wolf, C. R., Moll, E., Friedberg, T., and Oesch, F. Regulation and expression of four cytochrome P-450 isoenzymes, NADPH-cytochrome P-450 reductase, the glutathione transferases B and C and microsomal epoxide hydrolase in preneoplastic and neoplastic lesions in rat liver. Carcinogenesis 6: 513–521 (1985).
39. Neveu, M. J., Hully, J. R., Paul, D. L., and Pitot, H. C. Reversible alteration in the expression of the gap junctional protein connexin 32 during tumor promotion in rat liver and its role during cell proliferation. Cancer Commun. 2: 21–31 (1990).
40. Embleton, M. J., James, H. S., Haynes, A. J., and Butler, P. C. Heterogeneity of hepatocyte antigen expression in rat liver carcinogenesis: concordance between neoplastic nodules and tumours. Br. J. Exp. Pathol. 70: 647–657 (1989).
41. Goldsworthy, T. L., Hanigan, M. H., and Pitot, H. C. Models of hepatocarcinogenesis in the rat—contrasts and comparisons. CRC Crit. Rev. Toxicol. 17: 61–89 (1986).
42. Goldfarb, S. A morphological and histochemical study of carcinogenesis of the liver in rats fed 3′-methyl-4-dimethylaminobenzene. Cancer Res. 33: 1119–1128 (1973).
43. Reuber, M. D. Evolution of hyperplasia, hyperplastic nodules, and carcinomas of the liver induced in rats by N-2-fluorenyldiacetamide. Gann Monogr. Cancer Res. 17: 301–342 (1975).
44. Farber, E. Chemical carcinogenesis: a biological perspective. Am. J. Pathol. 106: 271–296 (1982).
45. Hendrich, S., Glauert, H. P., and Pitot, H. C. The phenotypic stability of altered hepatic foci: effects of withdrawal and subsequent readministration of phenobarbital. Carcinogenesis 7: 2041–2045 (1986).
46. Enomoto, K., and Farber, E. Kinetics of phenotypic maturation of remodeling of hyperplastic nodules during liver carcinogenesis. Cancer Res. 42: 2330–2335 (1982).
47. Tatematsu, M., Takano, T., Hasegawa, R., Imaida, K., Nakanowatari, J., and Ito, N. A sequential quantitative study of the reversibility or irreversibility of liver hyperplastic nodules in rats exposed to hepatocarcinogens. Gann 71: 843–855 (1980).
48. Moore, M. A., Hacker, H.-J., and Bannasch, P. Phenotypic instability in focal and nodular lesions induced in a short term system in the rat liver. Carcinogenesis 4: 595–603 (1983).
49. Edmondson, H. A, Reynolds, T. B., Henderson, B., and Benton, B. Regression of liver cell adenomas associated with oral contraceptives. Ann. Int. Med. 86: 180–182 (1977).
50. Reuber, M. D. Carcinomas of the liver in Osborne-Mendel rats ingesting DDT. Tumori 64: 571–577 (1978).
51. Kociba, R. J., Keyes, D. G., Beyer, J. E., Carreon, R. M., Wade, C. E., Dittenber, D. A., Kalnins, R. P., Frauson, L. E., Park, C. N., Barnard, S. D., Hummel, R. A., and Humiston, C. G. Results of a two-year chronic toxicity and oncogenicity study of 2,3,7,8-tetrachlorodibenzo-*p*-dioxin in rats. Toxicol. Appl. Pharmacol. 46: 279–303 (1978).
52. Schulte-Hermann, R., Timmermann-Trosiener, I., and Schuppler, J. Promotion of spontaneous preneoplastic cells in rat liver as a possible explanation of tumor production by nonmutagenic compounds. Cancer Res. 43: 839–844 (1983).
53. Campbell, H. A., Xu, Y. -D., Hanigan, M. H., and Pitot, H. C. Application of quantitative stereology to the evaluation of phenotypically heterogeneous enzyme-altered foci in the rat liver. J. Natl. Cancer Inst. 76: 751–767 (1986).
54. Pitot, H. C., Goldsworthy, T., Campbell, H. A., and Poland, A. Quantitative evaluation of the promotion by 2,3,7,8-tetrachlorodibenzo-*p*-dioxin of hepatocarcinogenesis from diethylnitrosamine. Cancer Res. 40: 3616–3620 (1980).
55. Dragan, Y. P., Xu, Y. -D., and Pitot, H. C. Tumor promotion as a target for estrogen/anti-estrogen effects in rat hepatocarcinogenesis. Prev. Med., in press.
56. Rao, M. S., Tatematsu, M., Subbarao, V., Ito, N., and Reddy, J. K. Analysis of peroxisome proliferator-induced preneoplastic and neoplastic lesions of rat liver for placental form of glutathione S-transferase and γ-glutamyl-transpeptidase. Cancer Res. 46: 5287–5290 (1986).
57. Sirica, A. E., Jicinsky, J. K., and Heyer, E. K. Effect of chronic phenobarbital administration on the gamma-glutamyl transpeptidase activity of hyperplastic liver lesions induced in rats by the

Solt/Farber initiation: selection process of hepatocarcinogenesis. Carcinogenesis 5: 1737–1740 (1984).
58. Yeldandi, A. V., Subbarao, V., Rajan, A., Reddy, J. K., and Rao, M. S. γ-Glutamyltranspeptidase-negative phenotypic property of preneoplastic and neoplastic liver lesions induced by ciprofibrate does not change following 2-acetylaminofluorene administration. Carcinogenesis 10: 797–799 (1989).
59. Glauert, H. P., Beer, D., Rao, M. S., Schwarz, M., Xu, Y. -D., Goldsworthy, T. L., Coloma, J., and Pitot, H. C. Induction of altered hepatic foci in rats by the administration of hypolipidemic peroxisome proliferators alone or following a single dose of diethylnitrosamine. Cancer Res. 46: 4601–4606 (1986).
60. Scherer, E. Relationship among histochemically distinguishable early lesions in multistep-multistage hepatocarcinogenesis. Arch. Toxicol. (suppl.) 10: 81–94 (1987).
61. Scherer, E., Feringa, A. W., and Emmelot, P. Initiation-promotion-initiation. Induction of neoplastic foci within islands of precancerous liver cells in the rat. In: Models, Mechanisms and Etiology of Tumour Promotion (M. Börzsönyi, K. Lapis, N. E. Day, and H. Yamasaki, Eds.), IARC Scientific Publication No. 56, Lyon, 1984, pp. 57–66.
62. Pitot, H. C., Campbell, H. A., Maronpot, R., Bawa, N., Rizvi, T. A., Xu, Y. -H., Sargent, L., Dragan, Y., and Pyron, M. Critical parameters in the quantitation of the stages of initiation, promotion, and progression in one model of hepatocarcinogenesis in the rat. Toxicol. Pathol. 17: 594–611 (1989).
63. Grundman, E. Quantitative cytochemistry of the carcinogenesis in the rat liver. Extrait de Acta Union Internationale Contre le Cancer 19: 571–575 (1963).
64. Gil, R., Callaghan, R., Boix, J., Pellin, A., and Llombart-Bosch, A. Morphometric and cytophotometric nuclear analysis of altered hepatocyte foci induced by N-nitrosomorpholine (NNM) and aflatoxin B1 (AFB1) in liver of Wistar rats. Virchows Arch. B. Cell. Pathol. 54: 341–349 (1988).
65. Sarafoff, M., Rabes, H. M., and Dörmer, P. Correlations between ploidy and initiation probability determined by DNA cytophotometry in individual altered hepatic foci. Carcinogenesis 7: 1191–1196 (1986).
66. Saeter, G., Schwarze, P. E., Nesland, J. M., Juul, N., Pettersen, E. O., and Seglen, P. O. The polyploidizing growth pattern of normal rat liver is replaced by divisional, diploid growth in hepatocellular nodules and carcinomas. Carcinogenesis 9: 939–945 (1988).
67. Xu, Y. -H., Sattler, G. L., and Pitot, H. C. A method for the comparative study of replicative DNA synthesis in GGT-positive and GGT-negative hepatocytes in primary culture isolated from carcinogen-treated rats. In Vitro Cell. Dev. Biol. 24: 995–1000 (1988).
68. Sargent, L., Xu, Y. -H., Sattler, G. L., Meisner, L., and Pitot, H. C. Ploidy and karyotype of hepatocytes isolated from enzyme-altered foci in two different protocols of multistage hepatocarcinogenesis in the rat. Carcinogenesis 10: 387–391 (1989).
69. Klein, G. Tumour suppressor genes. J. Cell Sci. (suppl.) 10: 171–180 (1988).
70. Solt, D. B., and Farber, E. New principle for the analysis of chemical carcinogenesis. Nature 263: 702–703 (1976).
71. Peraino, C., Staffeldt, E. F., and Ludeman, V. A. Early appearance of histochemically altered hepatocyte foci and liver tumors in female rats treated with carcinogens one day after birth. Carcinogenesis 2: 463–465 (1981).
72. Beer, D. G., Schwarz, M., Sawada, N., and Pitot, H. C. Expression of H-*ras* and c-*myc* protooncogenes in isolated γ-glutamyl transpeptidase-positive hepatocytes and hepatocellular carcinomas induced by diethylnitrosamine. Cancer Res. 46: 2435–2441 (1986).
73. Embleton, M. J., and Butler, P. C. Reactivity of monoclonal antibodies to oncoproteins with normal rat liver, carcinogen-induced tumours, and premalignant liver lesions. Br. J. Cancer 57: 48–53 (1988).
74. Cote, G. J., Lastra, B. A., Cook, J. R., Huang, D.-P., and Chiu, J.-F. Oncogene expression in rat hepatomas and during hepatocarcinogenesis. Cancer Lett. 26: 121–127 (1985).
75. Makino, R., Hayashi, K., Sato, S., and Sugimura, T. Expressions of the c-Ha-*ras* and c-*myc* genes in rat liver tumors. Biochem. Biophys. Res. Commun. 119: 1096–1102 (1984).
76. Galand, P., Jacobovitz, D., and Alexandre, K. Immunohistochemical detection of c-Ha-*ras* oncogene p21 product in pre-neoplastic and neoplastic lesions during hepatocarcinogenesis in rats. Int. J. Cancer 41: 155–161 (1988).
77. Ito, S., Watanabe, T., Abe, K., Yanaihara, N., Tateno, C., Okuno, Y., Yoshitake, A., and Miyamoto, J. Immunohistochemical demonstration of the c-*myc* oncogene product in rat chemical hepatocarcinogenesis. Biomed. Res. 9: 177–180 (1988).
78. Richmond, R. E., Pereira, M. A., Carter, J. H., Carter, H. W., and Long, R. E. Quantitative and qualitative immunohistochemical detection of myc and src oncogene proteins in normal, nodule, and neoplastic rat liver. J. Histochem. Cytochem. 36: 179–184 (1988).