Supplemental Material

Testis and Antler Dysgenesis in Sitka Black-Tailed Deer on Kodiak Island, Alaska: Sequela of Environmental Endocrine Disruption?

D. N. Rao Veeramachaneni[1], Rupert P. Amann[1], and James P. Jacobson[2]

[1]Animal Reproduction and Biotechnology Laboratory, Colorado State University, Ft Collins, Colorado 80523 USA; [2]Arctic Rivers Guide Service, Kodiak, Alaska 99615, USA

Background

Sitka black-tailed deer (SBTD; *Odocoileus hemionus sitkensis*) were introduced into the Kodiak Archipelago (Figure 1) from south-east Alaska in the early 1900s, but they apparently died out. Other releases (Figure 1) were 14 deer from Baranof Island on Long Island in 1924, 2 deer from Prince of Wales Island on Long Island in 1930, and 9 deer from Kupreanof Island in 1934 on the north end of Kodiak Island (Alaska Department of Fish and Game records; L.J. Van Daele, personal communication). In 1967 deer were rare in the southern third of Kodiak Island and apparently not present on the Aliulik Peninsula (AP). Over the next 25 years SBTD migrated the length and breadth of Kodiak Island and some swam across open water to nearby islands. A deer typically might range over 2-5 km^2, but travel >3 km between summer and winter ranges is common (Van Daele and McDonald 2001).

Legal hunting of deer in the Kodiak Archipelago started in 1953, with 53 males harvested, and peaked in 1987 when ~13,800 deer (both antlered and non-antlered) were shot. The hunting season encompasses the breeding season, which peaks in mid November. Generally, the terrain is rough and rises steeply from the coast to >1200 m. Northern areas are Sitka spruce forest interspersed with tundra, whereas the southern two-thirds is open tundra with low bushes (Smith 1979). The deer population is profoundly influenced by periodic severe winter kills (up to 50% die; Van Daele and McDonald 2001). It was estimated that there were 40,000 SBTD on the archipelago in fall 1999, and ~2,800 deer were shot annually in 2000-2002 (Alaska Department of Fish and Game records).

Adult male SBTD might weigh 60-115 kg (130-250 pounds) and have a characteristic antler form, with extent of development depending on age and other factors. Antlers are deciduous paired cranial protuberances of bone. After the first fall, antlers are grown annually, while circulating androgen concentration is low, from permanent epigenetic centers focused in paired antler pedicles plus overlaying skin, which provides the "velvet" (skin over growing antler; rich in blood vessels, sensory and other nerves, sebaceous glands, and short hair). With increased availability of androgens, growth is curtailed and mineralization occurs concurrent with death of the velvet, after which antlers are essentially dead bone with a coronet on the proximal end. With declining androgen, the antlers are shed leaving only the cranial pedicles on the head and shed antlers with proximal terminal seals and coronets. See Bubenik (1990a) and Li and Suttie (2001).The testes usually descend into the pendulous scrotum >2 mo before birth in *Odocoileus sp* (Short 1970), and remain there throughout life. Seasonal cessation of spermatogenesis starts in December (incomplete in an occasional male; West and Nordan 1976) and recrudescence starts in mid summer (Lambiase et al. 1972; Markwald 1968). Although post-pubertal in their second fall, young bucks usually are prevented from mating by dominant older bucks. Females normally lack antlers, and possibly 60% of them first become pregnant in their 2nd fall (Johnson 1987; Wallmo 1981).

At least as early as 1967, a non-typical antlered SBTD was shot in north-east Kodiak Island, with body conformation of a doe and neither testis evident in the scrotal region (N Sutliff, personal communication). JPJ started systematic recording of data for SBTD in 1999, and also collection of blood, fat, teeth, etc. Early evaluations showed that bilateral cryptorchid (BCO) males had lower serum concentrations of testosterone and higher concentrations of luteinizing hormone than non-cryptorchid (NCO) males (Bubenik et al. 2001). Testes of NCO males are not necessarily free of abnormalities, so the term "normal" would be inappropriate. The same report illustrated normal/abnormal antlers and skulls. Information from histological evaluations of testicular tissue from 4 NCO and 3 unilateral cryptorchid (UCO) or BCO males (Bubenik et al. 2001, Bubenik and Jacobson 2002) were hampered by formalin-fixation, but published photomicrographs of abdominal testes are suggestive of abnormalities described herein.

Detailed Methods

Bouin's-fixed tissues were embedded in paraffin and adjacent 5-µm thick sections were stained with hematoxylin and eosin (H&E) or periodic acid-Schiff reaction and hematoxylin (PAS). Glutaraldehyde-fixed tissues were post-fixed in osmium tetroxide, embedded in Poly/Bed 812, and prepared as 1-µm semi-thin and ~70-nm thin sections. Semi-thin sections were stained with toluidine blue or a differential stain (methylene blue and Safranin-O; Laczko and Levai 1975) and evaluated using a Nikon Microphot-FXA light microscope interfaced with a computerized digital imaging system (ImagePro, version 5). Thin sections were stained with uranyl acetate and lead citrate and examined using a JOEL1200EX transmission electron microscope.

Evaluation of the seminiferous epithelium was based on criteria facilitated by recognizing that cross-sections through a tubule can be assigned to 1 of 8 "stages" based on the germ cells therein (Markwald 1968). Recognizing that a group of cross-sections in a locus may actually represent the same convoluted seminiferous tubule, 50-100 (100 if available) randomly selected, essentially round (major diameter <1.5X minor diameter) cross-sections, spanning the entire area of a testicular section, were classified for normalcy via criteria used with bull (Veeramachaneni et al. 1986) testes. Each tubule cross-section was classified as 1 of 8 grades denoting progressive loss of germ cells and degenerative changes in seminiferous epithelium. They were: grade 0 — a normal seminiferous epithelium; grade 1 — pyknosis and desquamation of spermatids or focal vacuolation; grade 2 — changes intermediary to grades 1 and 3; grade 3 — presence of mostly spermatogonia and Sertoli cells (degeneration of post-meiotic cells); grade 4 — Sertoli cells only; grade 5 — no seminiferous epithelium (leaving only basement membrane); grade 6 — tubules with sperm stasis, granuloma, or mineralization; and grade 7 — a completely fibrotic tubule. As detailed in Veeramachaneni et al. (1986), a weighting scheme (0 for grade 0; 0.25, 0.5, and 0.75 for grades 1, 2, and 3; and 1.0 for grades 4-7) was applied to calculate the relative degree of germinal epithelial loss (DGEL) for that section.

Absence of a lesion or abnormal cells in tissue examined is not evidence that a testis was entirely normal (a typical 5-µm section represents ~0.006% of a 24 g testis; Amann, unpublished), although detection of a lesion or abnormal cells is unequivocal evidence that testis includes abnormal tissue (at least focal but perhaps diffuse throughout the organ).

Antlerogenesis

Biology of postnatal antlerogenesis has been studied extensively, but little is known of events early in fetal development. In red deer, sexual dimorphism of the primordial antler pedicle is evident at ~26% of

gestation followed by rapid growth at 32-44% of gestation (Li and Suttie 2001; Lincoln 1973). In males, a few days after initiation of testosterone production by fetal testes, differentiation of the antlers is evident; presumably the antler anlage is programmed for normal development. Mechanisms regulating repression/cessation of differential growth, concomitant with retention of epigenetic and patterning capabilities at birth, are unknown.

Postnatal antlerogenesis, and roles of hormones and the nervous system, have been reviewed (Bubenik 1990b; Goss 1983, 1990; Li and Suttie 2001). At birth, neither antler pedicles nor antlers are evident externally. However, as the testes start to produce testosterone 3-4 mo postnatally (>0.2 ng/mL serum; Suttie et al. 1984) antler pedicles originate from the antler periosteum consequent to testosterone-mediated activation by growth factors. The developing bone induces changes in the surrounding skin, and collectively they form a permanent protuberance. The next spring (~1 yr of age), while testosterone is low, the protruding antler pedicle develops a "shiny skin" and the deciduous antler develops rapidly (Goss 1983). The first antler typically is a single spike, covered with velvet until availability of testosterone rises in early fall (~1.3 yr of age) when the antler undergoes mineralization and the velvet dies and is shed. As the testes regress in the winter, blood concentration of testosterone declines and the antler is shed. Skin regrows over the exposed bone of the pedicle.

In subsequent years antler growth is reinitiated, while testosterone is negligible in blood, with increasingly complex branching and bilateral symmetry in a manner characteristic of the species. The fibrous layer of the perichondrium contains estrogen receptors, which might modulate function of nearby cells. The epidermis and chondroblasts contain IGF-1 receptors, but not those for growth hormone (Elliott et al. 1992). It is likely that both androgen (dihydrotestosterone?) and estrogen, as well as IGFs, are involved in control of mineralization of antlers and ultimately demineralization of the joint between an antler and pedicle (Bubenik 1990a).

Shedding of velvet from hardened bone apparently occurs when blood concentration of testosterone rises above ~1.5 ng/mL (estimated from Bubenik 1990b; McMillin et al. 1974; Suttie et al. 1984), although in the peak of the breeding season testosterone concentration might be >8 ng/mL in many deer (see NCO-NA deer in Figure 5). It is uncertain if this requirement of ~1.5 ng/mL was met in BCO SBTD which retained velvet on their antlers longer than typical, because 16 of 17 values were ≤1.0 ng/mL (Figure 5); most in first half of November. In typical deer, reduction of concentration of testosterone to <1 ng/mL serum, later in the winter, apparently induces casting of the antlers (West and Nordan 1976). Among SBTD observed when antlers should be absent, JPJ never has seen a BCO with retained antlers.

Inbreeding as a Cause of Cryptorchidism

In other species, extreme inbreeding typically results in hypogonadism and impaired spermatogenesis. However, scrotal testes of STBD on the AP had an average estimated weight similar to that for other sites (26 vs 24 g; P>0.55, N = 8, 29) or values for similarly sized Columbia black-tailed deer (*Odocoileus sp*) in the breeding season (25 g; West and Nordan 1976). Furthermore, spermatogenesis in scrotal testes (Figure 6A) was characteristic of a normal deer testis (Markwald 1968), rather than a hypogonadal scrotal testis (McEntee 1990).

Even if heritability and penetration of genetic cryptorchidism in SBTD were as for Boxer dogs (0.23 and <23%; Nielen et al. 2001), the life and generation interval of SBTD are very different from dogs. Death of fawns can approach 40% (Johnson 1987). Females rarely mate before 1.5 yr of age, and male deer ≤4.5 yr of age rarely are allowed by dominant males to mate with a female. Finally, periodically there is a severe

winter causing death of unusually high numbers of deer of all ages, but animals with certain genetic attributes might have a better chance of survival (Keller and Waller 2002); e.g., greater body fat characteristic of BCO deer.

Cryptorchidism in Deer Typically is Not Accompanied by Abnormal Antlers

Available evidence suggests that cryptorchidism in deer typically is not accompanied by abnormal antlers. In 3 BCO or UCO reindeer (*Ragnifer tarandus*) described by Leader-Williams (1979), antlers were small but otherwise normal. Also, cryptorchid roe deer (*Capreolus capreolus*) described by Hofmann (1968) apparently had normal antlers. Finally, Marburger et al. (1967) described 3 white-tailed deer with normal antlers, no scrotum with testes positioned under the perineal skin, and a penis emerging 4-10 cm below the anus; presumably examples of hypospadias. The exception to this generality is the cryptorchid deer described by Bubenik et al. (2001), but they were shot in the Kodiak Archipelago and are included in our data.

Unique scrotal maldevelopment accompanied by malposition of the testes in deer, apparently with normal antlers, was reported by Hoy et al. (2002). They examined 253 car-accident-killed white tailed deer, in western Montana. The scrotum was normal and contained 2 testes for 33% of the deer. In 32% of all deer the scrotal septum was perpendicular to the animal's midline; both testes were scrotal and in 1% of the deer 2 separate hemiscrota were present, each with testis. In 15% of these deer there was only a hemiscrotum (left side) with testis and in 19% the scrotum was short and contained no testis. Testes not found in the scrotum often were detected under the skin, rather than in the inguinal canal. Information on antlers was not provided, so presumably they were not remarkable (when present). Apparently, most of these deer had impairment of transinguinal testicular descent and scrotal development. Many of these abnormal deer also evidenced prognathism (underbite; JA Hoy, personal communication). Because such animals were not detected in their rehabilitation center prior to 1995, the authors speculated that a pesticide might be the causative factor. If that speculation is correct, the agent likely acted as an anti-androgen, because fusion of genital folds to form a scrotum, and gubernacular function, require androgen action. In any case, abnormal deer examined by Hoy et al. (2002) had different defects than SBTD in the current study.

Topography of AP and Potential Sources of Contamination

In contrast to major islands in the Kodiak Archipelago, the AP (~14x50 km) is low lying, especially the southern half (generally <120 m), and adjacent waters are shallow. Although wind is common, the peninsula frequently is covered by fog. Winter snow pack typically is <0.5 m. Further north on Kodiak Island, and other islands, the coast is rugged with few areas of facile access to a beach. The Alaska Costal Current (flowing southwest between the mainland and the archipelago) and the Alaskan Stream (flowing southwest on the east side of the archipelago) slow in velocity, and hence carrying capacity, as they converge on the AP and shallow water immediately west and south (L Buck, personal communication). Reduced carrying capacity favors deposition of kelp and materials on the AP. Kelp is much thicker here than elsewhere (JPJ personal observations). SBTD frequent beach regions of the AP because of facile browsing. Especially in the winter they frequently browse on kelp, washed up twice daily.

Historically, the Kodiak Archipelago has received deposits of bilge wastes and oil discharged by large vessels. The great Alaska earthquake of 1964 resulted in extensive spillage of oil products from wells on Cook Inlet and storage facilities near Anchorage, which impacted the archipelago. However, most of the Kodiak Archipelago purportedly received little or no conspicuous oil from the Exxon Valdez disaster

(Lewis 1991). Commercial canneries and government facilities have been scattered throughout the archipelago, but no contamination site is acknowledged.

References *(includes only those not in published article)*

Bubenik AB. 1990a . Epigenetical, morphological, physiological, and behavioral aspects of evolution of horns, pronghorns, and antlers. In: Horns, Pronghorns, and Antlers (GA Bubenik , AB Bubenik, eds). New York: Springer-Verlag, 3-113.

Elliott JL, Oldham JM, Ambler GR, Bass JJ, Spencer GSG, Hodgkinson DC, et al. 1992. Presence of insulin-like growth factor-I receptors and absence of growth hormone receptors in the antler tip. Endocrinology 130:2513-2520.

Johnson LL. 1987. Reproductive Potential of Sitka Black-Tailed Deer in Southeast Alaska. Final Report Projects W-22-4 and W-22-5. Juneau, AK: Alaska Department of Fish and Game.

Laczko J, Levai G. 1975. A simple differential staining method for semi-thin sections of ossifying cartilage and bone tissues embedded in eposy resin. Mikroskopie 31:S1-4.

Lambiase JTJr, Amann RP, Lindzey JS. 1972. Aspects of reproductive physiology of male white-tailed deer. J Wildlife Mgt 36: 868-875

Short C. 1970. Morphological development and aging of mule and white-tailed deer fetuses. J Wildlife Mgt 34:383-388.

Wallmo OC. 1981. Mule and Black-tailed deer of North America. Lincoln: University of Nebraska Press.

Supplemental Figure 1. Location of Kodiak Archipelago and sites from which SBTD were relocated in 1924, 1932, and 1934 to Long and Kodiak Islands, near town of Kodiak.

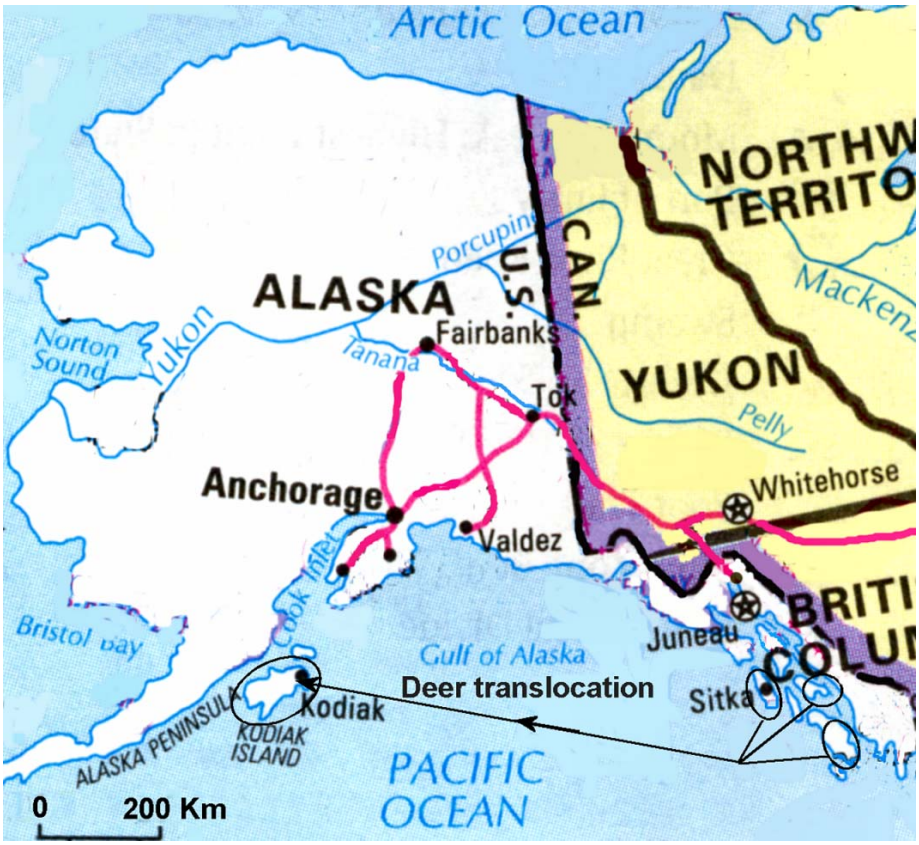

Supplemental Figure 2. Locations of 36 sites where SBTD were shot and evaluated in 1999-2004. Sites 6-13 are on the Aliulik Peninsula. Sites 40-49 were added in 2004. Only sites 1 and 26 were accessed by road.

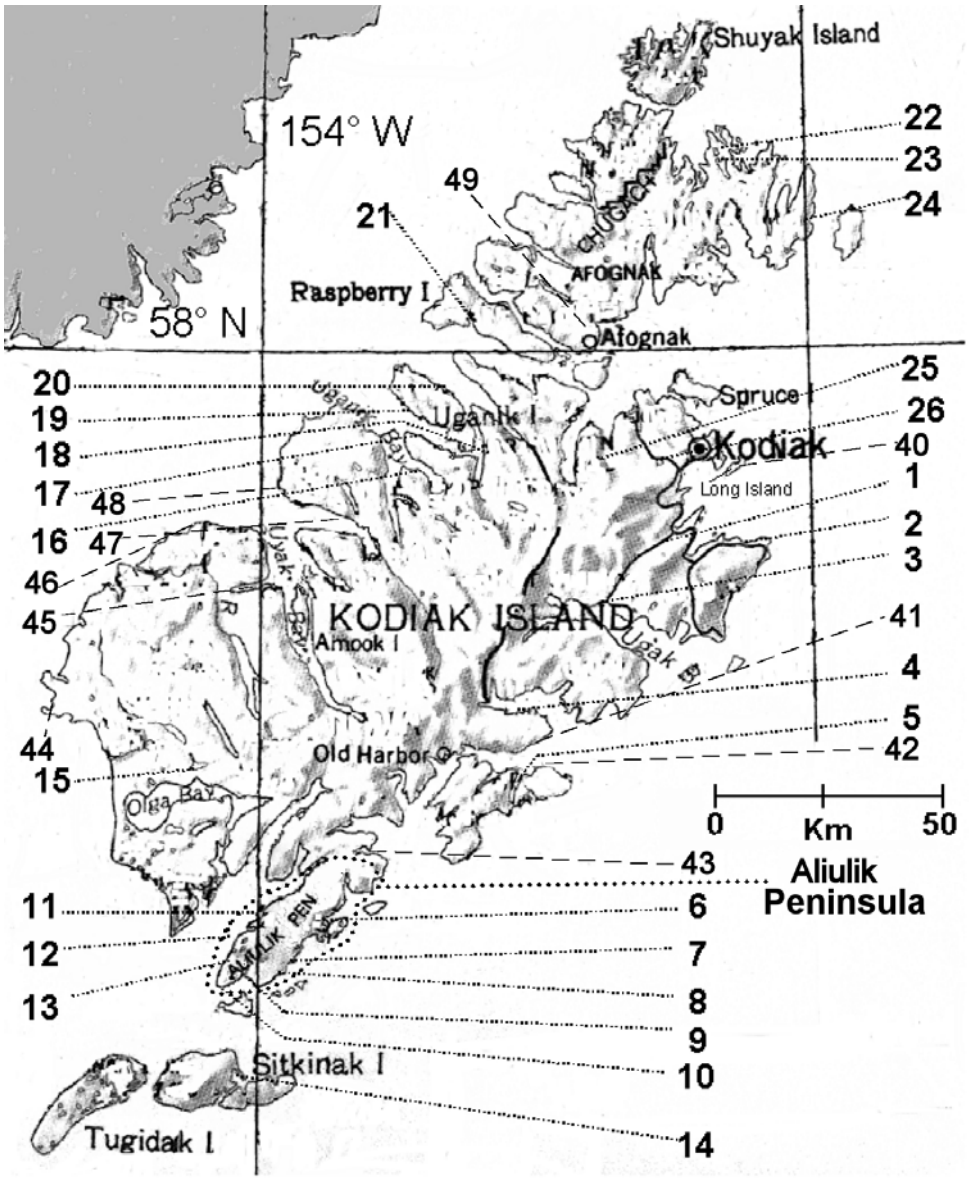

Supplemental Table 1. Testicular position in antlered SBTD as a function of site within the Kodiak Archipelago, as designated in Supplemental Figure 2.

Site #	Non-cryptorchid	Unilateral cryptorchid	Bilateral cryptorchid	Not recorded	% cryptorchid
6	2	1	5	0	75
7	8	5	12	0	68
8	2	0	15	0	88
9	2	0	3	0	60
10	6	0	3	0	33
11	3	1	13	0	82
12	3	0	8	0	73
13	0	0	2	0	100
14	13	1	0	0	7
5+42	1	0	1	0	50
16	4	0	0	0	0
17	7	0	0	0	0
18	5	1	0	4	17
19	5	0	3	7	38
20	3	0	0	0	0
21	2	1	0	1	33
24	2	0	0	0	0
40	1	0	0	0	0
41	1	0	0	0	0
43	2	0	0	0	0
44	1	0	0	0	0
45	2	0	0	0	0
46	1	0	0	0	0
48	4	0	0	0	0
49	3	0	1	0	25
Total/Ave	83	10	66	12	48

Only females were shot at sites 1-5, 15, 21,22, 25, 26, and 47.
Sites 6-13 are on Aliulik Peninsula.

Supplemental Figure 3. Pelvic area in BCO deer 2004-23. Abdominal testes are found among the intestines, often embedded in fat, 50-75% of the distance between the spine caudal of kidney and the lower abdominal wall in inguinal ring area, but never within an inguinal canal. The epididymis is evident. In many cases, there was morefat around each testis than in this example. The testis and epididymis are surrounded by the visceral layer of the vaginal tunica, but not the parietal layer of the vaginal tunic. Apparently, during fetal development the gubernaculum expanded into the opening of the inguinal canal, as the testis was displaced from the area of the kidney, but never expanded sufficiently to result in displacement of the testis into the inguinal canal (see Wensing, 1980). No scrotum was evident in any BCO SBTD, visually or to the touch.

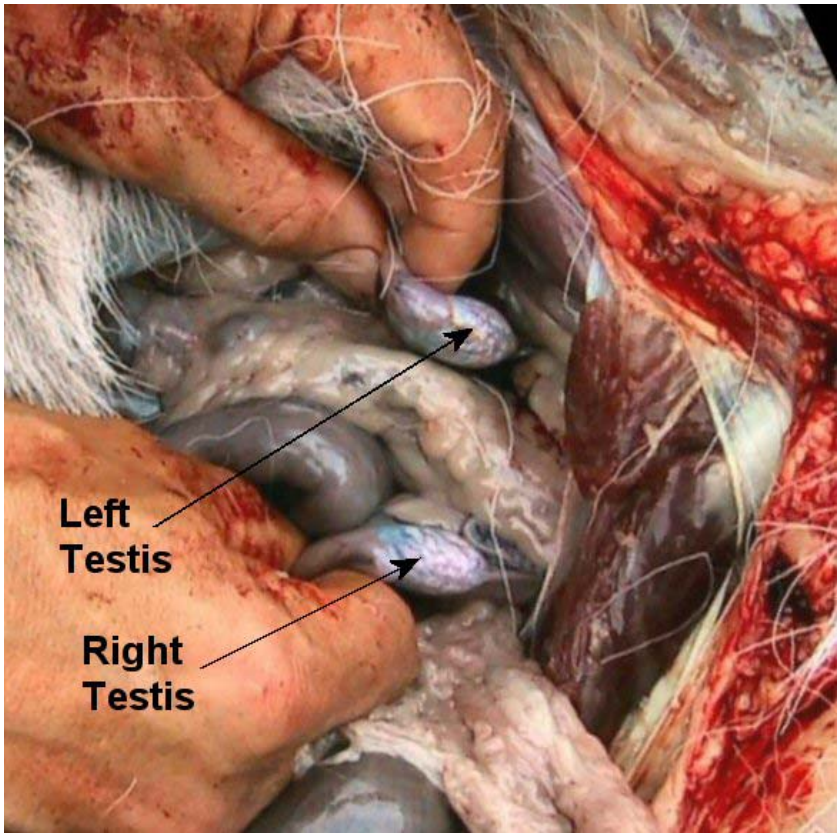

Supplemental Figure 4. Views of antlers of SBTD. **A:** Normal skull with coronet (Cor) and concave antler pedicle (Ped) designated. **B:** Pair of normal antlers each with a convex seal designated. **C:** Skull with atypical and extremely abnormal, convex antler pedicles (Ped) from a BCO deer. **D:** Normal antler partially shown in A. **E:** Pair of antlers each with a thickened base and concave seal (compare with B). **F:** Pair of antlers each with a thickened base, including extra points, and an extremely concave seal; associated with skull in C. **G:** Normal antlers of an NCO deer. **H:** Abnormal antlers, typifying those classified as "polished with sharp tips" often found on BCO deer (compare with G). Also compare tips in B, D, and G (normal) with those in E, F, and H (polished with sharp tips). I through M are abnormal antlers of BCO deer. **I:** Extremely bizarre antlers of deer shot in 1967 by N Sutliff. **J:** Deer 03-06 with spike antlers, despite age and size, still in velvet and arising from a thick base. **K:** Deer 03-03 with bizarre antlers bearing extra "points" or " nubs" still covered with velvet. **L:** Deer 03-13 with bizarre antlers and retaining some velvet. **M:** Deer 03-11 with strongly bizarre antlers still covered with velvet. Deer in J to M were shot between 7 and 16 November 2003 near sites 7 or 8. The Sutliff deer was shot in 1967 near site 3.

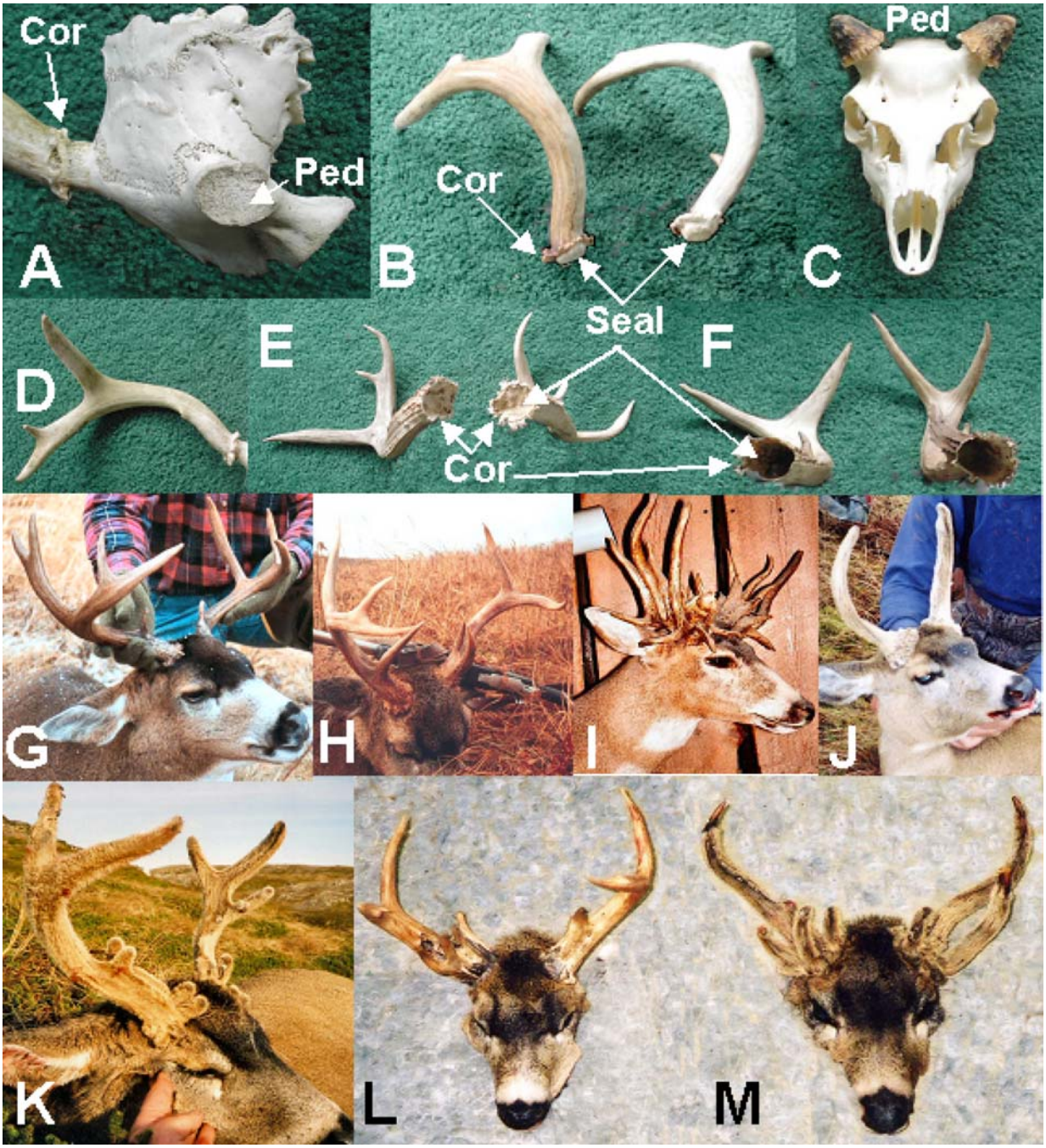

Supplemental Figure 5. Scrotal testis. Photomicrographs of fields in two loci of the same testis from NCO deer 03-10. **A:** Normal progression of spermatogenesis is evident from appearance of germ cells in several stages of the cycle of the seminiferous epithelium. **B:** Loss of germinal cells at different degrees of severity is evident, indicating degenerative changes in the seminiferous epithelium. The number in each tubule represents the grade of pathological change as described in the Materials and Methods. Note proteinaceous secretion (asterisks) sometimes in Grade 4 Sertoli cell-only tubules; whether these secretions ultimately form a concretion is not known. Comparison of the two panels demonstrates that the absence of a lesion in 1 locus is not evidence that an entire testis is normal. Scale bars = 100 µm.

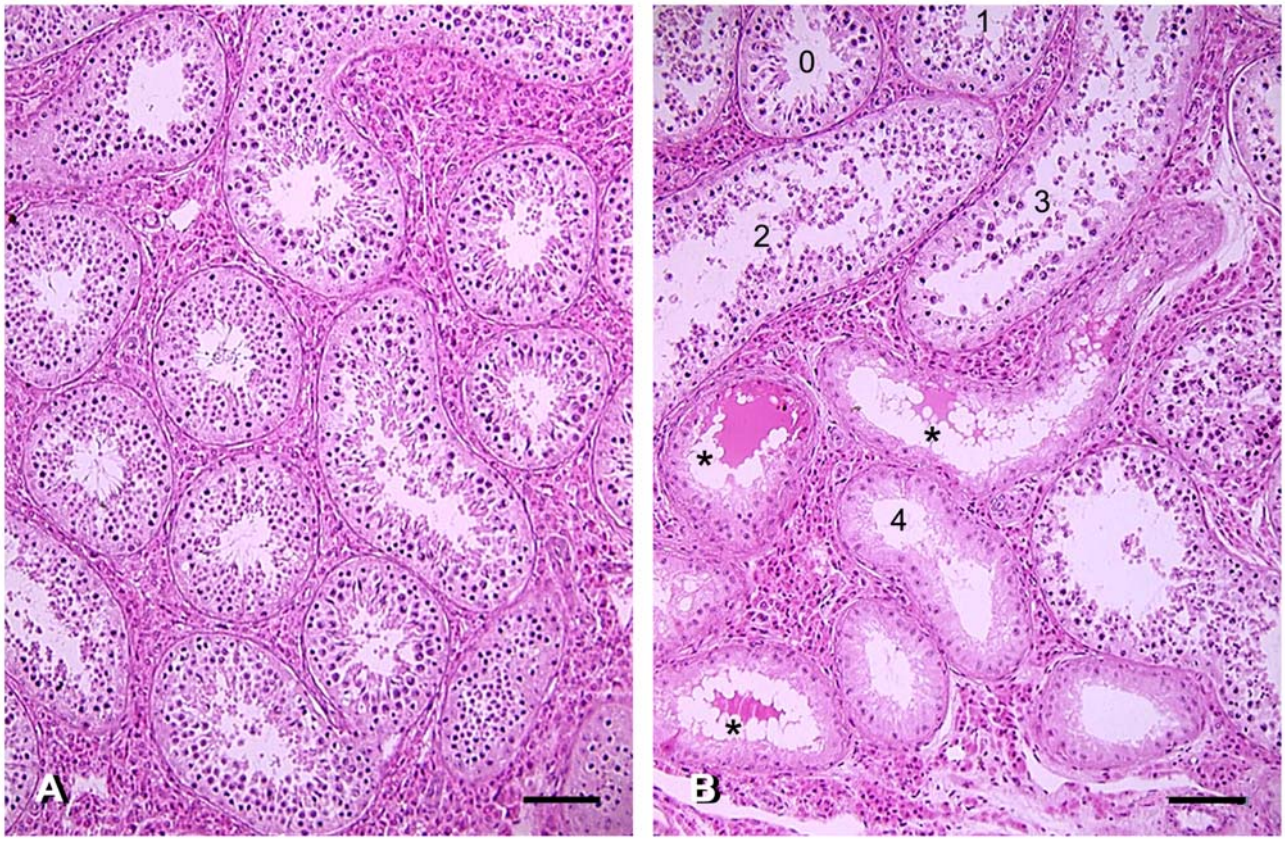

Supplemental Figure 6. Abdominal testes. **A:** Sertoli cell-only tubules (Grade 4) in the testis of BCO deer 03-7. This testis had a DGEL of 100. Note presence of concretions or microliths in several cross sections. **B:** Fibrosis of seminiferous tubules in BCO deer 03-9 enclosing Sertoli cell concretions. Few tubules containing only Sertoli cells and a concretion are seen in the upper right. This testis had a DGEL of 100. **C:** Atypical germ cells (arrows) amidst hyperplastic Sertoli cells in BCO deer 03-13. Note rosettes of Sertoli cells encasing proteinaceous secretions, one forming a concretion. **D:** A seminiferous tubule completely replaced by concretion in the testis of BCO deer 03-11. Note the concretion is surrounded by hyperplastic peritubular cells and by foamy, hypertrophic Leydig cells. Compare the non-neoplastic Sertoli cell-only tubule in the lower left with the neoplastic tubule in Panel C. PAS and hematoxylin staining. Panels C and D: differential interference contrast microscopy. Scale bars A and B = 100 µm; C and D = 25 µm.

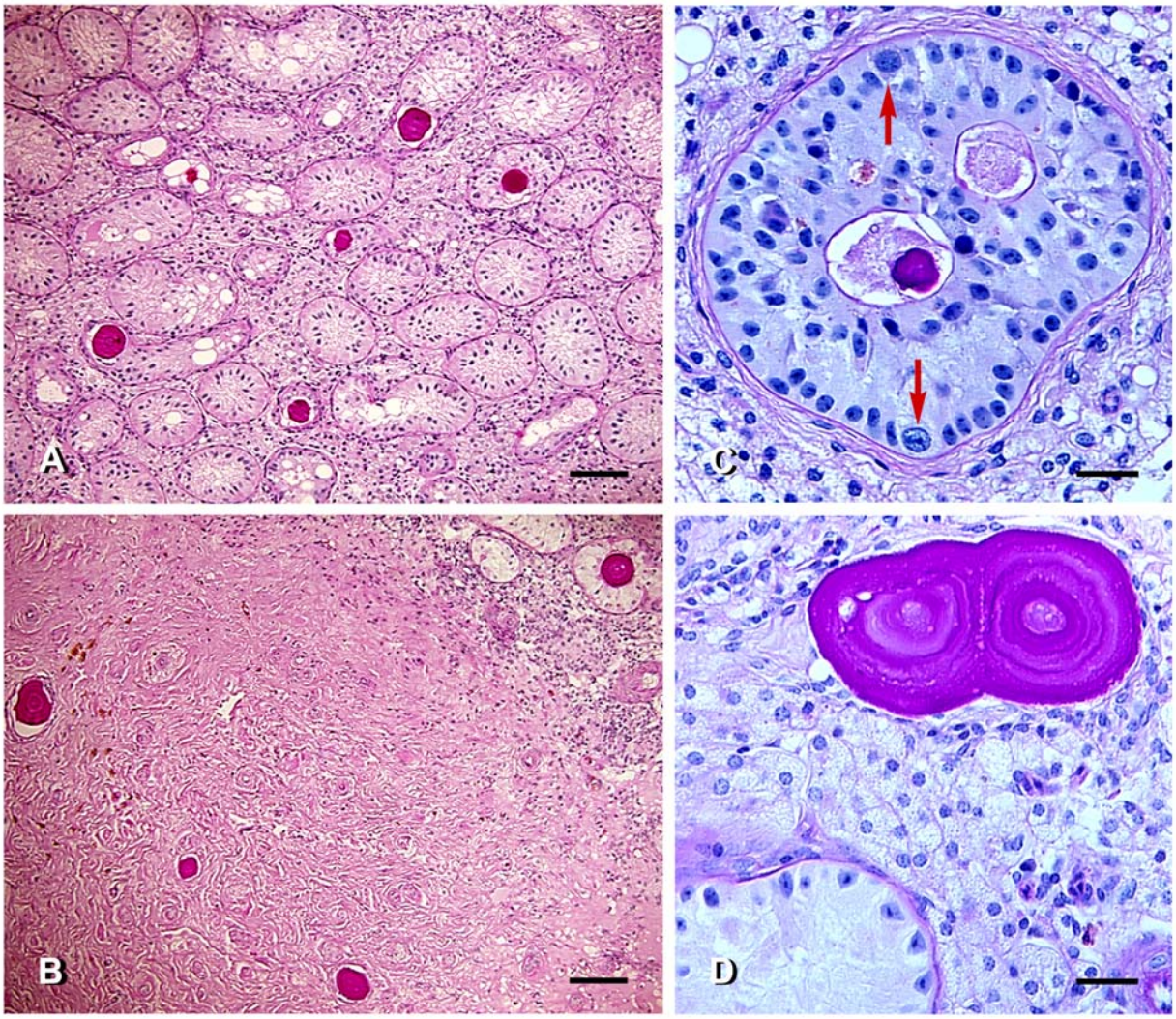
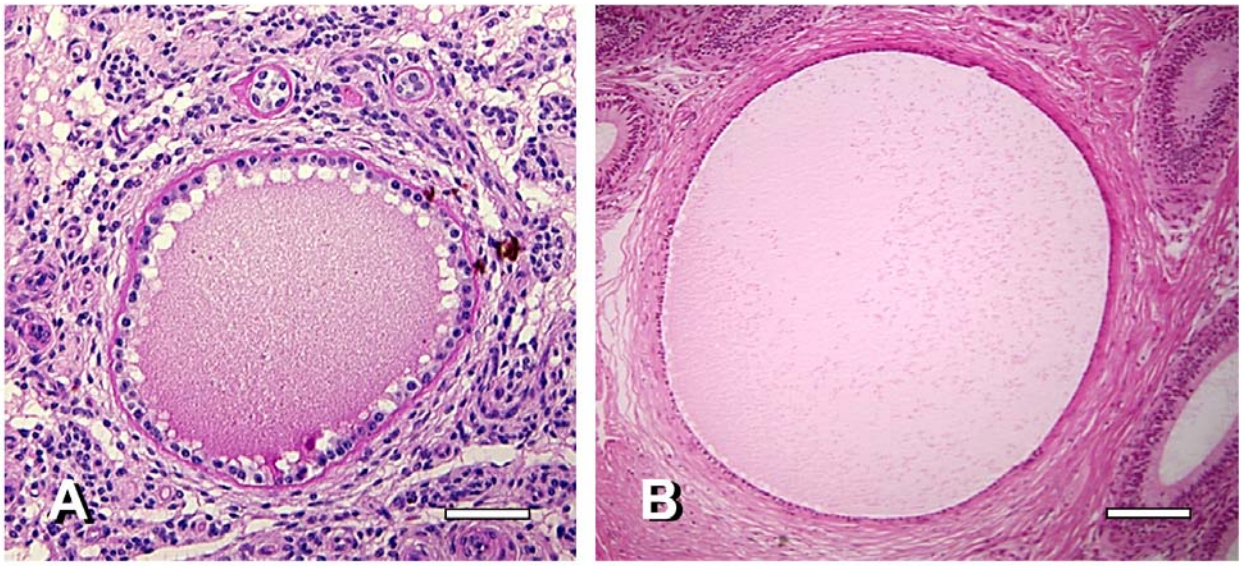
Supplemental Figure 7. Cysts within the rete testis or epididymal duct. **A:** Cyst of rete tubule in the testis of BCO deer 03-6. PAS and hematoxylin staining. **B:** Cyst within the caput epididymidis of BCO deer 03-11. H&E staining. Scale bars: A = 50 µm; B = 100 µm.